Case report: An unexpected outcome of in situ fusion of the calcaneo-cuboid joint

Van Kerckhoven J (1), Van Beek N (1), Verfaillie S (1)

1AZ Herentals, Nederrij 133, 2200 Herentals, Belgium

Background: Surgical options in end-stage osteoarthritis of the mid-foot are limited and often consist of arthrodesis of the painful joint. Unlike in older patients, we experience that arthrodesis of midtarsal joints is less tolerated in a younger patient population.

Case presentation: A 23-year-old women was treated with in-situ fusion of the calcaneo-cuboid joint because of painful posttraumatic end-stage arthritis. 2 years postoperatively, pain was unchanged, she was unable to fully bear weight and an increased heel valgus and forefoot abduction was noticed. Two consecutive SPECT-CT´s, 14 and 22 months after surgery, showed a healed arthrodesis with persistent activity. No other explanation was found than increased bone stress through the arthrodesis due to shortening of the lateral column after in-situ arthrodesis of the calcaneo-cuboid joint. Revision arthrodesis with lengthening and restauration of foot-statistics was performed and the complaints gradually disappeared.

Figure 1. Sagittal view on SPECT-CT taken in January 2017, showing a non-union of the avulsion fracture and arthritis of the calcaneo-cuboid joint. This is 2 years after trauma.

Figure 2. Sagittal view of the calcaneo-cuboid joint on SPECT-CT taken 22 months after arthrodesis and 10 months after hardware removal shows remaining activity within the arthrodesis.

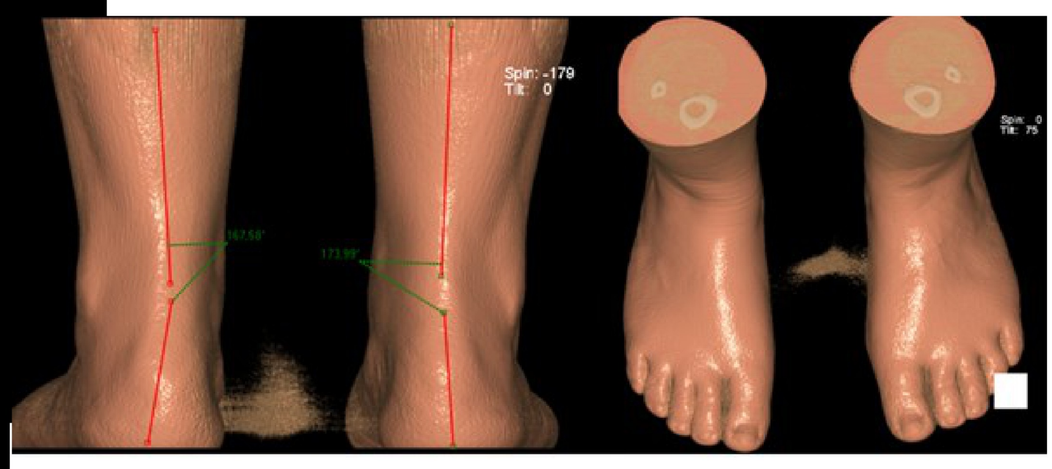

Figure 3. At the left: Posterior view on 3D-reconstruction of the feet shows increased heel valgus in the left heel (12 degrees left vs. 6 degrees right). At the right: View

Figure 4. Weight-bearing CT with transverse view of both feet to the left and axial view at a 60 degrees angle of both heels to the right. Measuring the distance between the styloid process of the 5th metatarsal and the most posterior part of the calcaneus reveals shortening between the lateral column in the left foot compared to the right foot. Comparing heel valgus left and right shows slightly increased valgus on the left side.

Discussion: The aim of this case report is to highlight the delicacy of foot statistics, especially in younger patients. As we could only detect subtle changes on the weight bearing CT-scan, we think that the fused CC-joint didn´t allow the foot to adopt a more pronounced planovalgus position as would be expected after shortening of the lateral column.Nonetheless, the force transmission through the lateral column was changed. The increased bone stress in the arthrodesis was visualised with 2 consecutive SPECT-CT scans 14 and 22 months after initial surgery. To the best of our knowledge, and after exclusion of other reasons for the remaining activity within the arthrodesis such as infection, hardware failure etc., the only explanation for the remaining symptoms was bone stress due to a slight increase in heel valgus. With a corrective lengthening osteotomy, a well-known treatment for flatfoot correction, we aimed to restore the kinematics through the lateral column in order to decrease the bone stress.

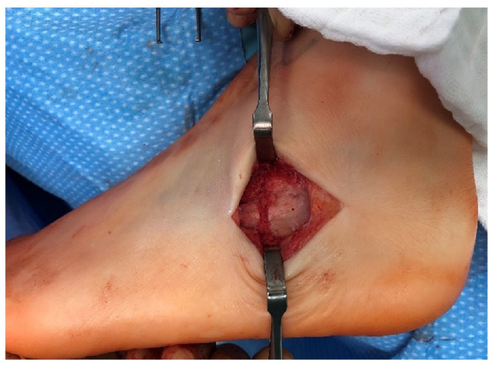

Figure 5. Peroperative photo of the lengthening arthrodesis of the calcaneo-cuboid joint through the sinus tarsi approach.

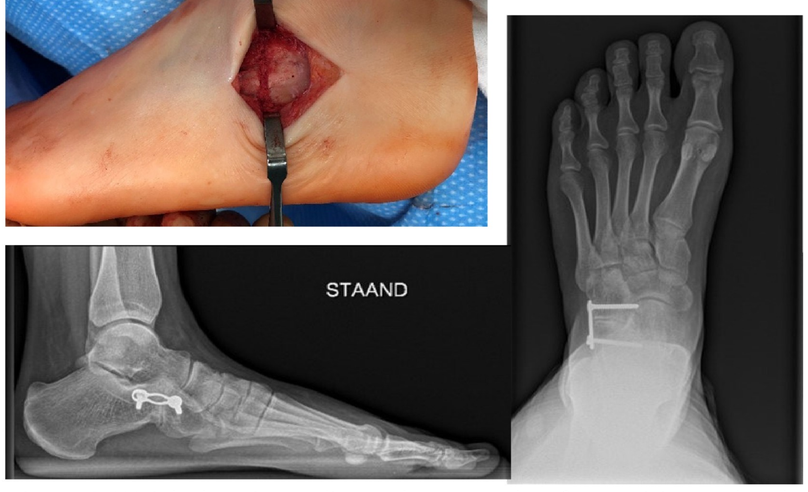

Figure 6. Weight bearing radiographs 5 months after revision arthrodesis with lengthening of the lateral column. Medio-lateral view at the left, cranio-caudal view at the right.

Conclusion: The biomechanical model of the foot is complex and poorly understood. Surgical options in end-stage osteoarthritis are limited and often consist of arthrodesis of the painful joint. Unlike in older patients, we experience that arthrodesis of midtarsal joints is less tolerated in a younger patient population. Our hypothesis is that shock- and force transmission during stance and gait is a very delicate mechanism that depends on small but essential movements through the midfoot. Especially in younger patients, alterations within the foot kinetics and kinematics can significantly change the load distribution within the foot and may cause bone stress and pain. We therefore recommend to respect foot statistics to a maximum, especially within younger patients, and to reconstruct foot physiognomy as good as possible.

ortho HERENTALS