



## Osteotomy around the painful degenerative varus knee

### ESSKA formal consensus project

#### Introduction

The aim of this ESSKA Consensus is to provide a fusion of the scientific evidence and expert opinion (where it is appropriate) regarding the **indications, planning, surgical strategy, rehabilitation and complications** for the most widespread application of osteotomy: **management of the painful, degenerative varus knee.**

Modern osteotomy has evolved dramatically from the accepted dogma of 50 years ago. In the 1960s through to the 1990s a valgising osteotomy for the painful degenerative varus knee conventionally involved a lateral closing wedge high tibial osteotomy (LCWHTO) for which bone staples and protection in plaster of Paris were routine methods of fixation and support. These established techniques have now been largely superseded by techniques of medial opening wedge high tibial osteotomy (MOWHTO), lateral closing wedge distal femoral osteotomy (LCWDFO) or a combination of the two with double level osteotomy (DLO). These techniques have been accompanied by the invention of angle stable locking plate fixators which have permitted earlier range of movement exercise and weight-bearing to enhance rehabilitation of patients. Development of new radiology techniques has led to the planning of osteotomies via PACS annotation or by digital software planning platforms. Computer navigation and patient specific instrumentation technologies have introduced options for improving accuracy and precision. Indications have broadened as experience has been gained and greater awareness of complications has led to fine tuning of technical procedures and modification of medical treatments for prevention of adverse events.

Whilst convention has changed, this consensus does not intend to suggest that a lateral closing wedge high tibial osteotomy may not be the preferred option in specific situations. The advent of modern fixation methods reduces some of the inherent fallibility of previous routine practice which may therefore be a thoroughly appropriate strategy in the correct setting. Similarly, the convention adopted in this consensus for distal femoral osteotomy will be the lateral closing wedge procedure as this is the logical procedure for this indication. This consensus acknowledges that each patient has different characteristics, deformity, severity of arthritis severity and indication for osteotomy surgery. Therefore, an individualized approach is promoted which incorporates the degree of deformity according to Paley and radiologic arthritis classification grading OA. This consensus does not purport to provide a specific prescription with precise advice for each patient but offers general



advice. It is a work of best practice guidance and not a list of strict guidelines. The intention is to describe the current perceived best 'every day' mainstream practice in osteotomy for the painful degenerate varus knee. The terminology we have chosen around the most common procedure – **high tibial osteotomy** reflects popular convention. Whilst the word 'high' is not necessarily as precise an anatomical term as the word 'proximal', we have acknowledged that the abbreviation '**HTO**' has usually been preferred in the orthopaedic literature to another accepted term of '**PTO**'. This was also reflected in our consensus process with frequent reference to literature and discussions where this choice of terminology was accepted .

Whilst substantial elements of current osteotomy practice are built on solid foundations with a strong scientific evidence base there are ever greater choices available to the inexperienced surgeon and accompanying areas where robust scientific evidence is absent. So, in addition to scrutiny of the scientific evidence this consensus also draws upon the knowledge of experts in the field with an in-depth experience of **indications, planning, surgical strategy, rehabilitation and complications** over a period of years in busy osteotomy practices.

This consensus does not attempt to cover the expanding variety and scope of highly specialized periarticular osteotomy techniques nor their extended indications. It is a work directed at the surgeon with an 'every day' osteotomy practice to provide the clearest statements possible to educate, guide and instruct.

#### **Methodology:**

The aim of the ESSKA consensus is to provide guidance to the everyday knee surgeon for the most common application of osteotomy around the knee: *the painful, degenerative varus joint*. This is a "Formal Consensus" (derived from a Delphi methodology) to address 5 specific sections upon the subject of osteotomy around the knee for this application. The sections are **Indications, Planning, Surgical Strategy, Rehabilitation and Complications**. The project steering group was formed by the Osteotomy committee of ESSKA, and 2 further osteotomy experts chosen for their skillset of literature analysis. 5 experienced osteotomy experts from the committee formed the *Questions Group*. This group formulated a series of enquiries to cover the relevant and important aspects of osteotomy surgery under each of the headings above. All sections were then individually allocated to a different osteotomy expert whose brief it was to scrutinize the available scientific evidence in the orthopaedic literature and to distill the important and relevant findings. These 5 surgeons, the *Literature Group*, reported back to the Questions Group who then formulated statements drawn from the scientific evidence and from their own expert opinion. The respective statements were given a scientific grade based upon existing literature (screened from 2000 - 2020) and their expert opinion.

Grade A: high scientific level

Grade B: scientific presumption

Grade C: low scientific level

Grade D: expert opinion



A first draft was reviewed and amended twice by another independent panel of 26 experienced osteotomy surgeons (rating group). The final text underwent a second review process by an additional peer review group comprising 50 clinicians and clinical scientists from different European countries. This complex and long process has two main advantages. It limits any individual or organizational bias or conflict of interest, and it may have a better chance of general acceptance due to the involvement of a large number of participants of different countries. This “consensus investigation” has attempted to bring some light into these mundane but extremely important clinical entities. In addition, the recommendations are presented free from economic constraints.

We hope the following recommendations will consider these messages, avoid any conflicting or political statements, and provide a well-balanced treatment instruction for the ‘every day’ surgeon undertaking osteotomy surgery for patients with a painful degenerative varus knee.

Acknowledgement of those involved :

**Chairmen of Consensus Steering Committee**

Matt Dawson (UK)  
Matthieu Ollivier (France)

**ESSKA Consensus Projects Advisor**

Philippe Beaufils (France)

**Members of Osteotomy Consensus Steering Committee**

Bogdan Ambroziv (Slovenia)  
Steven Claes (Belgium)  
Sandro Fucentese (Switzerland)  
Ronald van Heerwaarden (Netherlands)  
Ragbir Khakha (UK)  
Kristian Kley (Germany)  
Dietrich Pape (Luxembourg)  
Vlad Predescu (Romania)  
Steffen Schroter (Germany)  
Konrad Slynarski (Poland)  
Silvio Villascusa (Spain)  
Adrian Wilson (UK)

**Additional Members of Literature Group**

David Elson (UK)  
Alejandro Espejo Reina (Spain)

**With contributions from**

Toon Claes, Stijn Bartholomeeusen, Willem-Jan Vleugels, Wouter Van Genechten (all Belgium), James Broderick (Ireland) and Tamer Sweed (UK)



### **Members of Osteotomy Consensus Ratings Group**

Cristian Fink (Austria), Alexander Benko (Belarus), Peter Verdonk (Belgium), Vojtech Havlas (Czech Republic), Lars Blond (Denmark), Jukka Ristiniemi, (Finland), Jean Marie Fayard, Nicolas Gravelau (both France), Michael Hantes (Greece), Michele Malavolta, Roberto Rossi (both Italy), Romain Seil (Luxembourg), Jacek Walawski , Pawel Walawski (both Poland), Levi Reina Fernandes (Portugal), Stefan Mogos (Romania), Leonid Solomon (Russia), Pablo Gelber, Pablo Crespo (both Spain), Mats Brittberg (Sweden), Nevzat Reha Tandogan), Tahsin Beyzadeoglu (both Turkey), James Robinson, Martyn Snow (both UK)

### **Members of Osteotomy Consensus Peer Group**

Oleg Eismont (Belarus), Geert Van Damme (Belgium), Semin Becirbegovic (Bosnia), Peter Lavard, Kristoffer Weisskirchner Barfod, Andreas Kappel (all Denmark), Paul-Sander Vahi (Estonia), Mirouse Guillaume, Choufani Camille, Morvan Antoine (all France), Matthias Feucht, Georg Brandl (both Germany-Austria-Switzerland), Michael Iosifidis, Athanasios Ververidis (both Greece), Andras Tallay (Hungary), Mihai Vioreanu (Ireland), Francesco Saccia, Kleber Garcia Parra, Alessio Maione, Davide Bonasia (all Italy), Eriks Ozols (Latvia), Renaud Siboni (Luxembourg), Nienke van Egmond, Reinoud Brouwer, Robbert Gaasbeek (all Netherlands), Tor Kjetil Nerhus, Arne Kristian Aune, Gilbert Moatsche (all Norway), Lukasz Luboiński, Tomasz Pardała (both Poland), Manuel Vieira da Silva, Helder Nogueira, Paulo Ribeiro de Oliveira (all Portugal), Vlad Georgeanu, Radu Fleaca (both Romania), Vadim Dubrov (Russia), Tomaz Malovrh (Slovakia), Vicente López, José Silberberg, Tomas Roca, Carlos Martin, Rafael Arriaza (all Spain), Mikael Östin, Karl Eriksson, Anders Stålmán (all Sweden), İrfan Esenkaya, Elcil Kaya Bicer and Meriç Ünal (all Turkey)

### **ESSKA office**

For organisational and administrative assistance throughout and with special thanks for the fanatastic dedication of Anna Hansen Rak without whom this work would not have been possible.

## **Section 1: INDICATIONS and CONTRAINDICATIONS**

1. Is knee osteotomy (KO) for varus medial osteoarthritis preferentially indicated for a specific age group or gender?
2. Do extreme values of Body Mass Index (BMI) contraindicate KO?
3. How does smoking of nicotine products influence decision to perform osteotomy?
4. Is early lateral compartment osteoarthritis (OA) a contraindication to KO?
5. Is early lateral patello-femoral OA a contraindication to KO?
6. Is significant bone loss with uncorrectable varus deformity a contraindication to osteotomy?
7. Is there a risk of metal-allergy with materials used in KO?

### **1) Is knee osteotomy (KO) for varus medial osteoarthritis preferentially indicated for a specific age group or gender?**

The general status of the patient is considered more important than age alone. There is no clear cut-off value that preferentially indicates osteotomy at any specific age. Similarly, no outcome data exist to suggest superior or inferior clinical outcome in younger patients compared with those over 55 years of age. Older patients will enjoy improved outcomes where otherwise appropriate indications are followed.

#### **Grade C**

There is no evidence that male or female gender influence KO outcomes.

#### **Grade B**

#### **Literature review:**

Although the level of evidence found is limited, age might play an important role in knee osteotomy in the literature reviewed. It is not possible to set a clear threshold, as it varies between 40-65 years old in the different studies; however, it could be stated that younger patients have better outcomes and survival rates.

Failure is not homogeneously defined in literature, as it has been presented as a lower functional outcome according to clinical scales, the presence of adverse events, progression of arthritis or conversion to arthroplasty among others. Avoiding the endpoint of conversion to arthroplasty, which might be influenced by age itself and other factors, patients under the age of 40 showed improved functional outcomes in the short term [54]; similar outcomes were found in patients under 50 y.o. in the long term. [5] More adverse events (OR 4.1), longer stay in hospital (OR 4.1) and



more readmissions (OR 2.1) were found in patients above 45 y.o.[9] furthermore, an association was found between older age and increased risk of intraarticular fracture[15]. Considering any revision surgery, a 2.1 HR was found in patients above 50 y.o.[12] same result was found in patients above 55 y.o.[21]

Several papers consider conversion to arthroplasty as the endpoint of survival of knee osteotomy (KO). Lau et al[39] only studied patients under 55 y.o. and reported a survival rate of 87.4%. Bouguennec et al set the threshold for failure (progression of arthritis or persistent pain) in 54 y.o.[6] Jin et al considered failure as conversion to TKR or KSS<60 and found a HR 4,69 in patients above 65 y.o.[27] Regarding the big registries, W-Dahl.[73] found lower conversion rates to arthroplasty in patients under 40 y.o. in the Swedish registry, while Niinimaki et al. found a better survivorship in patients under 50 y.o.[50] Considering the progression of the risk with older age, Pannell found an increase of 8% per year of age[57] while Khoshbin et al. found a 5% increased risk per year above 46 y.o.[32], and Trieb et al. found a 7.6% of increased risk per year[70].

Despite age seems to play an important role on KO outcomes, it shouldn't be considered as a contraindication to undergo such surgery: an important improvement in functional outcomes has been found concerning the preoperative status[54]; furthermore, Kohn et al found no differences in outcomes after KO regarding age[38]; Howells et al. showed very interesting outcomes, obtaining better functional outcomes in patients over 55 y.o., although the conversion rate to arthroplasty was higher in this group[21].

The degree of cartilage wear, which may be related to age (although it remains unclear in the literature reviewed), is also correlated with KO outcomes. A grade  $\geq 3$  in Ählback's classification was correlated with worse survival [1, 7], while higher degrees of chondral lesions (Outerbridge 3-4) had decreased functional outcomes[54].

The influence of gender in KO remains unclear. According to Cotter et al., female gender was related to increased stay in hospital. Moreover, female gender presented delayed consolidation[76]. Niinimaki [50] and Pannell[57] found increased conversion to TKR in female patients in their series. Nonetheless, most of the literature reviewed demonstrated no differences between sexes[7, 11, 30,] and Bouguennec et al found an association between male gender and poorer outcomes[5]

**Level of evidence: 3**

## **2) Do extreme values of Body Mass Index (BMI) contraindicate KO?**

**BMI influences KO outcomes, with higher complication rates in patients with BMI>30 or BMI<21. Whilst no recommendation can be extracted from the literature on a specific 'cut off' value, a case by case assessment must be made if the BMI >35 and patients counselled regarding the high risks involved.**

**Grade C**

**Literature review:**

The nutritional status of the patient is an important issue to take into account in KO. Obesity is the main factor studied in literature: it has been defined according to the body mass index in all studies; The BMI threshold varies from one study to another, but most of them use a BMI>30 as the cut-off

point; Cotter et al [9] found an increase in adverse events in patients with BMI >30, while Floekermeier et al.[9] found poorer functional outcomes in the same group of patients. Kawai et al.[30] and Yokoyama et al.[77] found delayed union in patients with increased BMI.

Obesity has also a role in different secondary aspects that may influence the final outcomes of KO, although there's no high level of evidence in the literature; obese patients showed less improvement of the chondral lesions of the medial compartment after KO[37]; furthermore, there was decreased healing of the posterior root of the medial meniscus[7], and increased blood loss[80]: after KO in this group of patients: these aspects might impair clinical outcomes, although it was not demonstrated yet.

According to the conversion of the osteotomy to a TKR, different thresholds have been described: Bouguennec et al [6] found increased conversion rates in patients with BMI>25, and even more if >35; Li et al.[42] set the cut-off point in 25.25 while Akizuki et al.[2] did it in 27.5. Finally, other authors set the threshold in a BMI>30[12].

Most articles analyze excessive BMI as the main source of complications; Meidinger et al.[47] found that obesity increased the risk of non-union and they consider that the reason for this finding is an increase in the micromotion of the osteotomy; interestingly, on the other hand, they found that patients with low BMI (20.2 - 20.4; all of them female patients) also had more risk of non-union, but in this case due to the relatively excessive rigidity of the angular-stable plate (Tomofix), that would reduce said micromotion of the osteotomy.

Scarce data exists regarding the specific role of osteoporosis in KO. In their study, Yoon et al[79] found that osteoporosis increased risk of revision surgery in patients with KO as primary surgery (to TKR) compared to patients receiving a TKR as the primary surgery (to revision TKR) (HR 3.53); however, the same authors state that other factors such as that surgeons would be more prone to review a painful HTO than a painful TKR may bias their outcomes.

**Level of evidence: 3**

### **3) How does smoking of nicotine products influence decision to perform osteotomy?**

**Smoking and nonsmoking patients will all benefit from KO although smokers must be informed of the increased risks of complication such as infection and delayed union.**

**Grade B**

**Smokers should stop nicotine abuse for at least three weeks before and three weeks after surgery**

**Grade D**

**Literature review:**

It is known that smoking delays bone healing: it harms osteoblasts and their homeostasis through the accumulation of reactive oxygen species. Regarding KO, smoking should be recorded during the assessment of the patient, because it may have a role in local issues around the surgical site and the patient should be well informed.

Sikorski and Sikorska[65] found a 17% increased risk in smokers undergoing HTO, a figure similar to the one found in patients undergoing TKA; however, smokers undergoing KO had more local adverse



events (neurovascular issues, deep infection or wound problems). Kawata et al.[31] also found an increase in surgical site infection. Nevertheless, Cotter et al.[9] found no differences in adverse event, extended length of stay or readmission, so those local complications might not be so serious to alter the normal postoperative process after KO.

Probably, the most documented complication in smokers undergoing a KO is delayed or non-union of the osteotomy. Van Houten et al.[20] found an increased risk for non-union in these patients (OR: 4.1), as well as Meidinger[47] while Schröter[64] found delayed gap filling even one year after the operation. However, it remains unclear whether this complication impairs functional outcomes: Floekermeier et al.[14] found no correlation between smoking and functional outcomes; Spahn et al.[67] didn't find more complications, but did find poorer clinical outcomes, and they wonder whether this fact would be related to delayed union (although they didn't study it); on the other hand, although Niemeyer et al.[49] found improved outcomes in the IKDC scale in nonsmoking patients, they concluded that both smoking and nonsmoking patients benefitted from KO.

**Level of evidence: 3**

#### **4) Is early lateral compartment osteoarthritis (OA) a contraindication to KO?**

**Early signs of OA (diagnosed by radiography, MRI or arthroscopy) do not impair outcomes and are therefore not contraindications to KO surgery although it is important to recognise the status of the lateral meniscus. KO is a potentially powerful intervention in the younger patient even with early lateral compartment disease.**

**Substantial lateral compartment OA (Kellgren Lawrence 3 and 4 ) is a relative contraindication to KO and may well impact upon final outcome. Positioning of the weight bearing line (WBL) into the lateral compartment in such a circumstance may accelerate lateral compartment disease. A more neutral positioning of WBL may therefore be a more viable alternative.**

#### **Grade D**

##### **Literature review:**

The effects of valgus KO on the lateral compartment in the case of varus arthritis were studied by Ziegler, Madry, et al [44, 81, 82], who found no significant changes after KO in the menisci, the cartilage of the subchondral bone after 6 months in a sheep model. Similar outcomes were found by Bick et al in a prospective MRI study[4].

More specifically, Kim et al[33] found that mild lateral degeneration did not impair clinical outcomes or MRI and second-look arthroscopic findings after an opening wedge high tibial osteotomy in the mid-term; furthermore, the presence of such preoperative changes did not involve a more rapid decline in cartilage degeneration on the lateral compartment[33, 45]. No differences were detected in clinical outcomes in a prospective series by Niemeyer et al[49] when comparing groups of patients according to their cartilage status (ICRS 0-2) after excluding full thickness cartilage lesions. Jin et al [27] did not exclude patients with advanced cartilage injuries and they found that ICRS grade  $\geq 2$  on the lateral compartment was a risk for KO failure (HR 3.38).

Special care should be taken in the presence of a lateral discoid meniscus, as valgus KO outcomes may be impaired due to the increased pressures of the lateral compartment: the lateral discoid meniscus would accelerate its degeneration<sup>9</sup> and the lateral compartment osteoarthritis would increase[59].



**Level of evidence: 3**

**5) Is early lateral patello-femoral OA a contraindication to KO?**

**Patello-femoral OA (regardless of the diagnostic tool : MRI, radiography or arthroscopy) is not an absolute contraindication to KO. In certain specific cases adaptations of the conventional technique are recommended to avoid reduction in patella height (including descending biplanar cut and lateral closing wedge osteotomy).**

**Grade B**

**Literature review:**

The patellofemoral joint is a matter of concern when performing a KO, due to the biomechanical changes that it undergoes secondarily to the osteotomy. Different factors should be taken into account, among which the status of the patellofemoral cartilage and patellar height have received the main focus in literature.

First of all, Jeong et al[25] didn't detect any risk factors associated with excessive lateral pressure syndrome (which might be a cause of further cartilage damage) in patients undergoing KO after studying a series of candidates to KO surgery with SPECT-CT. According to Kim et al[33], mild patellofemoral degenerative changes did not affect the MRI, arthroscopic and clinical outcomes of KO. Along the same lines, Jin et al [28] found that patellofemoral cartilage injury was not related to failure of KO. Furthermore, Goshima et al[17] demonstrated that although a progression in patellofemoral chondral injury could be seen in 27% radiologically and 45% arthroscopically, changes in patellofemoral alignment and patellofemoral OA progression did not affect the clinical outcomes of KO at mid-term follow-up. Tanaka et al[69] found increased deterioration of PF cartilage injuries in patients with opening gap  $\geq 13$  mm or  $\Delta mPTA \geq 9^\circ$ , although there was no correlation with clinical outcomes.

On the other hand, though Niemeyer et al[49] couldn't find significant differences in outcomes between patients with different grades of patellofemoral chondral injury, they found a tendency towards patients with patellofemoral chondral injury showing worse outcomes than patients without it; however, both groups of patients improved significantly. According to Yoon et al[79], the patellofemoral joint was adversely affected by KO: overcorrection causing excessive valgus alignment led to further progression of degenerative changes in the patellofemoral joint and inferior clinical outcomes. Kim et al[34] also found increased patellofemoral chondral lesions after KO; however, they only found a 11.4% of cases with anterior knee pain.

In cases of patellar chondral lesions, a distally directed biplanar osteotomy has been suggested, to avoid increased patellofemoral pressure[18, 36].

Another factor that should be taken into account when performing a KO is patellar height. Otsuki et al[55] set a proportion of a 1.7% of decrease in Caton-Deschamps index with a  $1^\circ$  correction angle, but they failed to demonstrate the association between these findings and clinical outcomes; Akaoka et al[1] compared patients with double level osteotomy with patients with single OWHTO and discovered similar changes in the patellofemoral joint of both groups, again without demonstrating any clinical correlation with such changes; Jingbo et al[29] stated that patellar height is not altered when the correction of the KO is  $< 15^\circ$  and good outcomes can be expected. Similarly, Lee et al[41] showed that changes in patellofemoral alignment didn't impair clinical outcomes.



Adjacent TTO[43] and Hybrid Closing Wedge HTO[23, 56] have been proposed to improve PF joint congruity.

**Level of evidence: 3**

**6) Is significant bone loss with intra-articular varus deformity a contraindication to osteotomy?**

**Intra-articular deformity questions the indication for KO as the usual emphasis is on extra-articular deformity correction.**

**Grade D**

**In case of isolated Intra-articular wear, KO outcomes are unpredictable.**

**Grade C**

**In case of combined intra- and extra-articular deformity, the amount of “potential” soft tissue correction should be estimated to avoid massive over-correction.**

**Grade C**

**Literature review:**

Intra-articular deformity of the varus knee is mainly defined by the increase of the joint line convergence angle (JLCA). It can be due to a ligament laxity[52] or to a medial compartment wear[19].

JLCA has to be taken into account when planning a KO because bony varus deformity can be overestimated, resulting in an overcorrection of the global deformity[16, 53, 58]. Furthermore, some authors advocate the use of a single-leg stance X-Rays because an increase on JLCA has been found compared to double-leg stance X-Rays[3, 40, 75]. Different strategies are available to predict the behaviour of the JLCA during the KO[40, 48, 66, 68], and a tipping point of 6° has been proposed[26] as the JLCA threshold that a regular HTO is able to correct. For patients with higher JLCA, several techniques have been proposed to correct not only the tibial varus, but also the intra-articular deformity, like proximal tibia condylar osteotomies[8, 22], gradual corrections[24, 61], or combined procedures with several osteotomies[63, 72] or adding a medial uni-compartmental knee arthroplasty[48].

Although HTO alone may have a limited capability to adequately correct the JLCA[26], and further research is needed, it does not seem to be a contraindication in patients with uncorrectable varus deformity.

**Level of evidence: 4**

**7) Is there a risk of metal-allergy with materials used in KO?**

**There is no specific evidence regarding metal allergies in the KO setting. Modern angle stable implants are manufactured from pure titanium and the alloys most commonly associated with a potential for allergy no longer used.**

**Therefore, in daily practice it is recommended that the choice of implant is based on conventional principles even for those patients with “confirmed” metal-allergy.**

## Grade C

### Literature review:

Allergy or hypersensitivity to implant materials have been described in literature related to different orthopaedic procedures, especially in arthroplasty papers. Although it is a recognized complication that may cause undefined pain and swelling[11], it has been reported to be the reason for TKA revision surgery in only 0.06-0.32% of the cases[83]. Saccomanno et al even wonder whether metal allergy is a real problem in total knee replacements, advising against routine allergy testing or patch testing prior to TKA, unless a clear history of local or systemic reactions has been reported[62].

There is no specific evidence regarding metal allergies in KO. However, the materials most commonly employed in osteotomy plates have been studied in literature: stainless steel implants used for internal fixation were found to produce a 1.2-6% of nickel allergies, although no substantial complications were noticed[60]. According to Wood et al[74], in a review article, Titanium allergy has been reported 3 times in Orthopaedic surgery: one in an osteosynthesis case, one in a total knee replacement and one after rotator cuff surgery. Polyetheretherketone (PEEK) hypersensitivity is very rare, although it has been published as case reports[37, 46].

**Level of evidence: -**

### References:

1. Akaoka Y, Iseki T, Kanto R, Onishi S, Tachibana T, Tensho K, Yoshiya S, Nakayama H (2020) Changes in patellar height and patellofemoral alignment following double level osteotomy performed for osteoarthritic knees with severe varus deformity. *Asia-Pac J Sports Med Arthrosc Rehabil Technol* 22:20–26
2. Akizuki S, Shibakawa A, Takizawa T, Yamazaki I, Horiuchi H (2008) The long-term outcome of high tibial osteotomy: a ten- to 20-year follow-up. *J Bone Joint Surg Br* 90:592–596
3. Bardot L-P, Micicoi G, Favreau H, Zeman P, Khakha R, Ehlinger M, Ollivier M (2022) Global varus malalignment increase from double-leg to single-leg stance due to intra-articular changes. *Knee Surg Sports Traumatol Arthrosc Off J ESSKA* 30:715–720
4. Bick F, Iffland Y, Zimmermann E, Welsch F, Hoffmann R, Stein T (2019) The medial open-wedge osteotomy generates progressive intrameniscal integrity changes in the lateral knee compartment: a prospective MR-assessment after valgic osteotomy in the varus gonarthritic knee. *Knee Surg Sports Traumatol Arthrosc Off J ESSKA* 27:1339–1346
5. Bouguennec N, Mergenthaler G, Gicquel T, Briand C, Nadau E, Pailhé R, Hanouz JL, Fayard JM, Rochcongar G, Francophone Arthroscopy Society (2020) Medium-term survival and clinical and radiological results in high tibial osteotomy: Factors for failure and comparison with unicompartmental arthroplasty. *Orthop Traumatol Surg Res OTSR* 106:S223–S230
6. Bouguennec N, Mergenthaler G, Gicquel T, Briand C, Nadau E, Pailhé R, Hanouz JL, Fayard JM, Rochcongar G, Francophone Arthroscopy Society (2020) Medium-term survival and clinical and radiological results in high tibial osteotomy: Factors for failure and comparison with unicompartmental arthroplasty. *Orthop Traumatol Surg Res OTSR* 106:S223–S230
7. Can A (2018) What Determines the Success of Closed-Wedge High Tibial Osteotomy: Severity of Malalignment, Obesity, Follow-up Period, or Age? *Sisli Etfal Hastan Tip Bul Med Bull Sisli Hosp* 52:6–12

8. Chiba K, Yonekura A, Miyamoto T, Osaki M, Chiba G (2017) Tibial condylar valgus osteotomy (TCVO) for osteoarthritis of the knee: 5-year clinical and radiological results. *Arch Orthop Trauma Surg* 137:303–310
9. Cotter EJ, Gowd AK, Bohl DD, Getgood A, Cole BJ, Frank RM (2020) Medical Comorbidities and Functional Dependent Living Are Independent Risk Factors for Short-Term Complications Following Osteotomy Procedures about the Knee. *Cartilage* 11:423–430
10. Efe T, Ahmed G, Heyse TJ, Boudriot U, Timmesfeld N, Fuchs-Winkelmann S, Ishaque B, Lakemeier S, Schofer MD (2011) Closing-wedge high tibial osteotomy: Survival and risk factor analysis at long-term follow up. *BMC Musculoskelet Disord BioMed Central Ltd* 12:46
11. Faschingbauer M, Renner L, Boettner F (2017) Allergy in Total Knee Replacement. Does It Exist?: Review Article. *HSS J Musculoskelet J Hosp Spec Surg* 13:12–19
12. Flecher X, Parratte S, Aubaniac J-M, Argenson J-NA (2006) A 12-28-year followup study of closing wedge high tibial osteotomy. *Clin Orthop* 452:91–96
13. Flecher X, Parratte S, Aubaniac J-M, Argenson J-NA (2006) A 12-28-year followup study of closing wedge high tibial osteotomy. *Clin Orthop* 452:91–96
14. Floerkemeier S, Staubli AE, Schroeter S, Goldhahn S, Lobenhoffer P (2014) Does obesity and nicotine abuse influence the outcome and complication rate after open-wedge high tibial osteotomy? A retrospective evaluation of five hundred and thirty three patients. *Int Orthop* 38:55–60
15. Giuseffi SA, Replogle WH, Shelton WR (2015) Opening-Wedge High Tibial Osteotomy: Review of 100 Consecutive Cases. *Arthrosc J Arthrosc Relat Surg Off Publ Arthrosc Assoc N Am Int Arthrosc Assoc* 31:2128–2137
16. Goshima K, Sawaguchi T, Shigemoto K, Iwai S, Fujita K, Yamamuro Y (2019) Comparison of Clinical and Radiologic Outcomes Between Normal and Overcorrected Medial Proximal Tibial Angle Groups After Open-Wedge High Tibial Osteotomy. *Arthrosc J Arthrosc Relat Surg Off Publ Arthrosc Assoc N Am Int Arthrosc Assoc* 35:2898-2908.e1
17. Goshima K, Sawaguchi T, Shigemoto K, Iwai S, Nakanishi A, Ueoka K (2017) Patellofemoral Osteoarthritis Progression and Alignment Changes after Open-Wedge High Tibial Osteotomy Do Not Affect Clinical Outcomes at Mid-term Follow-up. *Arthrosc J Arthrosc Relat Surg Off Publ Arthrosc Assoc N Am Int Arthrosc Assoc* 33:1832–1839
18. Han C, Li X, Tian X, Zhao J, Zhou L, Tan Y, Ma S, Hu Y, Chen H, Huang Y (2020) The effect of distal tibial tuberosity high tibial osteotomy on postoperative patellar height and patellofemoral joint degeneration. *J Orthop Surg* 15:466
19. Heijens E, Kornherr P, Meister C (2016) The coronal hypomochlion: a tipping point of clinical relevance when planning valgus producing high tibial osteotomies. *Bone Jt J* 98-B:628–633
20. van Houten AH, Heesterbeek PJC, van Tienen TG, Wymenga AB (2014) Medial open wedge high tibial osteotomy: can delayed or nonunion be predicted? *Clin Orthop* 472:1217–1223
21. Howells NR, Salmon L, Waller A, Scanelli J, Pinczewski LA (2014) The outcome at ten years of lateral closing-wedge high tibial osteotomy: determinants of survival and functional outcome. *Bone Jt J* 96-B:1491–1497
22. Igarashi K, Yamamoto N, Hayashi K, Matsubara H, Takeuchi A, Miwa S, Tsuchiya H (2020) Distal Tibial Tuberosity Focal Dome Osteotomy Combined With Intra-Articular Condylar Osteotomy (Focal Dome Condylar Osteotomy) for Medial Osteoarthritis of the Knee Joint. *Arthrosc Tech* 9:e1079–e1086
23. Ishimatsu T, Takeuchi R, Ishikawa H, Yamaguchi Y, Maeyama A, Osawa K, Jung W-H (2019) Hybrid closed wedge high tibial osteotomy improves patellofemoral joint congruity compared with open wedge high tibial osteotomy. *Knee Surg Sports Traumatol Arthrosc Off J ESSKA* 27:1299–1309

24. Janoyer M (2019) Blount disease. *Orthop Traumatol Surg Res OTSR* 105:S111–S121
25. Jeong JH, Chang MJ, Kang S-B, Chang CB, Yoon C, Park J, Lee SA (2018) Prevalence of excessive lateral pressure syndrome in varus osteoarthritic candidates for high tibial osteotomy. *The Knee* 25:1192–1196
26. Ji W, Luo C, Zhan Y, Xie X, He Q, Zhang B (2019) A residual intra-articular varus after medial opening wedge high tibial osteotomy (HTO) for varus osteoarthritis of the knee. *Arch Orthop Trauma Surg* 139:743–750
27. Jin C, Song E-K, Santoso A, Ingale PS, Choi I-S, Seon J-K (2020) Survival and Risk Factor Analysis of Medial Open Wedge High Tibial Osteotomy for Unicompartement Knee Osteoarthritis. *Arthrosc J Arthrosc Relat Surg Off Publ Arthrosc Assoc N Am Int Arthrosc Assoc* 36:535–543
28. Jin C, Song EK, Santoso A, Ingale PS, Choi IS, Seon JK (2020) Survival and Risk Factor Analysis of Medial Open Wedge High Tibial Osteotomy for Unicompartement Knee Osteoarthritis. *Arthrosc - J Arthrosc Relat Surg Arthroscopy Association of North America* 36:535–543
29. Jingbo C, Mingli F, Guanglei C, Zheng L, Shuai A, Jiang H (2020) Patellar Height Is Not Altered When the Knee Axis Correction Is Less than 15 Degrees and Has Good Short-Term Clinical Outcome. *J Knee Surg* 33:536–546
30. Kawai R, Kawashima I, Maeda A, Tsukada M, Aoshiba H, Kusaka Y, Tsukahara T (2020) The factors affecting the timing of bone union after closing-wedge high tibial osteotomy. *J Clin Orthop Trauma* 11:S526–S529
31. Kawata M, Jo T, Taketomi S, Inui H, Yamagami R, Matsui H, Fushimi K, Yasunaga H, Tanaka S (2021) Type of bone graft and primary diagnosis were associated with nosocomial surgical site infection after high tibial osteotomy: analysis of a national database. *Knee Surg Sports Traumatol Arthrosc Off J ESSKA* 29:429–436
32. Khoshbin A, Sheth U, Ogilvie-Harris D, Mahomed N, Jenkinson R, Gandhi R, Wasserstein D (2017) The effect of patient, provider and surgical factors on survivorship of high tibial osteotomy to total knee arthroplasty: a population-based study. *Knee Surg Sports Traumatol Arthrosc Springer Berlin Heidelberg* 25:887–894
33. Kim DH, Kim SC, Yoon JS, Lee YS (2020) Are There Harmful Effects of Preoperative Mild Lateral or Patellofemoral Degeneration on the Outcomes of Open Wedge High Tibial Osteotomy for Medial Compartmental Osteoarthritis? *Orthop J Sports Med* 8:2325967120927481
34. Kim K-I, Kim D-K, Song S-J, Lee S-H, Bae D-K (2017) Medial Open-Wedge High Tibial Osteotomy May Adversely Affect the Patellofemoral Joint. *Arthrosc J Arthrosc Relat Surg Off Publ Arthrosc Assoc N Am Int Arthrosc Assoc* 33:811–816
35. Kim K-I, Seo M-C, Song S-J, Bae D-K, Kim D-H, Lee SH (2017) Change of Chondral Lesions and Predictive Factors After Medial Open-Wedge High Tibial Osteotomy With a Locked Plate System. *Am J Sports Med* 45:1615–1621
36. Kloos F, Becher C, Fleischer B, Feucht MJ, Hohloch L, Südkamp N, Niemeyer P, Bode G (2019) High tibial osteotomy increases patellofemoral pressure if adverted proximal, while open-wedge HTO with distal biplanar osteotomy discharges the patellofemoral joint: different open-wedge high tibial osteotomies compared to an extra-articular unloading device. *Knee Surg Sports Traumatol Arthrosc Off J ESSKA* 27:2334–2344
37. Kofler L, Wambacher M, Schweinzer K, Scherl M, Kofler H (2017) Allergic Reaction to Polyether Ether Ketone Following Cross-Reactivity to Epoxy Resin. *J Cutan Med Surg* 21:78–79
38. Kohn L, Sauerschnig M, Iskansar S, Lorenz S, Meidinger G, Imhoff AB, Hinterwimmer S (2013) Age does not influence the clinical outcome after high tibial osteotomy. *Knee Surg Sports Traumatol Arthrosc Off J ESSKA* 21:146–151

39. Lau LCM, Fan JCH, Chung K-Y, Cheung K-W, Man GCW, Hung Y-W, Kwok CKB, Ho KKW, Chiu K-H, Yung PSH (2021) Satisfactory long-term survival, functional and radiological outcomes of open-wedge high tibial osteotomy for managing knee osteoarthritis: Minimum 10-year follow-up study. *J Orthop Transl* 26:60–66
40. Lee DK, Wang JH, Won Y, Min YK, Jaiswal S, Lee BH, Kim J-Y (2020) Preoperative latent medial laxity and correction angle are crucial factors for overcorrection in medial open-wedge high tibial osteotomy. *Knee Surg Sports Traumatol Arthrosc Off J ESSKA* 28:1411–1418
41. Lee YS, Lee SB, Oh WS, Kwon YE, Lee BK (2016) Changes in patellofemoral alignment do not cause clinical impact after open-wedge high tibial osteotomy. *Knee Surg Sports Traumatol Arthrosc Off J ESSKA* 24:129–133
42. Li H-B, Nie S, Lan M, Tang Z-M, Liao X-G (2020) The risk factors for early conversion to total knee arthroplasty after high tibial osteotomy. *Comput Methods Biomech Biomed Engin* 1–7
43. Longino PD, Birmingham TB, Schultz WJ, Moyer RF, Giffin JR (2013) Combined tibial tubercle osteotomy with medial opening wedge high tibial osteotomy minimizes changes in patellar height: a prospective cohort study with historical controls. *Am J Sports Med* 41:2849–2857
44. Madry H, Ziegler R, Orth P, Goebel L, Ong MF, Kohn D, Cucchiaroni M, Pape D (2013) Effect of open wedge high tibial osteotomy on the lateral compartment in sheep. Part I: Analysis of the lateral meniscus. *Knee Surg Sports Traumatol Arthrosc Off J ESSKA* 21:39–48
45. Majima T, Yasuda K, Katsuragi R, Kaneda K (2000) Progression of joint arthrosis 10 to 15 years after high tibial osteotomy. *Clin Orthop* 177–184
46. Maldonado-Naranjo AL, Healy AT, Kalfas IH (2015) Polyetheretherketone (PEEK) intervertebral cage as a cause of chronic systemic allergy: a case report. *Spine J Off J North Am Spine Soc* 15:e1-3
47. Meidinger G, Imhoff AB, Paul J, Kirchhoff C, Sauerschnig M, Hinterwimmer S (2011) May smokers and overweight patients be treated with a medial open-wedge HTO? Risk factors for non-union. *Knee Surg Sports Traumatol Arthrosc Off J ESSKA* 19:333–339
48. Micicoi G, Khakha R, Kley K, Wilson A, Cerciello S, Ollivier M (2020) Managing intra-articular deformity in high Tibial osteotomy: a narrative review. *J Exp Orthop* 7:65
49. Niemeyer P, Schmal H, Hauschild O, von Heyden J, Südkamp NP, Köstler W (2010) Open-wedge osteotomy using an internal plate fixator in patients with medial-compartment gonarthrosis and varus malalignment: 3-year results with regard to preoperative arthroscopic and radiographic findings. *Arthrosc J Arthrosc Relat Surg Off Publ Arthrosc Assoc N Am Int Arthrosc Assoc* 26:1607–1616
50. Niinimäki TT, Eskelinen A, Mann BS, Junnila M, Ohtonen P, Leppilahti J (2012) Survivorship of high tibial osteotomy in the treatment of osteoarthritis of the knee: Finnish registry-based study of 3195 knees. *J Bone Joint Surg Br* 94:1517–1521
51. Niinimäki TT, Eskelinen A, Mann BS, Junnila M, Ohtonen P, Leppilahti J (2012) Survivorship of high tibial osteotomy in the treatment of osteoarthritis of the knee: Finnish registry-based study of 3195 knees. *J Bone Jt Surg - Ser B* 94 B:1517–1521
52. Noyes FR, Barber-Westin SD, Hewett TE (2000) High tibial osteotomy and ligament reconstruction for varus angulated anterior cruciate ligament-deficient knees. *Am J Sports Med* 28:282–296
53. Ogawa H, Matsumoto K, Ogawa T, Takeuchi K, Akiyama H (2016) Preoperative varus laxity correlates with overcorrection in medial opening wedge high tibial osteotomy. *Arch Orthop Trauma Surg* 136:1337–1342
54. Orrego M, Besa P, Orrego F, Amenabar D, Vega R, Irribarra L, Espinosa J, Vial R, Phillips V, Irrarázaval S (2020) Medial opening wedge high tibial osteotomy: more than ten years of





- experience with Puddu plate technique supports its indication. *Int Orthop International Orthopaedics* 44:2021–2026
55. Otsuki S, Murakami T, Okamoto Y, Nakagawa K, Okuno N, Wakama H, Neo M (2018) Risk of patella baja after opening-wedge high tibial osteotomy. *J Orthop Surg Hong Kong* 26:2309499018802484
  56. Otsuki S, Murakami T, Okamoto Y, Nakagawa K, Okuno N, Wakama H, Neo M (2019) Hybrid high tibial osteotomy is superior to medial opening high tibial osteotomy for the treatment of varus knee with patellofemoral osteoarthritis. *Knee Surg Sports Traumatol Arthrosc Off J ESSKA* 27:1332–1338
  57. Pannell WC, Heidari KS, Mayer EN, Zimmerman K, Heckmann N, McKnight B, Hill JR, Vangsness CT, Hatch GF, Weber AE (2019) High Tibial Osteotomy Survivorship: A Population-Based Study. *Orthop J Sports Med* 7:1–7
  58. Park J-G, Kim J-M, Lee B-S, Lee S-M, Kwon O-J, Bin S-I (2020) Increased preoperative medial and lateral laxity is a predictor of overcorrection in open wedge high tibial osteotomy. *Knee Surg Sports Traumatol Arthrosc Off J ESSKA* 28:3164–3172
  59. Prakash J, Song E-K, Lim HA, Shin YJ, Jin C, Seon J-K (2018) High tibial osteotomy accelerates lateral compartment osteoarthritis in discoid meniscus patients. *Knee Surg Sports Traumatol Arthrosc Off J ESSKA* 26:1845–1850
  60. Roberts TT, Haines CM, Uhl RL (2017) Allergic or Hypersensitivity Reactions to Orthopaedic Implants. *J Am Acad Orthop Surg* 25:693–702
  61. Sabharwal S, Sabharwal S (2017) Treatment of Infantile Blount Disease: An Update. *J Pediatr Orthop* 37 Suppl 2:S26–S31
  62. Saccomanno MF, Sircana G, Masci G, Cazzato G, Florio M, Capasso L, Passiatore M, Autore G, Maccauro G, Pola E (2019) Allergy in total knee replacement surgery: Is it a real problem? *World J Orthop* 10:63–70
  63. Saito H, Yonekura A, Saito K, Shimada Y, Yamamura T, Sato T, Nozaka K, Kijima H, Fujii M, Kawano T, Murata S, Miyakoshi N (2021) A new double level osteotomy procedure to restore a joint line and joint angles in severe varus osteoarthritis. - Double level osteotomy associated with tibial condylar valgus osteotomy (DLOTO). *Asia-Pac J Sports Med Arthrosc Rehabil Technol* 24:9–13
  64. Schröter S, Freude T, Kopp MM, Konstantinidis L, Döbele S, Stöckle U, Heerwaarden R van (2015) Smoking and Unstable Hinge Fractures Cause Delayed Gap Filling Irrespective of Early Weight Bearing After Open Wedge Osteotomy. *Arthroscopy Elsevier* 31:254–265
  65. Sikorski JM, Sikorska JZ (2011) Relative risk of different operations for medial compartment osteoarthritis of the knee. *Orthopedics* 34:e847-854
  66. So S-Y, Lee S-S, Jung EY, Kim JH, Wang JH (2020) Difference in joint line convergence angle between the supine and standing positions is the most important predictive factor of coronal correction error after medial opening wedge high tibial osteotomy. *Knee Surg Sports Traumatol Arthrosc Off J ESSKA* 28:1516–1525
  67. Spahn G, Kirschbaum S, Kahl E (2006) Factors that influence high tibial osteotomy results in patients with medial gonarthrosis: a score to predict the results. *Osteoarthritis Cartilage* 14:190–195
  68. Takagawa S, Kobayashi N, Yukizawa Y, Oishi T, Tsuji M, Inaba Y (2020) Preoperative soft tissue laxity around knee was associated with less accurate alignment correction after hybrid closed-wedge high tibial osteotomy. *Knee Surg Sports Traumatol Arthrosc Off J ESSKA* 28:3022–3030
  69. Tanaka T, Matsushita T, Miyaji N, Ibaraki K, Nishida K, Oka S, Araki D, Kanzaki N, Hoshino Y, Matsumoto T, Kuroda R (2019) Deterioration of patellofemoral cartilage status after medial





- open-wedge high tibial osteotomy. *Knee Surg Sports Traumatol Arthrosc Off J ESSKA* 27:1347–1354
70. Trieb K, Grohs J, Hanslik-Schnabel B, Stulnig T, Panotopoulos J, Wanivenhaus A (2006) Age predicts outcome of high-tibial osteotomy. *Knee Surg Sports Traumatol Arthrosc Off J ESSKA* 14:149–152
71. Trieb K, Grohs J, Hanslik-Schnabel B, Stulnig T, Panotopoulos J, Wanivenhaus A (2006) Age predicts outcome of high-tibial osteotomy. *Knee Surg Sports Traumatol Arthrosc* 14:149–152
72. Watanabe Y, Takenaka N, Kinugasa K, Teramoto T (2019) Intra- and Extra-Articular Deformity of Lower Limb: Tibial Condylar Valgus Osteotomy (TCVO) and Distal Tibial Oblique Osteotomy (DToo) for Reconstruction of Joint Congruency. *Adv Orthop* 2019:8605674
73. W-Dahl A, Robertsson O, Lohmander LS (2012) High tibial osteotomy in Sweden, 1998-2007: a population-based study of the use and rate of revision to knee arthroplasty. *Acta Orthop* 83:244–248
74. Wood MM, Warshaw EM (2015) Hypersensitivity reactions to titanium: diagnosis and management. *Dermat Contact Atopic Occup Drug* 26:7–25
75. Yazdanpanah O, Mobarakeh MK, Nakhaei M, Baneshi MR (2017) Comparison of Double and Single Leg Weight-Bearing Radiography in Determining Knee Alignment. *Arch Bone Jt Surg* 5:174–180
76. Yokoyama M, Nakamura Y, Onishi T, Hirano K, Doi M (2016) Healing period after open high tibial osteotomy and related factors: Can we really say that it is long? SpringerPlus Springer International Publishing 5:1–6
77. Yokoyama M, Nakamura Y, Onishi T, Hirano K, Doi M (2016) Healing period after open high tibial osteotomy and related factors: Can we really say that it is long? SpringerPlus 5:123
78. Yokoyama M, Nakamura Y, Onishi T, Hirano K, Doi M (2016) Healing period after open high tibial osteotomy and related factors: Can we really say that it is long? SpringerPlus 5:123
79. Yoon J-R, Ko S-N, Jung K-Y, Lee Y, Park J-O, Shin Y-S (2019) Risk of Revision Following Total Knee Arthroplasty or High Tibial Osteotomy: A Nationwide Propensity-Score-Matched Study. *J Bone Joint Surg Am* 101:771–778
80. Zhu J-W, Chen D-S, Wang T-F, Xie Y (2020) Patient Characteristics Related to Blood Loss in High Tibial Osteotomy in Novel Multiple Linear Regression Analysis. *BioMed Res Int* 2020:8965925
81. Ziegler R, Goebel L, Cucchiari M, Pape D, Madry H (2014) Effect of open wedge high tibial osteotomy on the lateral tibiofemoral compartment in sheep. Part II: standard and overcorrection do not cause articular cartilage degeneration. *Knee Surg Sports Traumatol Arthrosc Off J ESSKA* 22:1666–1677
82. Ziegler R, Goebel L, Seidel R, Cucchiari M, Pape D, Madry H (2015) Effect of open wedge high tibial osteotomy on the lateral tibiofemoral compartment in sheep. Part III: analysis of the microstructure of the subchondral bone and correlations with the articular cartilage and meniscus. *Knee Surg Sports Traumatol Arthrosc Off J ESSKA* 23:2704–2714
83. Australian Orthopaedic Association National Joint Replacement Registry. Annual Report. Adelaide:AOA; 2014 2014 .



## **Section 2 : PLANNING**

- 1) What is the ideal radiographic evaluation to facilitate osteotomy planning?
- 2) Which measurements should be included in the deformity analysis?
- 3) What are the normal values in lower-limb coronal alignment, femoral and tibial morphology?
- 4) Where does the deformity lie in varus arthritic knees?
- 5) Where should the weightbearing line be positioned to treat a knee with medial OA knee in varus malalignment?
- 6) Which knee joint line orientation is acceptable after planning an osteotomy?
- 7) When is a double level osteotomy (DLO) indicated to correct a varus malaligned knee?
- 8) How is ankle joint line orientation influenced by osteotomy?
- 9) When correcting a varus arthritic knee how is intra-articular deformity factored into the plan?

### **Abbreviations used in this document**

*CT – Computerised Tomography*

*JLCA – Joint Line Convergence Angle*

*MPTA – Medial Proximal Tibial Angle*

*MRI – Magnetic Resonance Imaging*

*mTFA – mechanical Tibio Femoral Angle*

*OA – Osteoarthritis*

*PLRI – Postero Lateral Rotatory Instability*

*TMA – Tibial Mechanical Angle*

*FMA – Femoral Mechanical Angle*

*TPI – Tibial Plafond Inclination; angle between a tangent through the tibial plafond and the horizontal.*

*KAJA – Angle between tangent lines to the articular surface of the proximal tibia (knee) and tibial plafond (ankle)*

## **1) What is the ideal radiographic evaluation to facilitate osteotomy planning?**

The gold standard for quantification of coronal alignment is the double leg stance long leg radiograph with the patient appropriately positioned with the limbs correctly rotated so as not to misrepresent coronal alignment.

### **Grade C**

Standard lateral knee view is a routine requirement. In addition, for sagittal plane deformity analysis and planning, whole length views of femur and/or tibia should be performed.

### **Grade D**

If torsional deformity is suspected clinically, axial plane planning CT scan slices at predefined heights are preferred.

### **Grade D**

#### **Literature review:**

Patients will have deformities which can occur in three planes. The majority of an osteotomy surgeon's work concerns coronal plane deformities. However, the sagittal and transverse planes also require radiographic assessment for completeness.

#### **Coronal Plane**

William MacEwan [106] [107] performed all of his osteotomies before the advent of radiographs. He would often perform osteotomies at multiple sites and then position the leg straight using splints. This concept of eyeballing to achieve a straight leg was practiced even up to the 1960s [81]. There is no doubt that Wilhelm Röntgens' invention of x-rays [59] was one of the most significant medical advances of the 19<sup>th</sup> century. Radiographs enable visualization of cortical outlines amongst soft tissue shadow and the morphology of the long bones can be seen and understood.

Proposed osteotomy lines were drawn upon the short knee views (*Figure 1*) obtained in the early modern era of osteotomy [162] when lateral closing wedge tibial osteotomy techniques [81] [33] were used to tackle medial arthritic varus. Zampogno [195] found only weak correlation with the mTFA measured on short knee views, compared to long leg measurements and so these authors recommend avoidance of pre-operative planning from short knee views reinforcing the conventional understanding that radiographs of the whole lower limb are required to plan accurate osteotomy surgery.

Harris [66] suggested using x-rays of the whole leg to quantify alignment. These were performed with the patient standing because the deformity may be under-interpreted in recumbent patients. Frank [53] described a standardized technique to take reproducible long leg radiographs (*Figure 2*). The beam is set 3.05 m from the patient, at the level of the knee joint. This ensures an equidistant trajectory from both the femur and tibia to reduce beam distortion. Any leg length discrepancy should be corrected with blocks under the shorter leg to level the pelvis [186]. The patient is encouraged to distribute weight evenly between each leg and keep the knees fully extended. For calibration a marker ball is suspended on a flexible arm between the knees at the joint level.

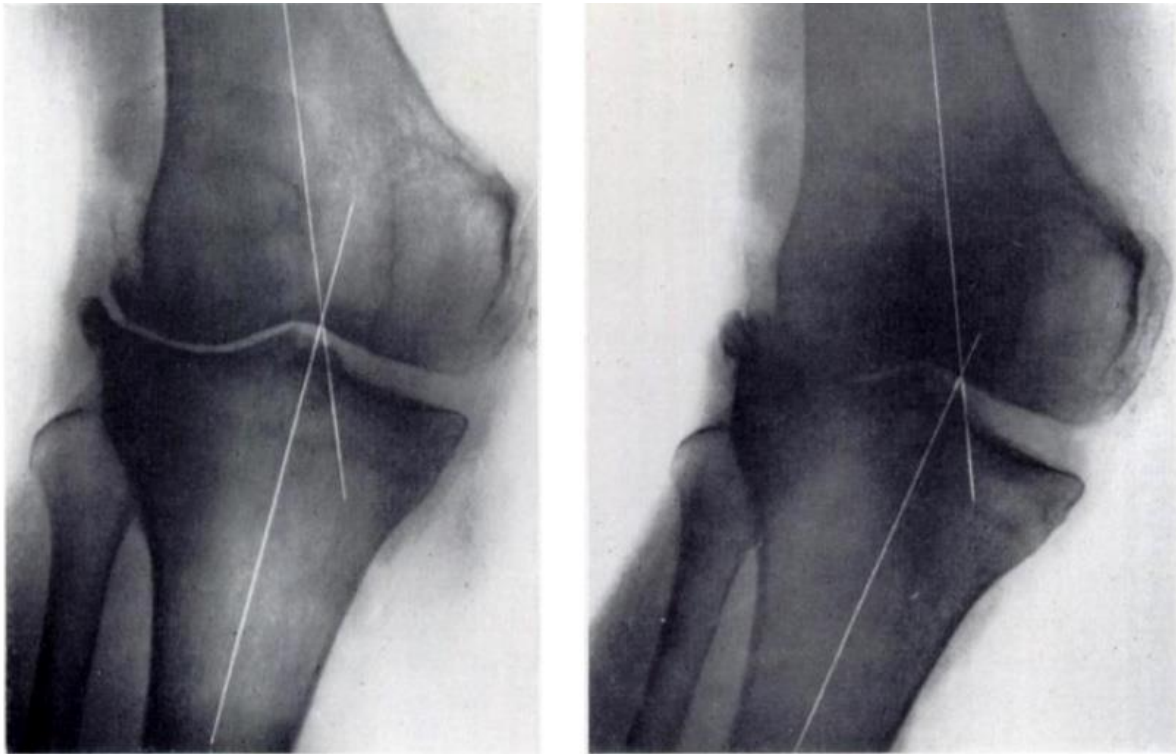


Figure 1: Short knee views only provide limited understanding of alignment and have been replaced with the conventional long leg alignment radiograph as the gold standard examination. Figure copied from [81]

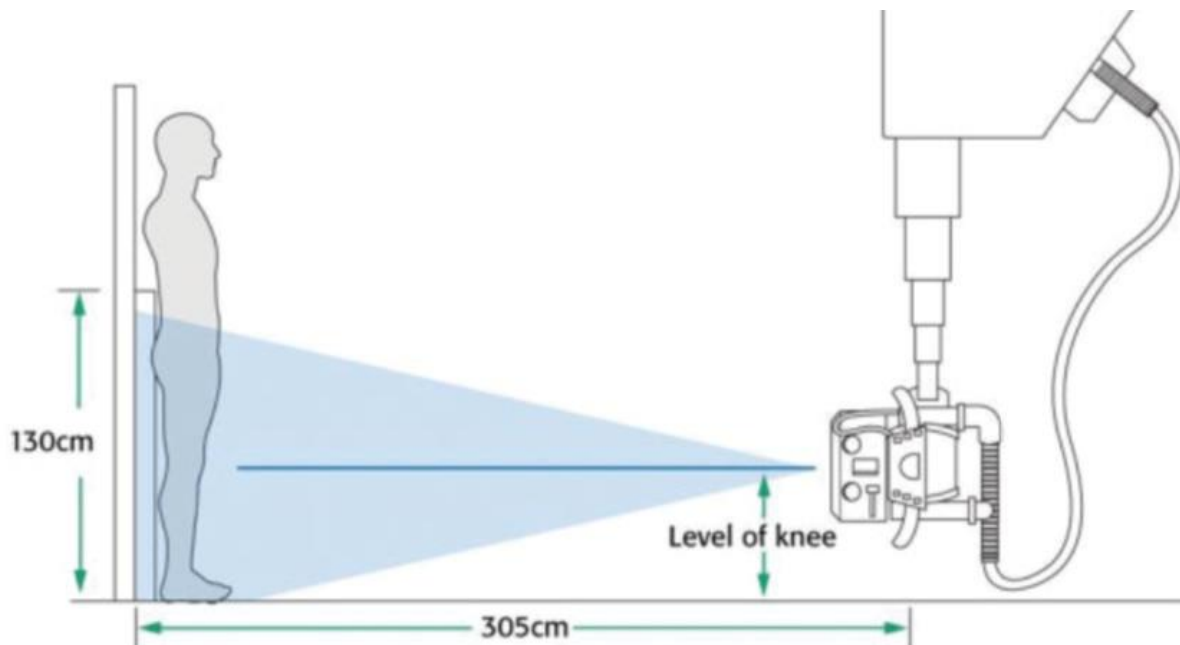


Figure 2: Performing long leg alignment radiographs as described by Frank in 1974 [53]

Radiographs obtained in this way should first be interpreted for appropriate rotation. The legs are rotated with the patella centred within the middle of the knee [32], accepting that this may not be

the natural foot progression angle for this patient. Recently, Ahrend et al [2] proposed a useful patella index (patella centre, relative to the femoral width at that level). The interpretation must be made with caution in cases of torsional deformity or chronic patella mal tracking. Well rotated films will have symmetrical outlines to the femoral condylar projections and the intercondylar notch [32] and typically superposition of one-third of the fibular head by the proximal tibia [150].

Specific features are observed in films obtained with the incorrect rotation [151]: In internally rotated films, the patella lies over the medial femoral condyle, the notch loses shape with divergent tibial spines, there is increased lateral femoral metaphyseal flare, and the fibula head is exposed. In externally rotated images, the patella lies over the lateral femoral condyle, the notch loses shape with convergent tibial spines, there is increased medial femoral metaphyseal flare, and the fibula head is excessively hidden. A method to assess rotation based upon overlap of the fibula head at the proximal tibiofibular joint [108] is useful if this needs quantification (figure 3).

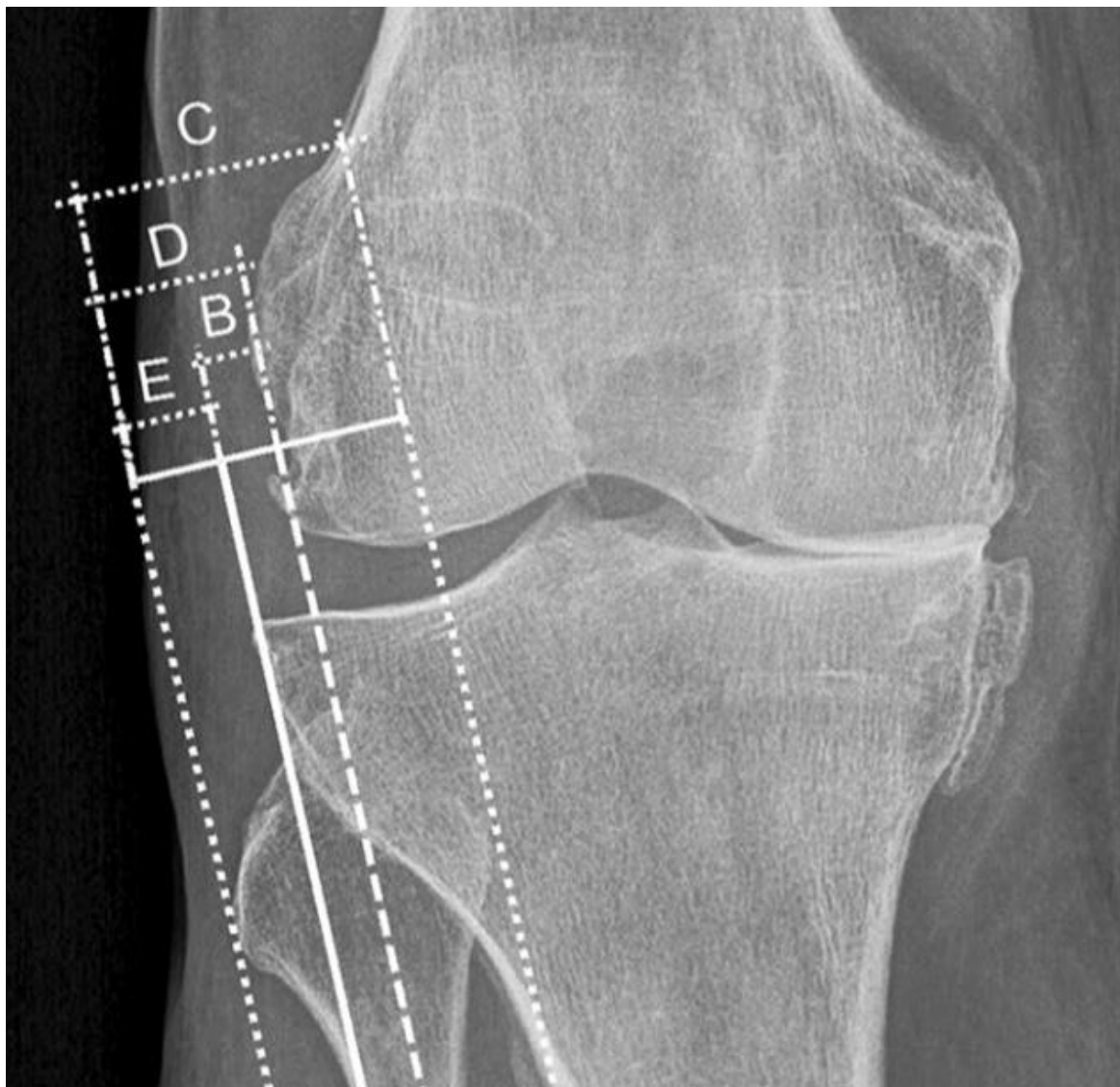


Figure 3: Maderbacher et al [108] describe a method to measure the amount of fibula overlap



A common-sense interpretation is necessary, aiming for radiographs with a near normal projection to the femoral condyles and tibial head, with superposition of one-third of the fibular head by the proximal tibia. Any surgeon who is dissatisfied with the radiographic rotation should be reminded that repetition of the long leg examination is far less harmful than execution of a poorly planned osteotomy.

There are alignment differences between long leg radiographs which are taken with the patient supine, double leg stance and single leg stance. This is unsurprising given that the transmitted load will increase as these weight bearing conditions progress. This is eloquently demonstrated by Na et al [127] where the difference between double and single leg stance is not significant in normal individuals, but is clinically and statistically significant in those with posterolateral rotatory instability (PLRI) and even more so in osteoarthritis (OA) (Figure 4)

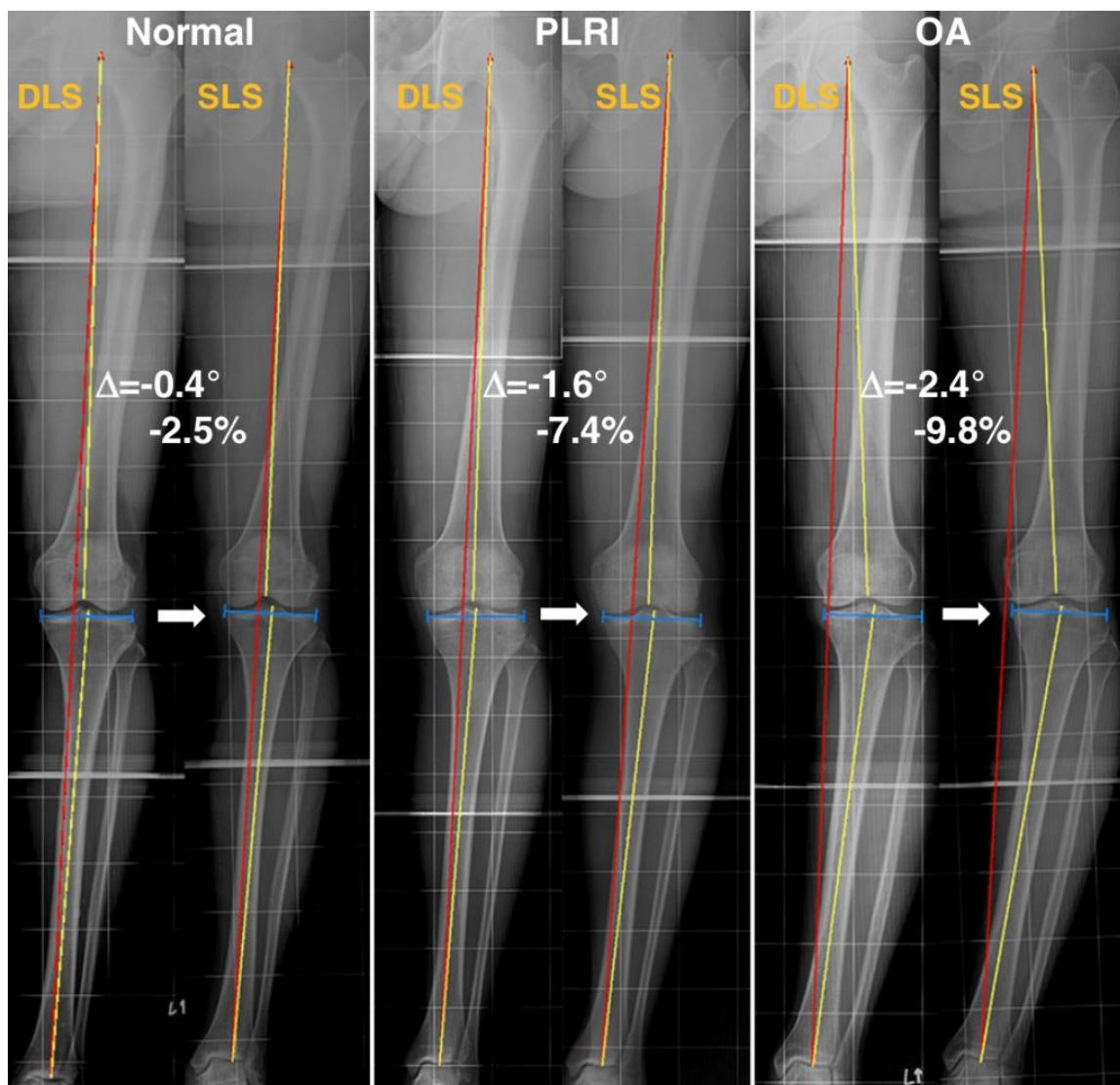


Figure 4: Alignment differences are accentuated between double and single leg stance in a group with PLRI and a group with OA. Figure copied from [127]



These authors suggest that the double leg stance radiograph is the gold standard for static planning, but the single leg stance radiograph gives insight into the dynamic loading of the limb. These changes have been observed by other authors [192] [13]. In Bardot et al [13] the transition from double to single leg stance resulted in an accentuated varus but also caused the joint line convergence angle (JLCA) to increase by a further  $0.8^\circ$ , in discussion the authors propose that this may be a simple method to establish the JLCA opening for each individual case which may be particularly useful in cases where the JLCA is noted to be high before surgery.

### **Sagittal plane**

The conventional radiograph to assess deformity at the knee in the lateral plane is the lateral x-ray of the whole tibia [151]. This should be assessed for rotation with a good true lateral view showing superimposition of the femoral condyles. The lateral view of the femur is of relevance where femoral flexion or extension deformity is suspected but this can be difficult to fit onto a single cassette in tall individuals and the proximal soft tissue bulk around the pelvis will often obscure views

### **Transverse plane**

In the infancy of computerised tomography (CT), it became possible to measure the bony contours of the tibia and femur by superimposing cuts from the hip, knee and ankle, with the leg position held static whilst in the scanner [69]. Simple geometric tools (*Figure 5*) are then used to measure torsion in the femur and tibia. There is some evidence that MRI used in the same way has comparable reliability



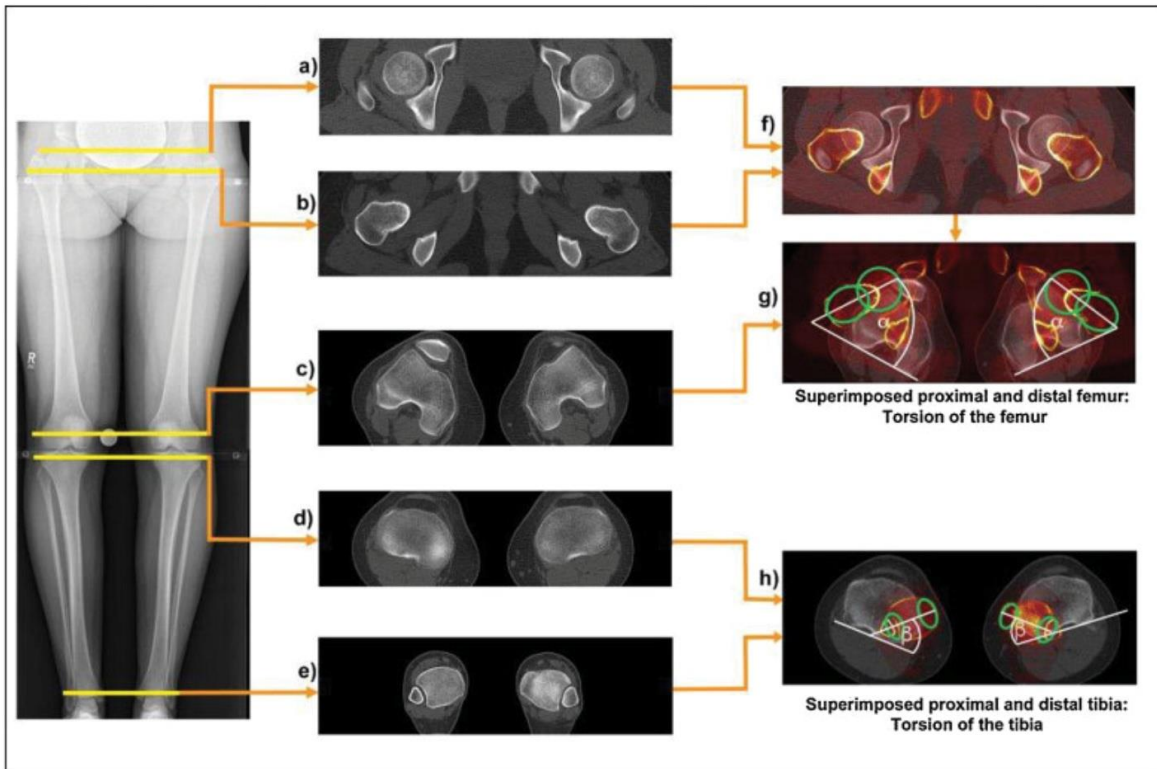


Figure 5: Rotational profile CT scan with explanation of the superimposed images used to measure long bone torsion (Included with author permission from [151])

## 2) Which measurements should be included in the deformity analysis?

A deformity analysis should precede the planning for correction of a coronal plane deformity and must include measurements of a weight bearing leg axis, periarticular angles, and joint line angles, preferably according to Paley et al

### Grade D

Sagittal plane (patella height and tibial slope) and axial plane deformity analysis of femur and tibia can be performed relative to normal values irrespective of the measurement system used for patella height and tibial slope.

### Grade D

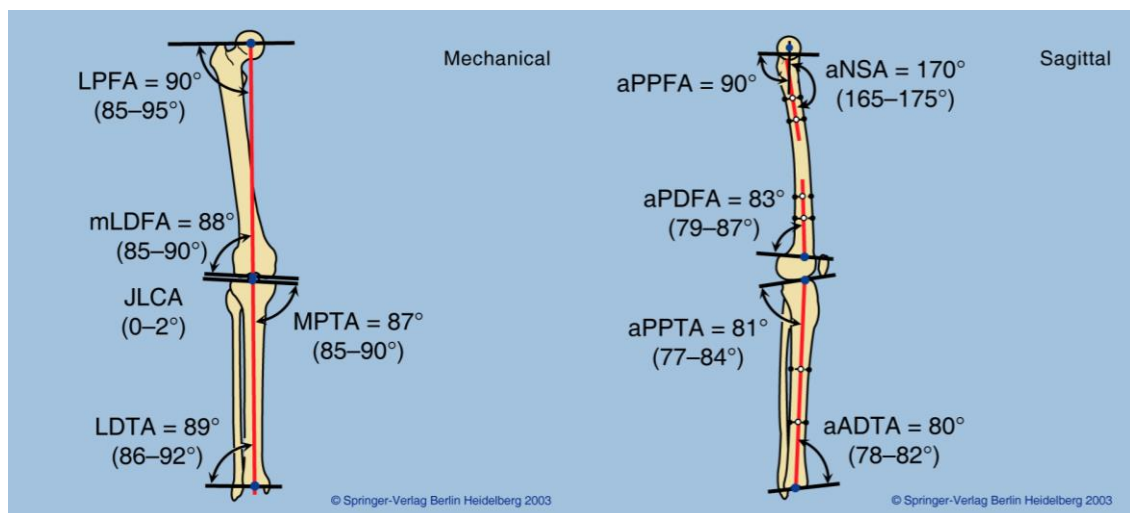


Figure 6: Mechanical alignment parameters in the coronal and sagittal planes. Conventionally described by Paley et al [136]

### Literature review:

Following on from the approach to question one; different parameters can be applied to imaging performed in coronal, sagittal and transverse planes. It is important to remember that planning has two main stages. An initial deformity analysis in order to identify the choice of osteotomy and the subsequent planning of this chosen osteotomy [151] [186]. It is also important to remember that an accurate measurement of joint line tangents should be made to avoid the pitfall of assuming that all varus is in the tibia and valgus is in the femur [186]

### Coronal Plane

Various different alignment parameters can easily be measured by the geometry between landmarks identified on long leg alignment radiographs. These are shown as mechanical values for the coronal plane (Figure 6) according to the description from Paley et al [136].

These are also identified in the table below which is not exhaustive, and this includes parameters which are commonly used in the literature:

Abbreviation	Name	Description	Normal Values	Reference
Mik %	Mikulicz point	Point where the weightbearing axis (plumb line from hip to ankle) transects a scale from the medial tibial margin (0%) to lateral tibial margin (100%)	35-55%.	[50]
MAD	Mechanical Axis Deviation	Perpendicular distance from the centre of the knee to the mechanical axis line (Femoral centre to ankle centre)	9.7 +/- 6.8mm	[136]
mTFA	Mechanical Tibio Femoral Angle	Acute angle between the mechanical axes of the femur and tibia	1° to 1.3° varus	[136]
HKA	Hip Knee Ankle	Obtuse or Reflex angle formed between femoral and tibial mechanical axes	Varus <180° (Obtuse) Valgus > 180° (Reflex) N = 172°	[70] [42]
MPTA	Medial Proximal Tibial Angle	Medial angle between tibial mechanical axis and tibial plateau tangent	87° (85° to 90°)	[136]
LDFA	Lateral Distal Femoral Angle	Lateral angle between mechanical femoral axis and femoral condylar tangent	88° (85° to 90°)	[136]
TBVA	Tibial Bone Varus Angle	Angle between tibial mechanical axis and the epiphyseal axis of the proximal tibia	2°-5°	[19]
JLCA	Joint Line Convergence Angle	Angle between the femoral condylar tangents and the tibial plateau tangents	0-2°	[136]

Paley [136] eloquently described his “**mal-alignment test**” with the following steps:

**Step 0:** Draw axis from the hip to the knee

**Step 1:** Femoral Mechanical axis against the femoral condylar tangent (LDFA)

**Step 2:** Tibial mechanical axis against the tibial plateau tangent (MPTA)

**Step 3:** Angle between the femoral condylar tangent and the tibial plateau tangent (JLCA)

**Step 4:** Mark the midpoint of the femur and tibia at the knee. If they do not line up this represents medial or lateral joint subluxation.

**Step 5:** Look for intra-articular malalignment sources with steps across the joint or angulation of the joint surfaces.

**Sagittal plane** (see fig 6)

These are also identified in the table below which is not exhaustive, the parameters included are commonly used in the literature:

Abbreviation	Name	Description	Normal Values	References
aPDFA	anatomical Posterior Distal Femoral Angle	Angle between the physeal scar on a lateral view and the anatomical axis of the distal femur	83° (79° to 87°)	[136]
aPPTA	anatomical Posterior Proximal Tibial Angle	Angle between the tibial joint line on a lateral view and the anatomical axis of the proximal tibia	81° (77° to 84°)	[136]

There are several commonly used methods for measuring tibial slope at the knee (*Figure 8*). Paley et al [136] uses a lateral X-ray of the whole tibia. The shaft axis is a line between halfway marks in the upper and lower tibial thirds. The posterior angle between the shaft axis and the tibial plateau tangent is called the posterior proximal tibia angle. Amendola et al [5] used the best shaft axis from a lateral knee view, and a perpendicular line to the shaft axis is drawn. The tibial slope is recorded as the angle between the shaft perpendicular and the tibial plateau tangent. Moore and Harvey [119] generates a tangent from the anterior tibial border on a lateral knee X-ray, and a perpendicular is drawn. The tibial slope is recorded as the angle between the anterior border perpendicular and the tibial plateau tangent. Brazier et al [20] generates a tangent from the posterior tibial border on a lateral knee X-ray, and a perpendicular is drawn. The tibial slope is recorded as the angle between the posterior border perpendicular and the tibial plateau tangent.

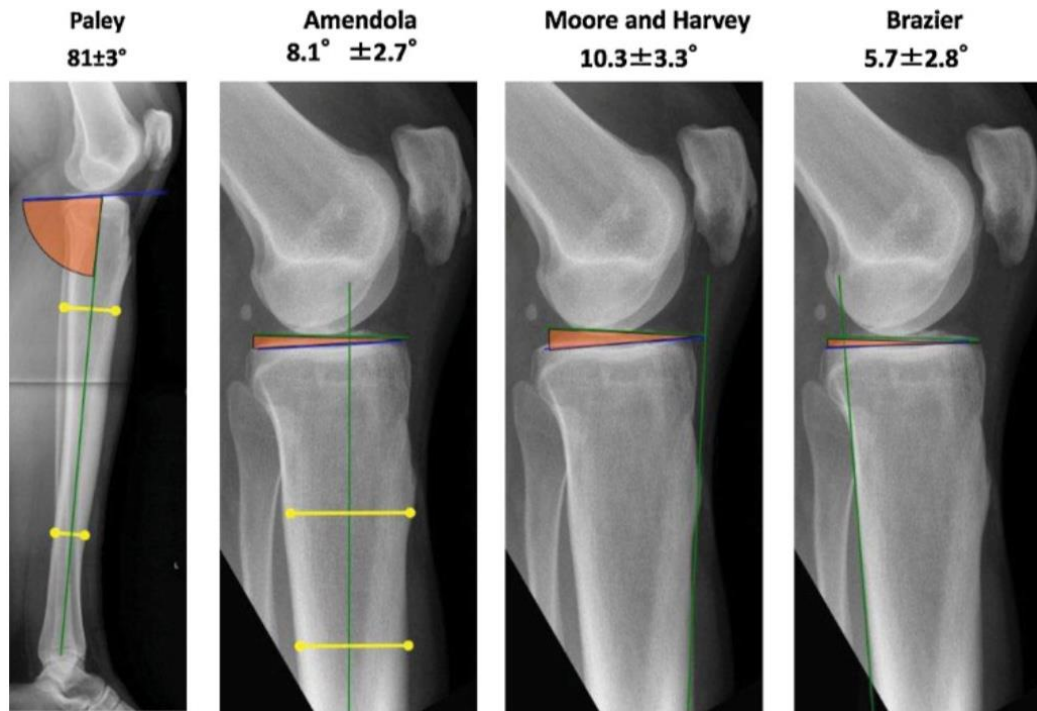


Figure 8: Different methods of measuring the tibial slope as described by Schroter et al [151]

### Transverse plane

The CT torsional profile is interpreted to give an angular value for torsion or twist within a long bone. The term rotation should be avoided because rotation can only occur between two separate bodies, the long bones are one unless separated by osteotomy at which point rotation can occur. Torsional angles are measured between the bony landmark trajectories made at the proximal and distal ends of superimposed long bone slices. Various parameters have been proposed such as the femoral neck torsion angle. The choice of the bony landmarks will influence the angle measured as is well summarised in Kaiser et al [85] (Figure 9). In the femur the distal angle is typically the tangent of the posterior femoral condyles but proximally different measurement methods have been proposed [194] [69] [116] [189] [125] [83] [100] [177]. [140] More recent research call upon oblique femoral neck slices to provide the whole femoral neck on one projection [193] [83] however this may not be practical in cases of coxa valga [151]. Zhang et al [196] use 3D modelling of the scans to measure femoral neck torsion angle (FNTA).

Regardless of the measurement method the values created need clinical context based on the clinical presentation and the values should be consistent with clinical examination findings. Understanding normal values is necessary to establish abnormal or pathological values. The method



proposed by Waidelich et al [189] in 1992 is fortunate to be backed up a large population-based cohort where the method was applied to more than 500 limbs [168] where mean internal torsion of the femur was  $24^{\circ} \pm 17^{\circ}$  and mean external torsion on the tibia was  $35^{\circ} \pm 16^{\circ}$ . Liodakis et al [102] found sufficient variation in the measurements recorded by different methods to preclude direct comparison. All the methods proposed above are achievable however a good working relationship between surgeon and radiologist is required to maintain consistency in measurement, interpretation and application to deformity correction

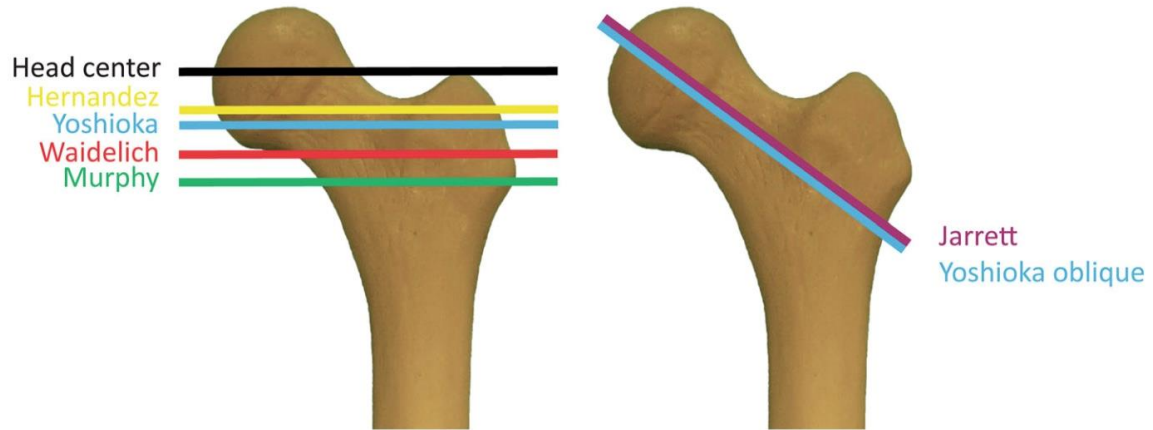


Figure 9: Different landmarks used to identify femoral torsion, illustration from Kaiser et al [85]



**3) What are the normal values in lower-limb coronal alignment, femoral and tibial morphology?**

Normal lower limb alignment and standard ranges can be defined according to Paley et al. <sup>21</sup> in the coronal plane. These normal values (table below) should be considered in the context of recognized ethnic and gender differences and clinical examination findings.

**Grade B**

mTFA	Mechanical Tibio Femoral Angle	Acute angle between the mechanical axes of the femur and tibia	1° to 1.3° varus
MPTA	Medial Proximal Tibial Angle	Medial angle between tibial mechanical axis and tibial plateau tangent	87° (85° to 90°)
LDFA	Lateral Distal Femoral Angle	Lateral angle between mechanical femoral axis and femoral condylar tangent	88° (85° to 90°)
JLCA	Joint Line Convergence Angle	Angle between the femoral condylar tangents and the tibial plateau tangents	0-2°

**Literature review:**

Again, following on from previous answers there are three planes to consider; coronal, sagittal, axial plane [151]

**Coronal plane**

At a very simple level normal lower limb alignment has been defined alongside the parameters used to measure it. Accordingly, Paley and his group, defined typical standard ranges for his stated alignment parameters [24]. Having a standard range for these alignment parameters is a useful concept because values out-with these normal ranges can then be recognised as deformity and considered in the context of clinical examination findings [186]. However, there was limited early work comparing the relationships between these alignment parameters and how this related to the lower limb as a whole.

Population studies were needed in order to define normality and its generalisability to clinical application. I describe the work from Bellemans et al [15] because it is familiar to the osteotomy community and I then go on to describe a systematic review of several population studies which is perhaps more detailed in answering the question on normal alignment.

**Bellemans et al**

Bellemans et al. studied coronal alignment in a population of 250 healthy young adults living in Belgium [15]. The group was half male and half female, comprising individuals aged 20 to 27. The measured HKA had a typical normal distribution with a mean of -1.3 (Varus) (Figure 10). Men were

more varus (1.9°) than women (0.8°) ( $p < 0.0001$ ). Men (Figure 11) were less likely to be neutral; with only 66% of the male knees within -3° to +3°, compared to 80% of the women (Figure 12) falling within this range. Constitutional varus was defined when HKA angle was -3° or less, and this occurred in 32% of men and 17% of women. Interestingly the researchers compared alignment to sporting activity during the second decade of life when physeal closure occurs. The greatest contributor to constitutional varus was MPTA ( $R^2 = 0.408$ ), followed by LDFA ( $R^2 = 0.294$ ) suggesting that this was mostly tibia varus but there was also a correlation with increased teenage sporting activity ( $R^2 = 0.081$ )

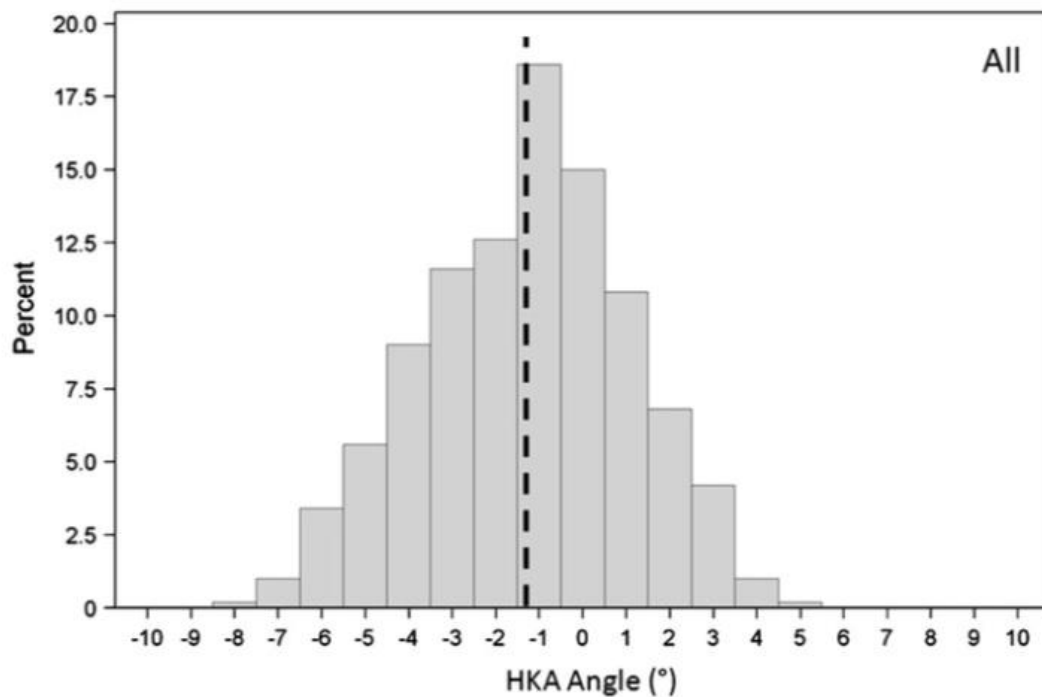


Figure 10: Histogram of the whole Study group from Bellemans et al [15] (n=250)

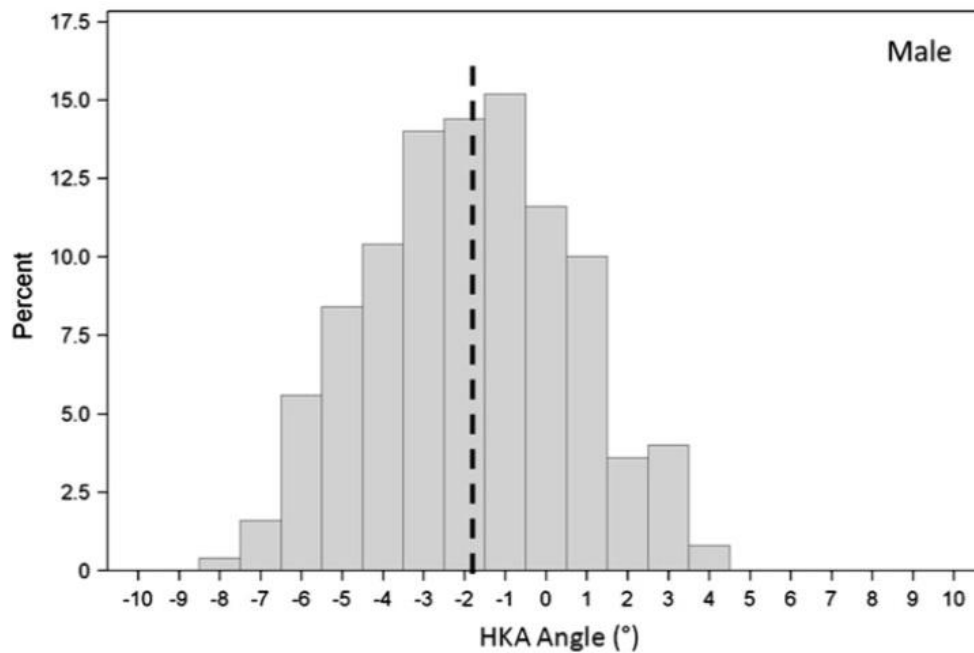


Figure 11: Histogram of the male subjects from Bellemans et al [15] (n=125)

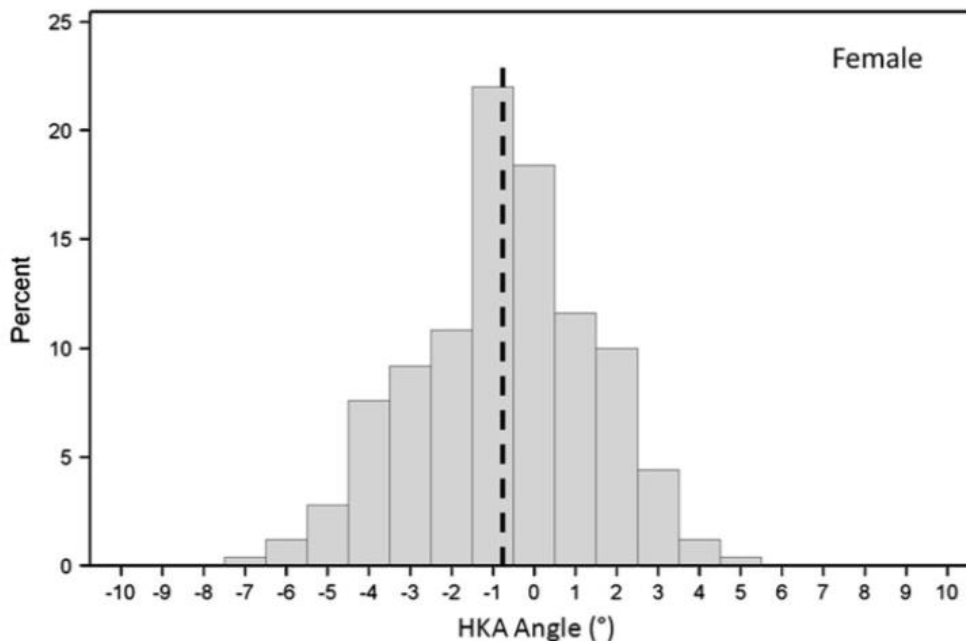


Figure 12: Histogram of the female subjects from Bellemans et al [15] (n=125)

**Moser et al [122]**

The systematic review of coronal alignment in native non-arthritic knees performed by Moser et al [122] in 2019, is highly relevant to answering this particular question. So, a substantial portion of this subsequent answer is based on this manuscript, due to its relevance to the normal variability of coronal knee alignment. This systematic review selected 15 studies for inclusion [170] [128] [79] [165] [157] [15] [89] [172] [29] [175] [73] [120] [111] [124] [74]. In the global community of 2021, it is worth noting that this systematic review has sampled human populations originating from several

different countries and races, which included, Hungary, China, India, Japan, Korea, North America, Pakistan, Iran and Belgium.

**Parameters used in this systematic review (Figure 13)**

This review utilises the parameter Femoral Mechanical Angle (FMA) on the medial side of the femur. The Paley defined lateral distal femoral angle (LDFA) can easily be calculated as  $LDFA^\circ = 180^\circ - FMA^\circ$ . This systematic review also reports Tibial Mechanical Angle (TMA) which is equivalent to the medial proximal tibial angle (MPTA)

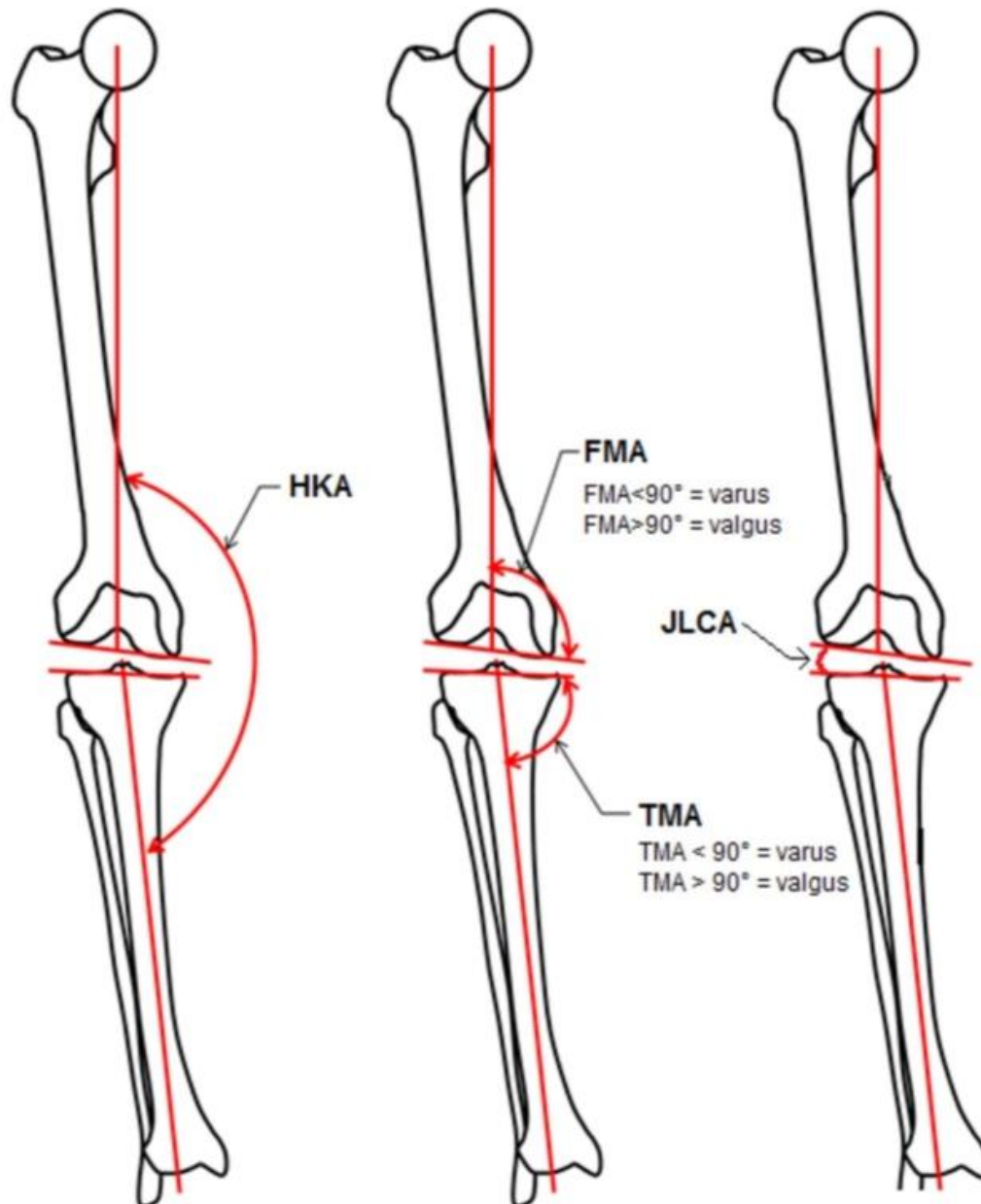


Figure 13: Joint tangents at the knee create the angles shown, diagram adapted from [122].  $TMA = MPTA$ ,  $LDFA = 180 - FMA$

**HKA**

14 of these studies reported mean HKA (*Figure 14*) with the most varus mean  $176.7^{\circ} \pm 2.8^{\circ}$  in males [111] and the most valgus HKA of  $180.7^{\circ}$  in females [175]. Only three of these studies reported the range of HKA with the widest range from  $167.7^{\circ}$  to  $183.8^{\circ}$  [158]. There are small differences in the reported mean HKA values which may reflect subtle changes in the morphology of the sampled populations. Equally the findings demonstrate gender distinction. 12 studies reported mean HKA for males from  $176.7^{\circ}$  to  $179.1^{\circ}$ . 10 studies reported mean HKA for females  $177.8^{\circ}$  to  $180.7^{\circ}$ . It is fair to conclude therefore that men have more varus knees than women.

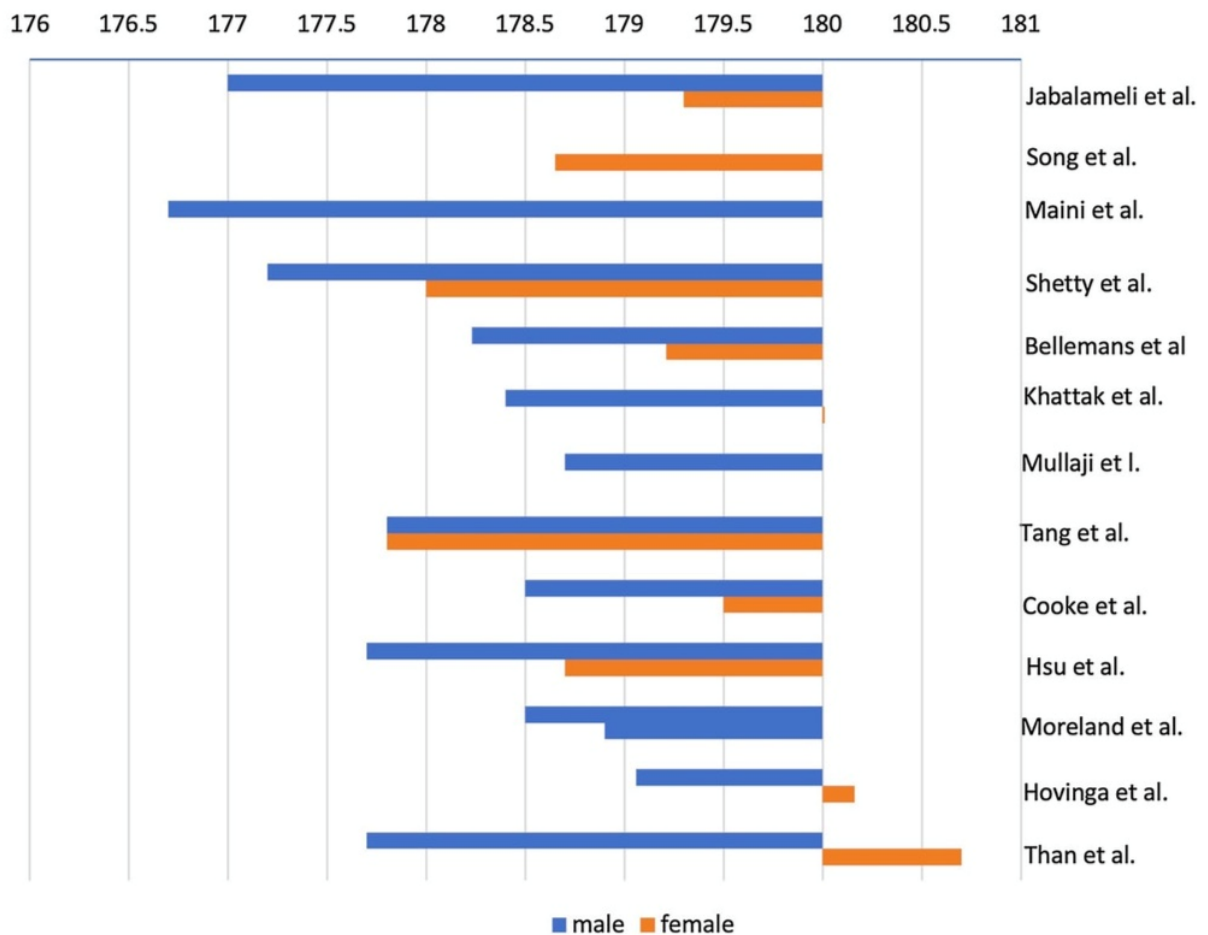


Figure 14: Mean HKA values reported by each study according to gender, figure from [122]

**Femoral Joint Line**

Five studies reported the FMA (*Figure 15*) from 92.1° [15] (LDFA 87.9°) to 97.2° [79] (LDFA 82.8°). This more marked femoral valgus was found in an Iranian population [79]

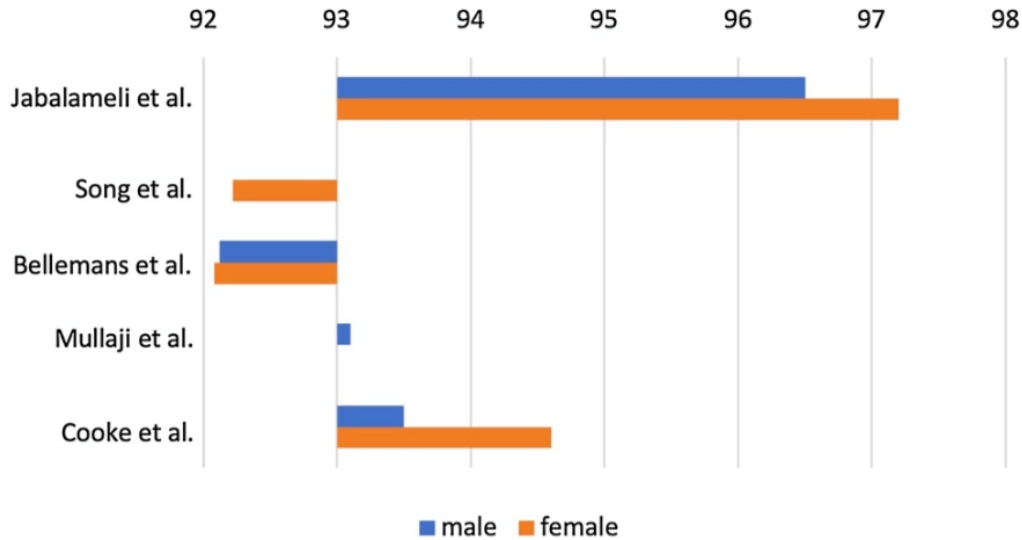


Figure 15: depicts the values reported for FMA according to gender, figure from [122]

**Tibial Joint Line**

Ten studies reported the TMA (equivalent to the MPTA) (*Figure 16*) with mean values ranging from 84.6° [172] to 89.6° [175]

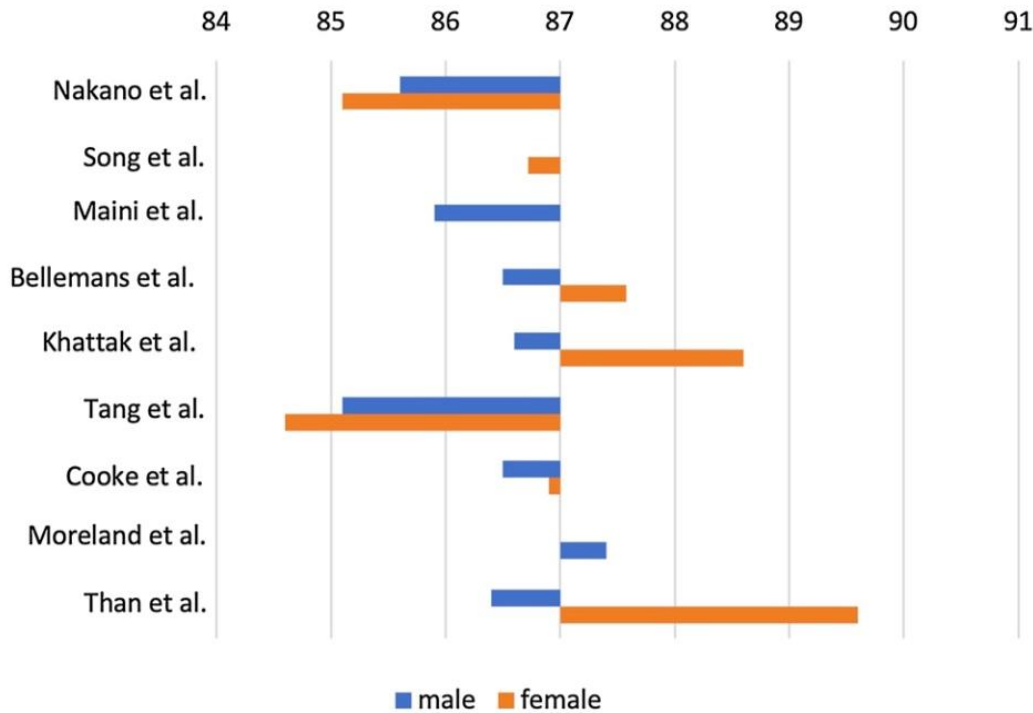


Figure 16: Depiction of the values reported for TMA according to gender, figure from [122].

**JLCA**

Four studies presented data on normal values for JLCA (figure 17) where all means were reported in the narrow range 0° to 2° the highest being 1.9° [30] and the lowest being 0.47° [15]

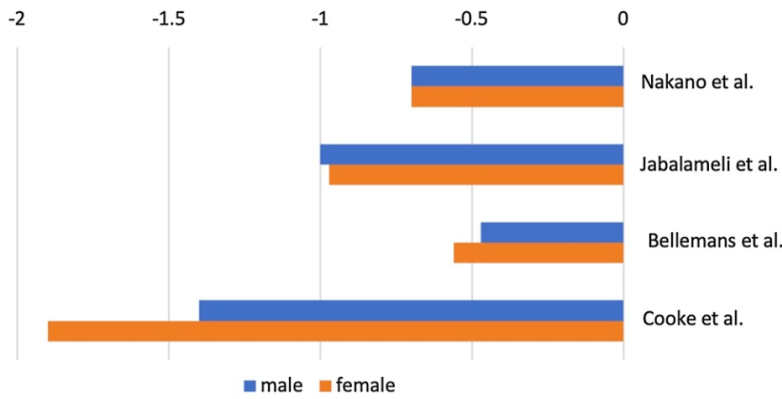


Figure 17: Depiction of the values reported for JLCA according to gender, figure from [122]

**Alignment phenotypes**

It has been suggestion that the model of varus / neutral / valgus coronal axis is an oversimplification [72]. Consideration of joint line obliquity to further stratify into recognised alignment phenotypes is a new concept [72]. There have been a few proposed schemes.

Hirschman et al proposed seven types (Figure 18) using the HKA as the secondary classifier at 3° intervals.

Coronal alignment				Average value
Limb phenotype (HKA)	VAR <sub>HKA</sub>	VAR <sub>HKA</sub> 9°	169.5°<HKA<172.5°	171°
		VAR <sub>HKA</sub> 6°	172.5°<HKA<175.5°	174°
		VAR <sub>HKA</sub> 3°	175.5°<HKA<178.5°	177°
	NEU <sub>HKA</sub>	NEU <sub>HKA</sub> 0°	178.5°<HKA<181.5°	180°
	VAL <sub>HKA</sub>	VAL <sub>HKA</sub> 3°	181.5°<HKA<184.5°	183°
		VAL <sub>HKA</sub> 6°	184.5°<HKA<187.5°	186°
		VAL <sub>HKA</sub> 9°	187.5°<HKA<190.5°	189°

Figure 18: Phenotypes categorised by Hirschman [72]

In a different phenotype proposal, Lin et al [101] considers the long bones as either varus, neutral or valgus depending upon their tangent at the knee and slits into the five alignment phenotypes observed in a Taiwanese population (Figure 19).



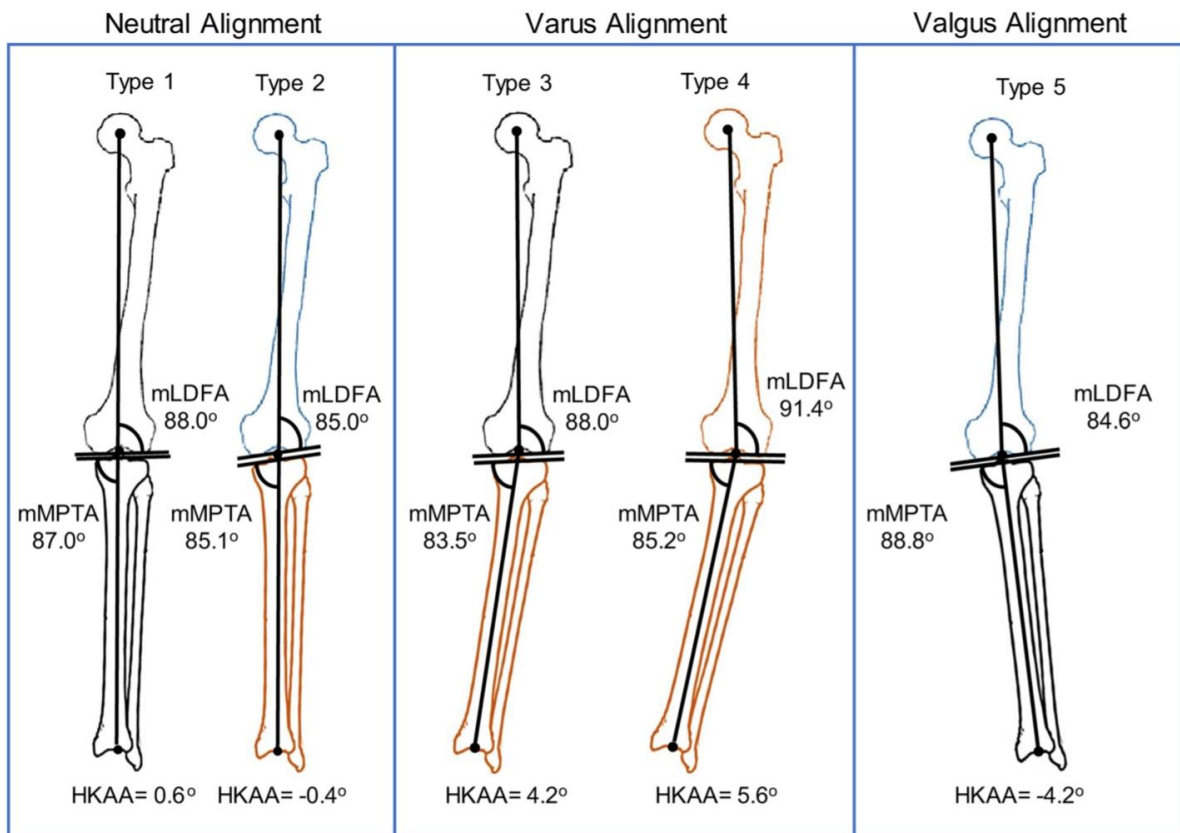


Figure 19: The 5 alignment phenotypes described by Lin et al [101]. Notice the bone is coloured black if considered neutral, brown if varus and blue of valgus.

Alternatively, MacDessi et al [105] created a grid where joint line obliquity is considered as apex distal, neutral or apex proximal and plotted against HKA as varus, neutral or valgus (Figure 20). This forms the basis of the coronal plane alignment of the knee (CPAK) classification, which is a comprehensive way to consider alignment phenotypes, accepting that some phenotypes are more frequently observed (Figure 21). For example, type I and I (apex distal joint line obliquity with either varus or neutral legs) makes up 65% of the studied population.

### Transverse plane

The method proposed by Waidelich et al [189] in 1992 is fortunate to be backed up a large population-based cohort where the method was applied to more than 500 limbs [168] where mean internal torsion of the femur was 24° +/- 17° and mean external torsion on the tibia was 35° +/- 16° [151]

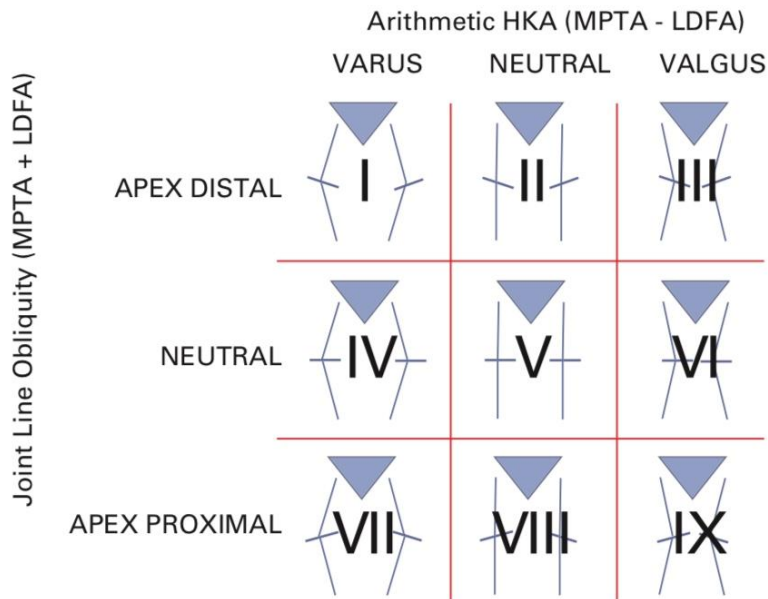


Figure 20: Coronal Plane Alignment of the knee (CPAK) classification proposed by MacDessi et al [105]

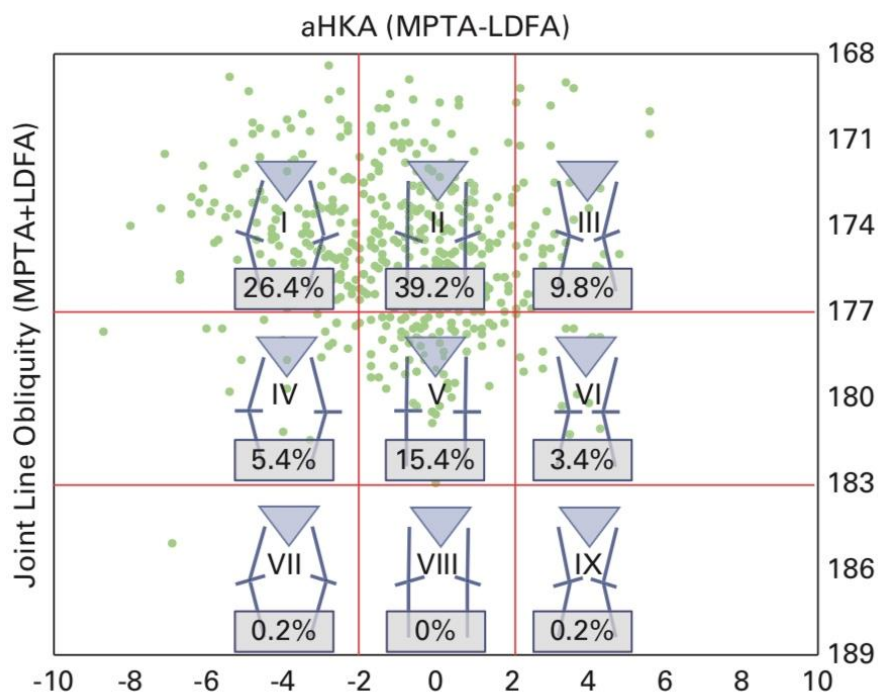


Figure 21: CPAK classifier [105] with green points plotted to show distribution of phenotypes in a healthy population (n=500)

#### 4) Where does the deformity lie in varus arthritic knees?

A deformity analysis will show in which bone(s) the varus leg alignment is located. If the periarticular bone angles measured do not (fully) account for the leg deformity, then an additional ligament laxity or intraarticular deformity may be contributing to the varus malalignment.

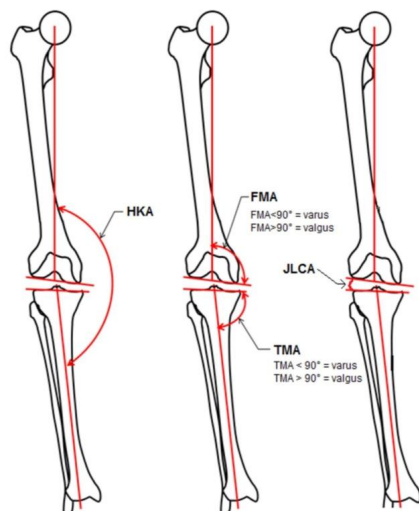
#### **Grade B**

#### **Literature review:**

The systematic review of coronal alignment in native but arthritic knees performed by Hess et al [71] in 2019, is highly relevant to answering this particular question. The paper is formatted in a similar manner to the systematic review of normal knees described in question 3, however this time focussing on patient populations with knee arthritis. A portion of this subsequent answer is based on this manuscript, due to its relevance to this topic. This systematic review again selected 15 studies for inclusion; [12] [28] [31] [38] [80] [93] [104] [123] [139] [143] [156] [175] [176] [190] [197]

Again, this systematic review has sampled human populations originating from several different continents and races, which included China, Canada, Saudi Arabia, Scotland, Iran, USA, Belgium, France, Hungary, Australia, South Africa, North America, Europe

Again, this review utilises the parameter Femoral Mechanical Angle (FMA) on the medial side of the femur (*Figure 22*). The Paley defined lateral distal femoral angle (LDFA) can easily be calculated as  $LDFA^\circ = 180^\circ - FMA^\circ$ . This systematic review also reports Tibial Mechanical Angle (TMA) which is equivalent to the medial proximal tibial angle (MPTA)



*Figure 22: Joint tangents at the knee create the angles shown. TMA = MPTA  
LDFA = 180 – FMA. Diagram from [71]*

#### HKA

13 of these studies reported mean HKA ranging from 163.5° +/- 2.3° [80] to 179.9° +/- 4.8° [156] (*Figure 23*). The widest reported range from 22° varus to 21° valgus [104] but this was matched by comparable within study ranges; 15° varus to 22° valgus [139], 18.1° varus to 21.6° valgus [143]. 5

studies reported gender specific mean HKA (*Figure 24*). The lowest reported value was  $-26.7^{\circ}$  varus [197] and the highest was  $+22^{\circ}$  valgus [139]. It would seem that the variation in OA patients is enormous. The mean overall HKA values were all less than  $180^{\circ}$ . 2 studies with HKA less than  $170^{\circ}$  studied middle Eastern populations which may be skewed by patient selection. Arabic patients may be more reluctant to undergo surgery and so they wait longer until presentation and have greater deformity as a consequence.

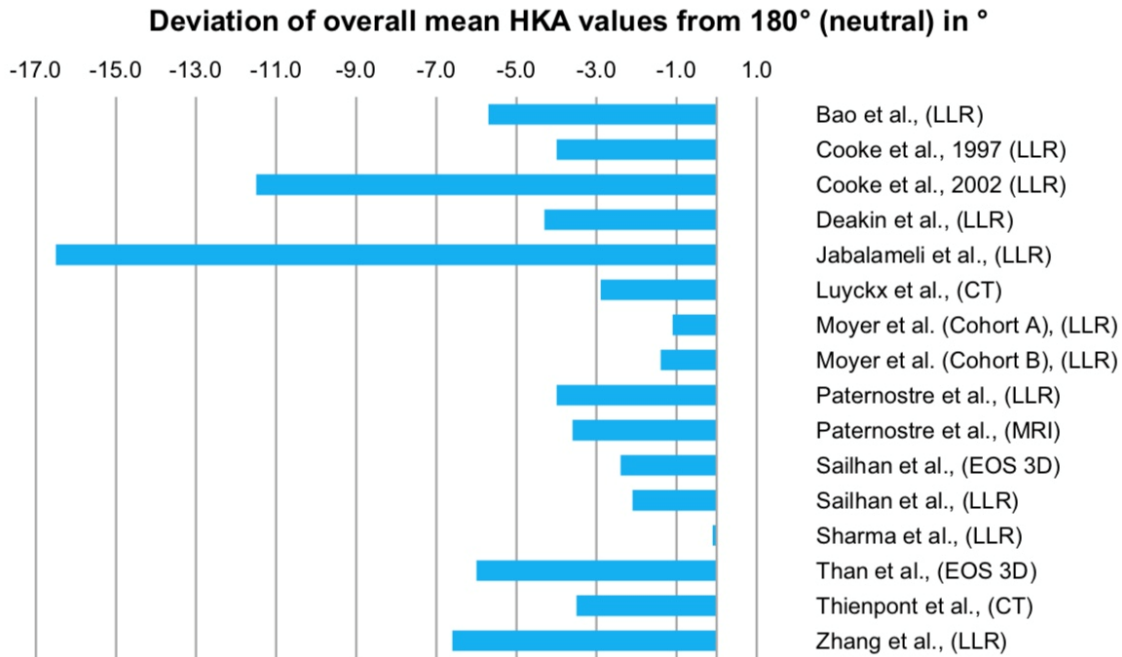


Figure 23. Deviation of Mean HKA from neutral in the studies included in this systematic review [71]

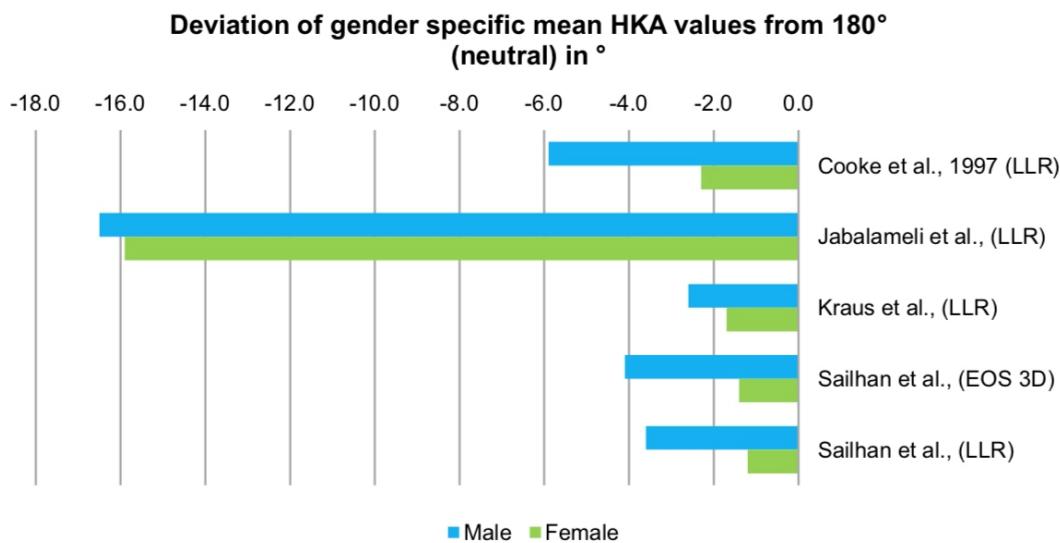


Figure 24: Gender specific values for HKA in the studies included in this systematic review [71]

**Femoral angle**

Mean values for Femoral Mechanical Angle (FMA) ranged from 88.6° (LDFA=91.4°) [80] to 92.7° (LDFA=87.3°) [176]. The widest reported range in a single study was 99.4° valgus to 87° varus [197]. This is shown graphically in Figure 25.

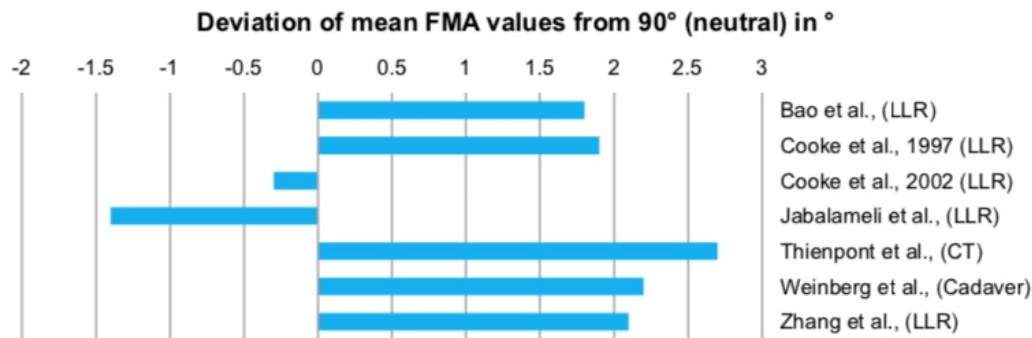


Figure 25: Femoral mechanical angle values in the studies included in systematic review [71]

### Tibial mechanical angle

Given that TMA = MPTA. Mean MPTA values ranged from 81.7° [80] to 87.8° [31]. See figure 26

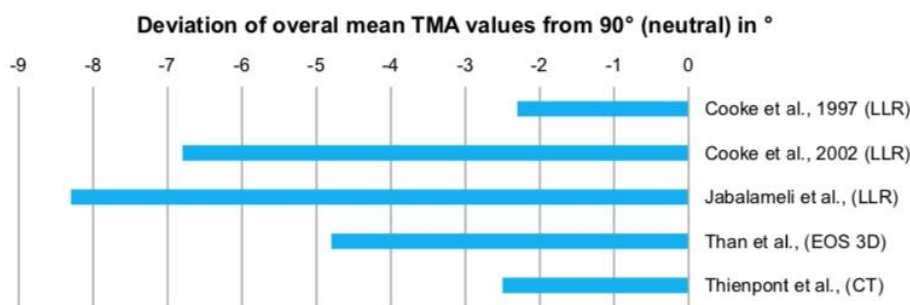


Figure 26: Reported TMA which is equivalent to MPTA in the studies included in systematic review [71]

### Joint line convergence angle (JLCA)

Only three studies reported JLCA in OA patients. Cooke et al reported JLCA -3.5° +/- 4° for Canadian patients and -4.3° for Arabic patients. Jabalameli reported overall mean JLCA of -6.4° (males - 5.6° and females -7.1°)

### What phenotypes are seen in arthritic knees ?

The distribution of an arthritic population is shown on the CPAK classification grid in Figure 27 below

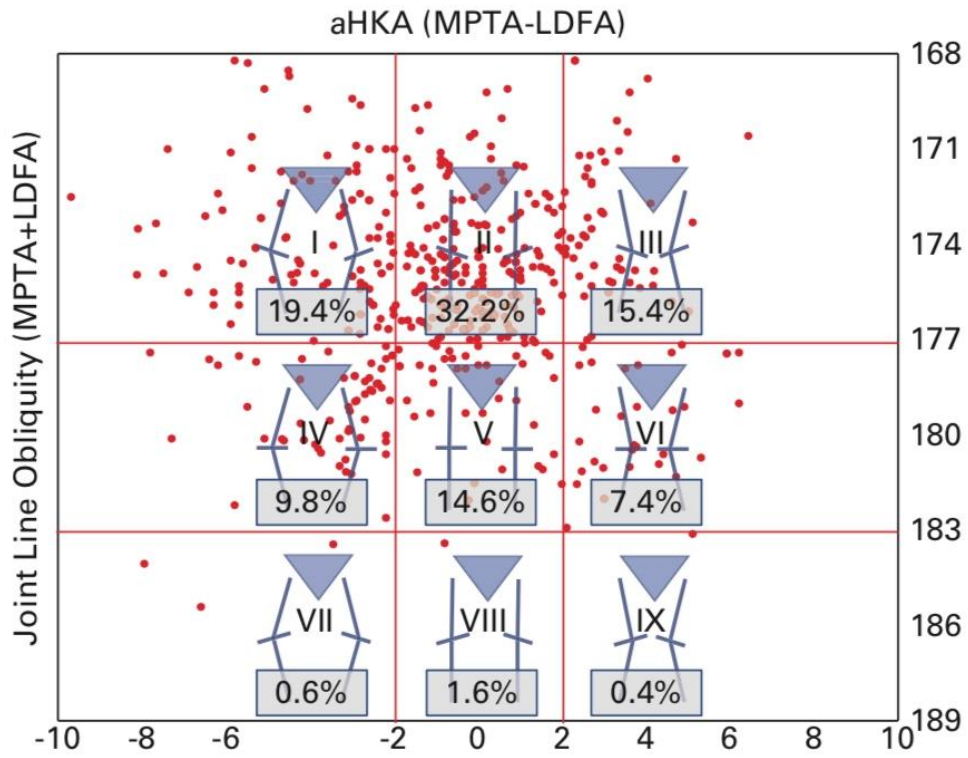


Figure 27: CPAK classifier [105] with red points plotted to show distribution of phenotypes in an osteoarthritic population (n=500)



**5) Where should the weightbearing line be positioned to treat a knee with medial OA knee in varus malalignment?**

An individualized approach is recommended which recognises that each patient has differing characteristics which include degree of deformity, radiographic osteoarthritis severity and indication for osteotomy surgery.

No specific target point can be recommended but based on historic results target ranges of between 50% and 68% have been proposed and may be implemented depending on patient specificity and degree of OA . In the light of the more recent evidence relating to joint line obliquity the consensus group would aim at the lower range of correction (see the following statement)

**Grade D**

**Literature review:**

The aim of lower limb osteotomy surgery around the knee is to correct the coronal weight bearing axis. To do this the surgeon needs a “surgical target” or “intended correction” which is typically defined by the surgeon based on several different factors. However, our evolving understanding of the “best” intended correction has always been controversial and this remains the case to date.

History has observed that the achievable accuracy in osteotomy surgery has been dependent upon the technology of the times. Prior to the advent of x-rays William MacEwan <sup>1</sup> [107] would aim for a **straight leg** as judged by his eyes prior to splinting of the osteotomized lower limb. This was still the case up to the 1960s where Jackson and Waugh [81] stated that “the aim was to **make the leg look straight**” prior to casting and wedging.

Greater understanding of lower limb deformity came with routine use of the long leg alignment view [66] [53]. Harris et al [66] point out that “dead reckoning” with the “opposite leg concealed under the drapes” would often lead to “embarrassing” over or under corrections. He proposed a really simple planning technique by calculating the wedge angle equal to an intersection angle between the weight bearing axis and the tibial mechanical axis (*Figure 28*). In theory this brought the weight bearing axis back to the “**centre of the knee**” which was the stated intended correction in his paper.

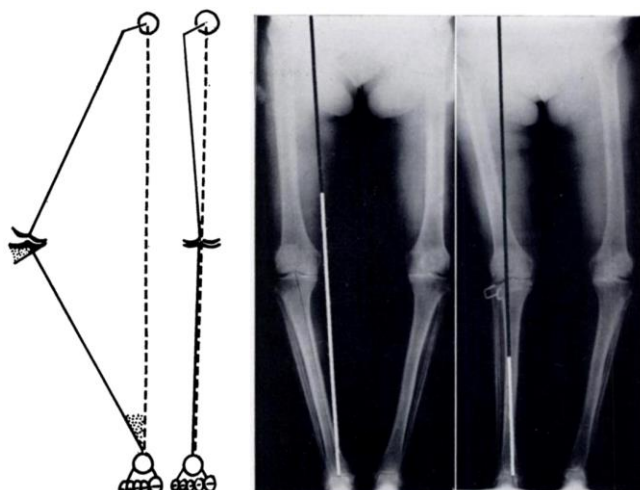


Figure 28: Extracted from Harris 1970 [66] showing his planning technique

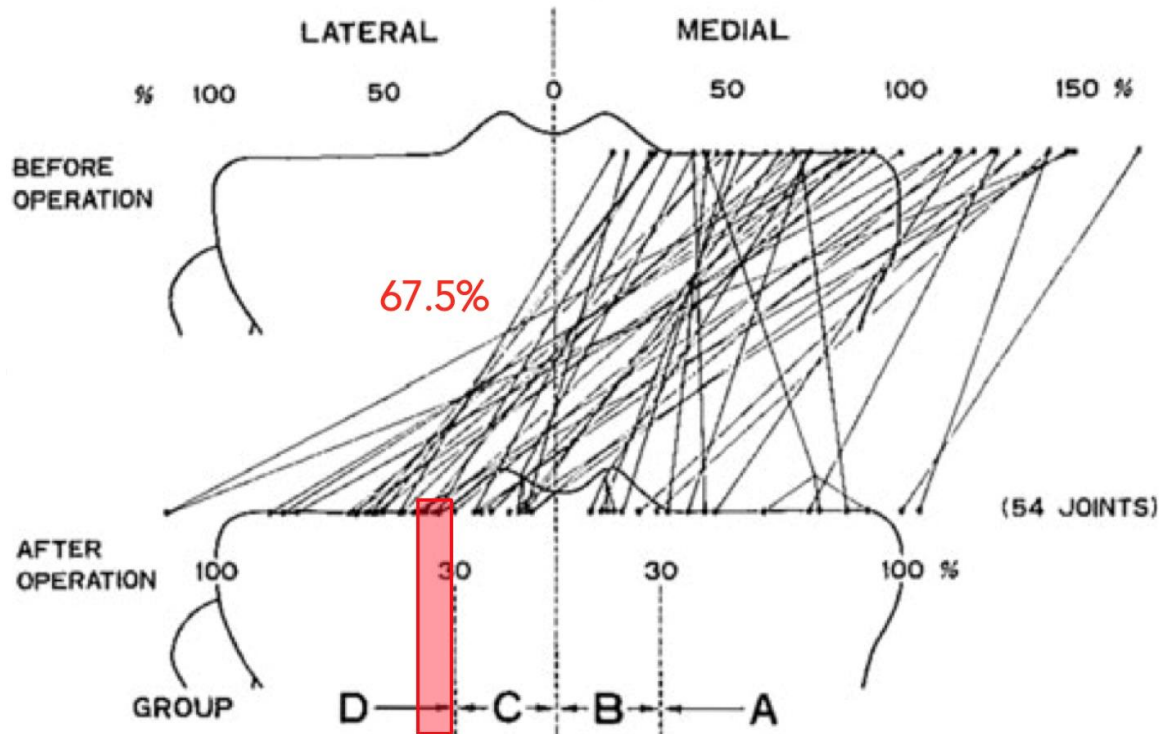


Figure 29: Extracted from the 1979 Fujisawa thesis [54], where the highest proportion of improved cartilage changes were observed in group D.

This confusion probably arises from the discussion in Dugdale and Noyes [40] where 62.5% was selected as halfway in a broad target area between neutral (50%) and the theoretical “medial lift off” at 75%, which was deemed to lead to excessive lateral overloading. Dugdale makes a review of the literature from the early modern years [162] and he includes these papers [33] [14] [66] [34] [82] [178] [75] [161] [65] [88] [35] [54] [112] [51] [183] [87] [1] [76] [70] whilst noting that although authors disagree on the optimal intended correction (Figure 30) they seem to agree that some overcorrection is necessary.

	NonFull- Length AP	Full- Length AP	Varus or Valgus Stress Views	Desired Postoperative Alignment in Femorotibial Angle	Desired Postoperative Alignment in Mechanical Axis
Coventry 1965 <sup>5</sup>	+				
Bauer 1969 <sup>4</sup>	+			3°-16° valgus	
Harris 1970 <sup>16</sup>		+			Through center of joint
Coventry 1973 <sup>7</sup>	+			5° overcorrection	
Insall 1974 <sup>21</sup>	+			5°-10° valgus	
Jackson 1974 <sup>22</sup>	+			"Slight overcorrection"	
Slocum 1974 <sup>41</sup>	+				
Torgerson 1974 <sup>43</sup>	+			7°-8° overcorrection	
Harding 1976 <sup>14</sup>	+			0°-6° valgus	
Kettelkamp 1976 <sup>28</sup>	+		Varus + valgus	8°-11° valgus	
Coventry 1979 <sup>7</sup>	+		Varus + valgus	At least 7° valgus	
Fujisawa 1979 <sup>10</sup>		+			30%-40% lateral to midjoint
Maquet 1980 <sup>30</sup>		+		Variable overcorrection	
Engel 1981 <sup>9</sup>	+		Valgus	8° valgus	
Vainionpaa 1981 <sup>44</sup>	+			5°-15° valgus	
Keene 1983 <sup>25</sup>	+			5°-13° valgus	
Aglietti 1983 <sup>1</sup>	+			6°-10° valgus 5° overcorrection	
Insall 1984 <sup>20</sup>	+			5°-10° valgus	
Hernigou 1987 <sup>17</sup>		+	Varus + valgus		183°-186°

Figure 30. Intended corrections from the early modern years as summarized in Dugdale et al [40] (NB. the Reference codes in superscript by the named authors apply to the refence list in Dugdale's original manuscript and not this document)

Notable papers with some evidence for the proposed intended correction are Hernoigou's [70] series of 93 knees where corrections with HKA within 183° to 186° had fewer long-term symptoms. Odenbring et al's [132] series of 314 osteotomies showed a significantly higher revision rate where HKA >185°. Sprenger's survival analysis at 22 years [166] which was significantly improved by corrections achieved within 8° - 16° valgus (Figure 31)

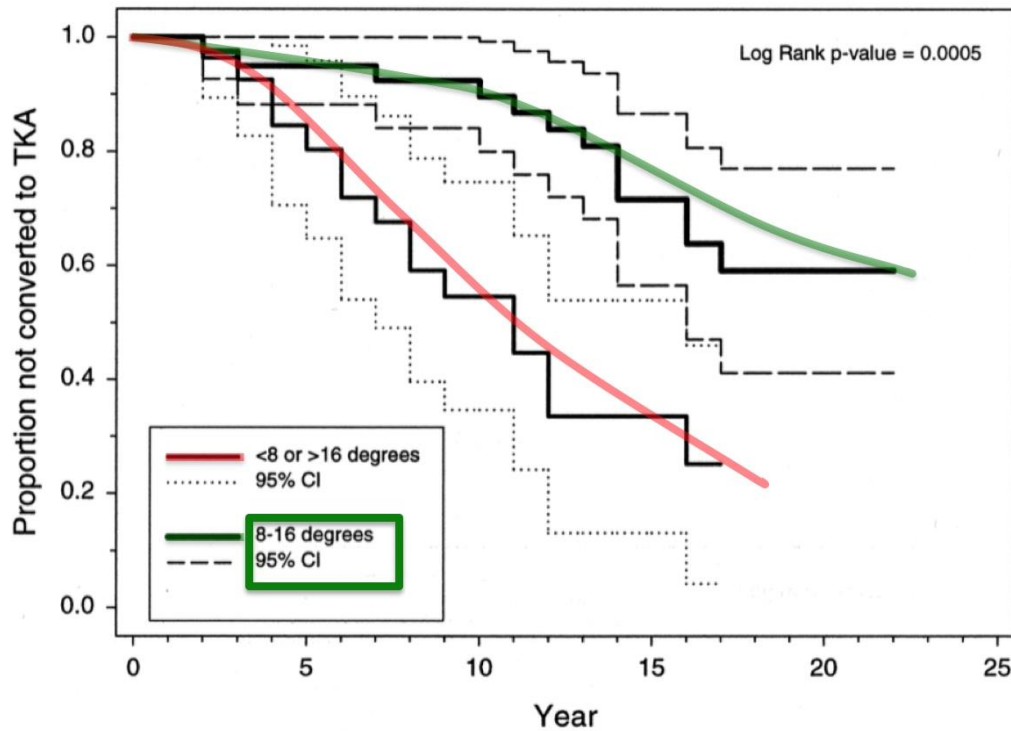


Figure 31: Sprenger [166] showed improved survival for corrections achieved within 8°-16° valgus [166]

Marti et al [113] suggested that the degree of arthritis should influence the intended correction, which would be taken further into valgus for worsening medial OA. The proposal was that arthroscopy should be performed to gauge the extent of arthritis and then modify the intended correction accordingly (Figure 32). This does conflict with a previous study [87] where arthroscopic findings prior to HTO had little predictive value in evaluating the suitability of patients for the subsequent osteotomy procedure

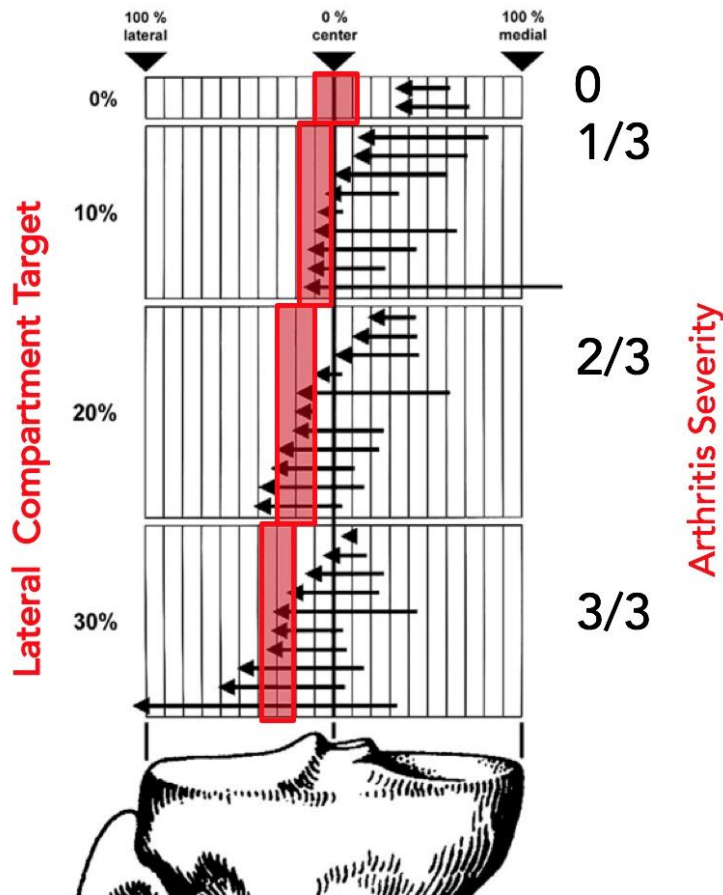


Figure 32: Marti et al [113] proposed that the intended correction should be more valgus for worse case of arthritis

This approach was modified by Müller [126] who suggested that this intended correction should be tempered by the difference between arthritic compartments, such that a correction only be taken further when the lateral compartment was healthy, and the correction be tempered when mild to moderate arthritis changes were seen laterally (Figure 33)

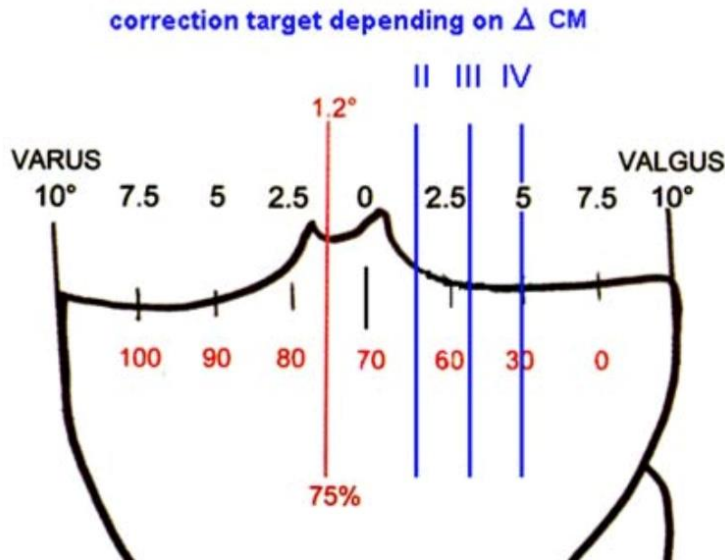


Figure 33: Müller [126] proposed considering the difference between compartments before adjusting the correction

Feucht et al [52] recognized that each patient has different characteristics, deformity, arthritis severity and indication for osteotomy surgery. They proposed an individualized approach where the indication for surgery is considered alongside the degree of deformity and arthritis (Figure 34)

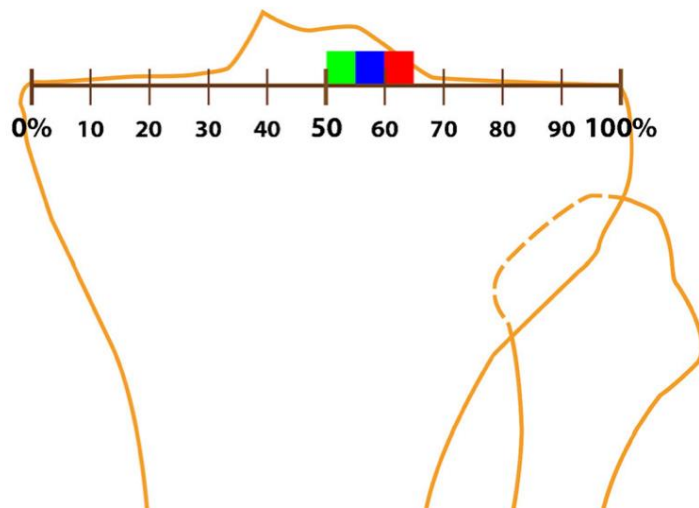


Figure 34: Three target zones proposed for valgus osteotomy by Feucht et al [52]. Indications for osteotomy (such as medial overload, cartilage repair, medial meniscal transplantation, ligamentous insufficiency) without any OA in the green zone 50-55%, mild OA to the blue zone 55-60% and moderate to severe OA is targeted at the red zone 60-65%.

Another systematic review of HTO accuracy [184] included 15 studies [63] [41] [10] [44] [21] [23] [57] [77] [98] [96] [97] [110] [148] [152] [167] There was a considerable overlap in the target ranges selected in these studies where 2°-3° of valgus was an area of consistent agreement for 11 of these selected studies (Figure 35) interestingly this is also the point where there is some evidence that the medial joint space may begin to open [67]



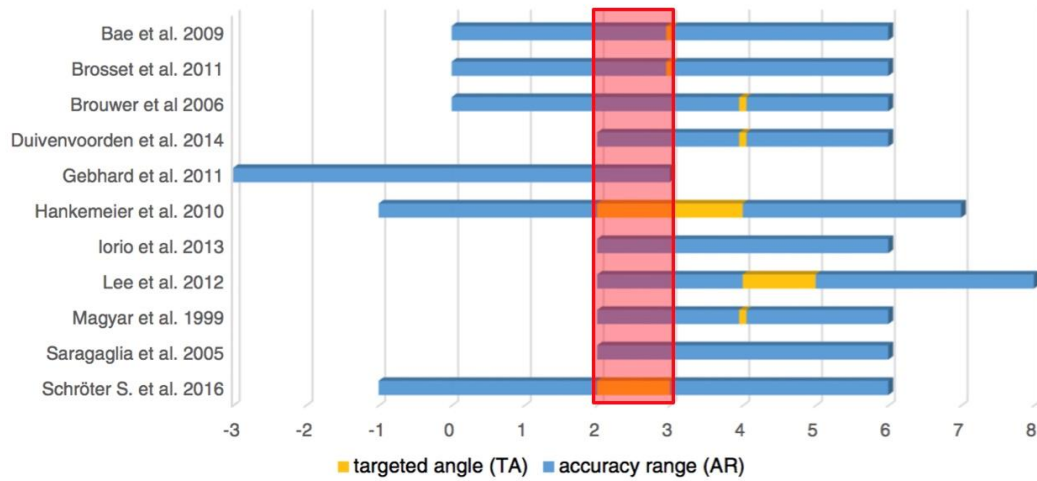


Figure 35. Target angles or ranges selected by 11 authors from this systematic review [184] where 2°-3° valgus appears to be a consistent area of crossover amongst authors

This target was not consistently met, which should be of concern to osteotomists. The target was missed more often with conventional methods than with computer navigation (Figure 36). Inevitably any system has inherent tolerances. In osteotomy surgery this has now been defined [45] with the term “surgical accuracy” with a simple formulae subtracting the achieved from the intended correction, or vice versa depending upon the osteotomy direction. The Gaussian distribution has been described for a cohort of 540 osteotomies from experienced surgeons with mean -1.5° (under-correction) and standard deviation 10.9% (Figure 37).

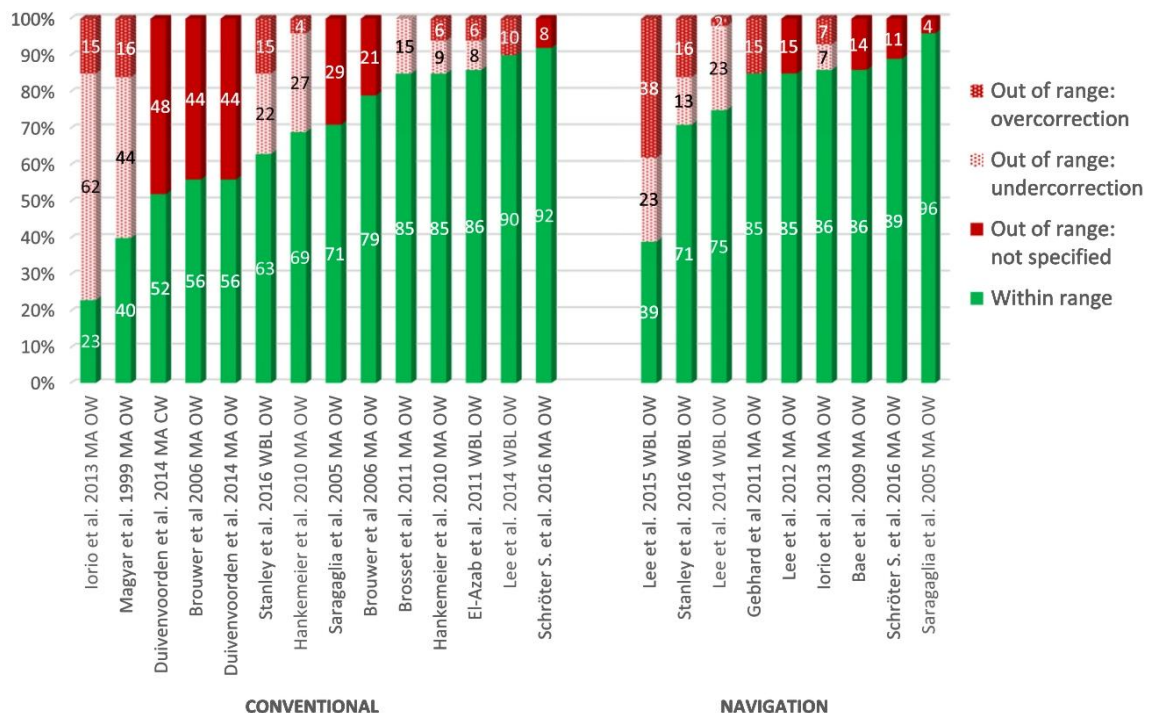


Figure 36: Reported success at achieving the target ranges between the different studies included in this systematic review [184]

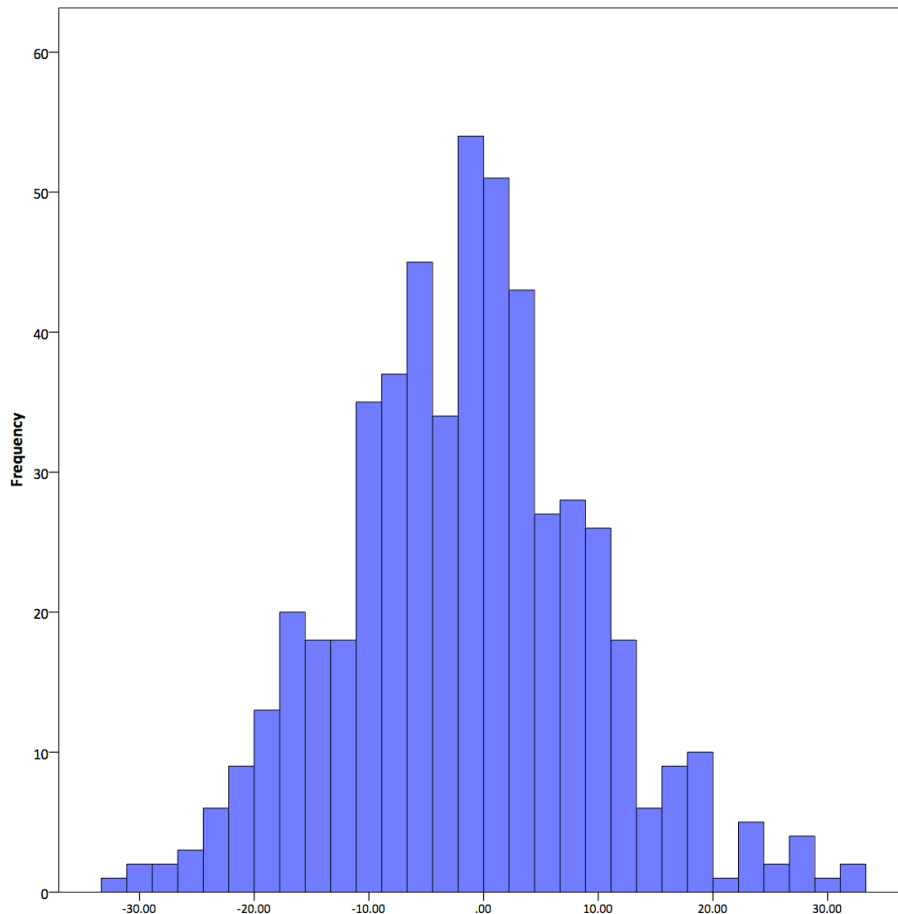


Figure 37. Normal Distribution of surgical accuracy in a cohort of 540 knee osteotomies from experienced surgeons [46]. Mean was 1.5% under correction and Standard Deviation of 10.9%

Recently, Tawy et al [173] have performed a systematic review to determine whether correction angle correlates with clinical outcome. The review was conducted according to the PRISMA statement and included 39 different studies [4] [7] [9] [17] [18] [22] [25] [27] [37] [37] [58] [43] [55] [61] [64] [78] [86] [90] [91] [103] [109] [114] [115] [182] [118] [121] [130] [131] [135] [142] [145] [149] [160] [171] [179] [187] [188] [191] [185] analyzing the results of 50 cohorts who underwent high Tibial Osteotomy. 15% of the studies were conducted as level II evidence (randomized controlled trials), 59% were level III (prospective cohorts) and remaining 25.6% were level IV studies (retrospective cohorts). The authors took the mean alignment changes for each study population together with any reported Proms to establish if linear correlation exists. Somewhat artificially the means reported from the 50 cohorts are then pooled to look for patterns. Correction of alignment and clinical outcomes are observed as shown in Table below:

Author (Year)	Surgical Approach	Fixation Type	Final Follow-Up (Months)	Preoperative Varus (deg)	Postoperative Valgus (deg)	VAS	OKS	EQ-5D
Altay (2016)	MOWHTO	Modular plate	75	4.7 <sup>b</sup>	8.4 <sup>b</sup>	53.7 > 14.1		
Asik (2006)	MOWHTO	Locking plate	34	5.7	6.5			
Bachhal (2011)	Hemicallostasis	External	63	10.6/4.9 <sup>b</sup>	4.0/9.2 <sup>b</sup>		20.6 > 39.8	
Birmingham (2009)	MOWHTO	Nonlocking plate	24	8.0	-0.05		43.0 > 19.1	
Birmingham (2017)	MOWHTO	Locking plate	60	8.0	0.3			
Brouwer (2006)	LCWHTO	Staple	12	6.8	3.4	59.0 > 36.0		
	MOWHTO	Locking plate	12	5.7	1.3	63.0 > 36.0		
Cho (2018)	MOWHTO	Unknown	72	5.1/1.5 <sup>b</sup>	1.2/6.8 <sup>b</sup>	51.0 > 24.0		
Choi (2017)	MOWHTO	Locking plate	12	4.1	4.3	56.0 > 41.0		
Da Cunha (2020)	MOWHTO	External	N/A	8.4	-1.3	11.8 > 0.0		
Duivenvoorden (2014)	LCWHTO	Staple	72	6.0	3.2	63.0 > 40.0		
	MOWHTO	Locking plate	72	5.0	1.3	60.0 > 34.0		
Eduardo Gelber (2015)	MOWHTO	Locking plate	31	9.2	2.1	79.0 > 21.0		
Ekeland (2017)	MOWHTO	Locking plate	99	1.1 <sup>b</sup>	6.2 <sup>b</sup>			
Gaasbeek (2010)	MOWHTO	Locking plate	12	4.3	3.8	66.0 > 25.0		
	LCWHTO	Locking plate	12	4.1	4.4	64.0 > 18.0		
Gouin (2010)	MOWHTO	Locking plate	24	5.2	1.9	56.0 > 22.0		
	MOWHTO	Locking plate	24	5.1	2.9	58.0 > 26.0		
Hantes (2018)	MOWHTO	Locking plate	124	5.8	2.3		20.4 > 34.2	
Ishimatsu (2019)	MOWHTO	Locking plate	96	6.7	5.7		29.1 > 41.3	
	HLCWHTO	Locking plate	96	9.9	3.3		28.8 > 43.8	
Kanto (2020)	MOWHTO	N/A	24	6.8	1.3			
Khurana (2015)	MOWHTO	External	11	7.2/2.4 <sup>b</sup>	1.7/8.0 <sup>b</sup>	65.0 > 3.0	43.3 > 16.9	
	MOWHTO	Locking plate	9	6.4/0.9 <sup>b</sup>	1.2/6.4 <sup>b</sup>	66.0 > 6.0	43.2 > 16.5	
Kim (2015)	MOWHTO	Locking plate	34	8.2	1.1	75.0 > 21.0		
	MOWHTO	Wedge plate	37	8.6	0.9	77.0 > 30.0		
Luites (2009)	MOWHTO	Locking plate	24	5.0	3.4	56.0 > 15.0		
	LCWHTO	Locking plate	24	6.8	0.9	59.0 > 23.0		
Maffulli (2013)	MOWHTO	Locking plate	42	9.1	3.1			56.4 > 73.6
	MOWHTO	Nonlocking plate	40	8.5	2.1			
McClelland (2016)	MOWHTO	External	72	8.6	-1.44	76.3 > 37.4		
McNamara (2014)	MOWHTO	Nonlocking plate	24	8.6	0.9			
Mhaskar (2020)	MOWHTO	Locking plate	24	4.1	1.1	57.9 > 10.0		
Mondanelli (2017)	MOWHTO	External	84	8.4/3.4 <sup>b</sup>	4.2/6.6 <sup>b</sup>			
Morin (2018)	MOWHTO	Anatomical plate	12	7.0	3.0	60.0 > 0.0		
Nerhus (2017)	MOWHTO	Locking plate	24	6.0	3.3		26.3 > 36.7	
	LCWHTO	Staple	24	6.2	2.0		25.7 > 37.4	
Nha (2019)	MOWHTO	Locking plate	24	6.9	2.7	77.0 > 25.0	20.0 > 38.7	
Ozel (2017)	MOWHTO	Locking plate	84	8.2	3.7	80.0 > 30.0		
Sadek (2016)	LCWHTO	Locking plate	35	7.0	3.6	75.0 > 16.0		
	LCWHTO	Locking plate	26	7.6	3.2	75.0 > 16.0		
Salzmann (2009)	MOWHTO	Locking plate	36	4.8 <sup>b</sup>	6.9 <sup>b</sup>	69.0 > 29.0		
Sawaguchi (2020)	MOWHTO	Locking plate	24	0.7 <sup>b</sup>	10.2 <sup>b</sup>		33.6 > 19.9	
Sischek (2014)	MOWHTO	Nonlocking plate	24	8.9	0.8			
Tang (2005)	LCWHTO	Staple	78	6.0 <sup>b</sup>	7.9 <sup>b</sup>	73.0 > 31.0		
Torres-Clarmunt (2018)	LCWHTO	Screws	12	7.8	0.6	68.0 > 25.0		
Van der Woude (2017)	MOWHTO	Locking plate	12	6.2	2.4	65.0 > 27.0		0.64 > 0.79
W-Dahl (2005)	Hemicallostasis	External	24	10.0	2.0			
W-Dahl (2009)	Hemicallostasis	External	12	10.0	4.0			
Whelton (2017)	MOWHTO	Locking plate	12	7.3	0.1		26.1 > 39.6	

The authors then specifically search for strong correlation with the available data from the 50 cohorts. This is found, such as strong correlation ( $r=0.62$ ) between HKA and the symptoms sub-domain of Knee Injury and Osteoarthritis Outcome Score (KOOS) [141]. This result suggests that greater valgus alignment is associated with better symptoms. However, conversely a moderate negative correlation ( $r=-0.50$ ) is identified for activity, sports and quality of life suggesting that greater valgus is associated with poorer scores for activity, sports and quality of life.

On face value, this just doesn't make sense and is difficult to interpret. Whilst the motivation for writing this systematic review is laudable, the paper itself may be limited by methodological flaws. Firstly, the pooled data is based upon the reported means for each cohort rather than raw data for individual cases and I would question the value of conclusions drawn from such indirect methods. Secondly using the Spearman's Rank method to identify statistical correlation, maps the data to a linear model and this may not represent the truth if we consider the clinical context. If we assume that over or under-corrected cases on either side of an ideal target are less likely to clinically



improve then hypothetically the data is more likely to resemble a Gaussian distribution or hyperbola than a linear correlation.

The authors [173] assume a valgus “ideal alignment” target of 3° to 6° (derived from Dugdale et al [40]) but find that this is not achieved in the average patient cohort included in the review. In light of the clinical improvement universally observed they then conclude that the ideal correction may be more flexible than the 3° to 6° range.

It is possible that a large dataset of individual cases with robust patient outcomes to consider alongside reliable alignment data may eventually answer this question regarding the ideal intended correction. Whilst a UK national knee osteotomy registry with apparatus to collect this data has been established [47] [48] this analysis is yet to be published and statically may require a sizeable dataset exceeding 5000 cases to have the capability to definitively answer the question posed?

## **6) Which knee joint line orientation is acceptable after planning an osteotomy?**

The knee joint line orientation defined as the position of the knee joint tangent relative to the horizontal is known to be important to reduce shear forces in the knee. Joint line orientation reflects a challenging compromise between mechanical WBL modification and resulting tibial and femoral anatomical morphology.

Planning should therefore aim to target a resulting knee joint line orientation below or equal to 5° (mPTA <95)

### **Grade B**

#### **Literature review:**

Although Coventry et al. [36] reported that a JLO of 10° was acceptable, most modern studies quote an accepted upper limit of 4°. A JLO of 4° represents the mean post-operative JLO ± SD that has been observed across several studies, with authors then analyzing their clinical outcomes either side of this cut-off value. In a 3D finite element model analysis, Nakayama et al. [129] reported that a JLO ≥ 5° induced shear stress twice as high as a JLO < 5°, but they did not take into account compensatory changes that may occur at the hip and ankle joints. Babis et al. [8] tracked 29 double-level osteotomies and reported that knees with a JLO of ≤ 4° could achieve a high survival (96%) at 100 months, while Song et al. [164] followed 109 MOW HTO patients for a mean of 55 months and found a statistically (though not clinically) significant difference in Knee Society objective and functional scores with worse outcomes when JLO ≥ 4° and adverse radiological outcomes when JLO ≥ 6°. Conversely, Lee et al. [99] and Oh et al.<sup>167</sup> found no association between JLO and clinical outcomes. In Lee et al. [99] this study of 50 HTO patients against 75 healthy controls the relative KJLO changed significantly less than did the anatomical geometry of the proximal tibia.

Conflicting evidence also exists with regard to post-operative MPTA and no threshold at which over-correction can be tolerated has been clearly established. Akamatsu et al. [3] found that patients with > 95° MPTA had lower KOOS Sports & Rec function subscale scores than patients with an MPTA ≤ 95° (51.1 vs 69.5). Similarly, Schuster et al. [154] found that functional long-term outcomes decreased in knees with an MPTA > 95°, but up to 10 years, there was no difference in the rate of conversion to arthroplasty. Conversely, Goshima et al. [60] and Lee et al. [99] found no correlation between MPTA and clinical outcome.

Several retrospective studies report the mean change in JLO as being less than half the mean change in MPTA. Other authors have attempted to determine post-operative JLO on pre-operative templating. Oh et al. [134] found that pre-operative HKA and JLCA were significant predictors of a JLO ≥ 4° and they caution against introducing excess JLO in patients with severe pre-operative deformity or a large JLCA. Park et al. [138] aimed to devise an equation that predicts post-operative JLO and determined that a 1° increase in MPTA will increase JLO by 0.463°. Finally, Tseng et al. [180] measured numerous radiological parameters at the hip and knee joints and found that when the post-operative Knee Ankle Joint Angle (KAJA) was ≥ 10°, 68% of patients ended up with a JLO ≥ 5°. They recommend consideration of a double level osteotomy if templating indicates the KAJA will be ≥ 10°.

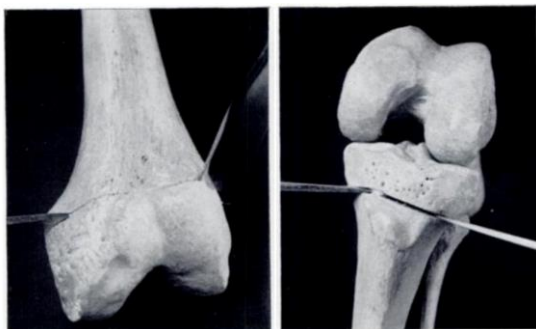
## **7) When is a double level osteotomy (DLO) indicated to correct a varus malaligned knee?**

A DLO correcting the varus malignment in both the femur and the tibia should be considered if deformity analysis identifies a significant deformity in both bones. DLO may also be considered if when planning a single level correction, the resultant knee joint line orientation exceeds 5° or MPTA exceeds 94

### **Grade C**

#### **Literature review:**

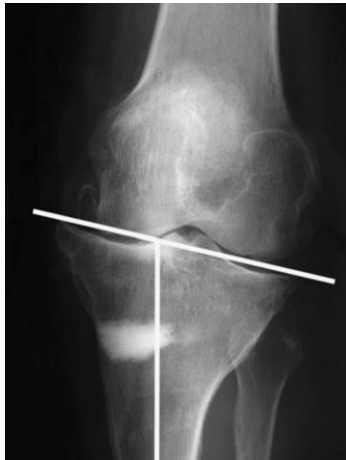The earliest report of double level osteotomy, as we know it today, appears to be from Alec Benjamin [16], an orthopaedic surgeon in the small market town of Berkhamsted in Hertfordshire England. His paper is laced with historical serendipity. Having observed success from high femoral osteotomy he thought that this was due to the division of various structures (blood vessels, nerves, bone) and their subsequent healing. He applied the same logic to the knee, observing that “the blood supply to the knee is similar above and below” and so double osteotomy was therefore offered to six patients who were waiting for knee arthrodesis. The early results were so encouraging that it was soon offered to more patients. The techniques were quite rudimentary (*Figure 38*), and any coronal or flexion deformity was corrected by manipulation into a straight plaster cast. Over 7 years 150 patients received this treatment and 57 of the earlier patients were evaluated. The paper is limited by the lack of validated PROMS due to its era, but it does report that satisfactory pain relief was frequently observed. Whilst of historical interest it does not really answer the primary question given that all these patients were offered double osteotomy in an era prior to reliable alignment quantification.



*Figure 38: Site of the two osteotomies performed through a medial arthrotomy in Benjamin [16]*

Alignment can now be quantified accurately on long leg x-rays. Small deformities can often be tackled with a single level osteotomy in the correct bone, but when the deformity is larger the single level approach may be insufficient and double level osteotomy may be required. Inevitably this surgery will take longer to perform and may carry increased risk from greater surgical exposure. So, what does the literature tell us about the threshold at which surgeons should employ double level osteotomy over single level procedures? (see example in *Figure 39*)





*Figure 39: An example of severe joint line obliquity following high tibial osteotomy as a single level procedure*

Shoji and Insall, examined varus osteotomies for valgus deformities and identified that excessive medial tilting leads to poor outcomes [159]. Mark Coventry [36] described how medial proximal tibial osteotomy with more oblique joint lines can create shear stresses on the tibia. He went on to propose a threshold for acceptable joint line obliquity  $<10^\circ$ , but it would seem that at best this was expert opinion (level V evidence). Terauchi [174] retrospectively examined alignment parameters in 37 HTO knees and identified that excessive obliquity prevents shift of weight bearing to the lateral compartment and may cause recurrent varus deformity after HTO. They reported improved results (HSS 88) from HTO with just tibial deformity compared to HTO where the deformity was on both tibia and femur (HSS 65,  $P < 0.01$ )

The seminal paper on the concept of double level osteotomy is the work of George Babis et al in 2002 from the Mayo clinic [8]. Here 29 double osteotomies (24 patients) were followed up on average 7 years after the index surgery. One of these double osteotomies was revised to TKR but the others maintained reasonable level of function at 82.7 months (range 27 to 137 months). This survival of 96% was considered excellent and the authors concluded that double osteotomy is indicated in cases with larger deformities where load transfer to the unaffected compartment cannot be achieved with an acceptable joint line obliquity. Double level osteotomy was considered when joint line obliquity exceeded  $0^\circ \pm 4^\circ$  (see Figure 40). Whilst it is not clearly stated in the paper, I think it reasonable to assume that the authors mean  $90^\circ$  to the tibial anatomical axis  $\pm 4^\circ$  which would be a simulated MPTA  $< 94^\circ$ . The authors complete this paper with the observation that “a large varus deformity (mean  $13.9^\circ$ ) coupled with a small joint-line obliquity appeared to be the common indication for use of a double level osteotomy to achieve the required biomechanical criteria for a successful treatment outcome.” This would make sense - a double is likely to be necessary when the varus deformity is large, but the tibial deformity is small; leaving limited surgical room to correct the osseous deformity in just the tibia alone. Therefore, an additional femoral osteotomy is needed to split the surgical correction without excessively altering the joint line obliquity. It is useful to have the criteria quantified and this may explain the reluctance of some surgeons to create an MPTA  $> 94^\circ$ . This is a retrospective review of a cohort so at best level IV evidence.



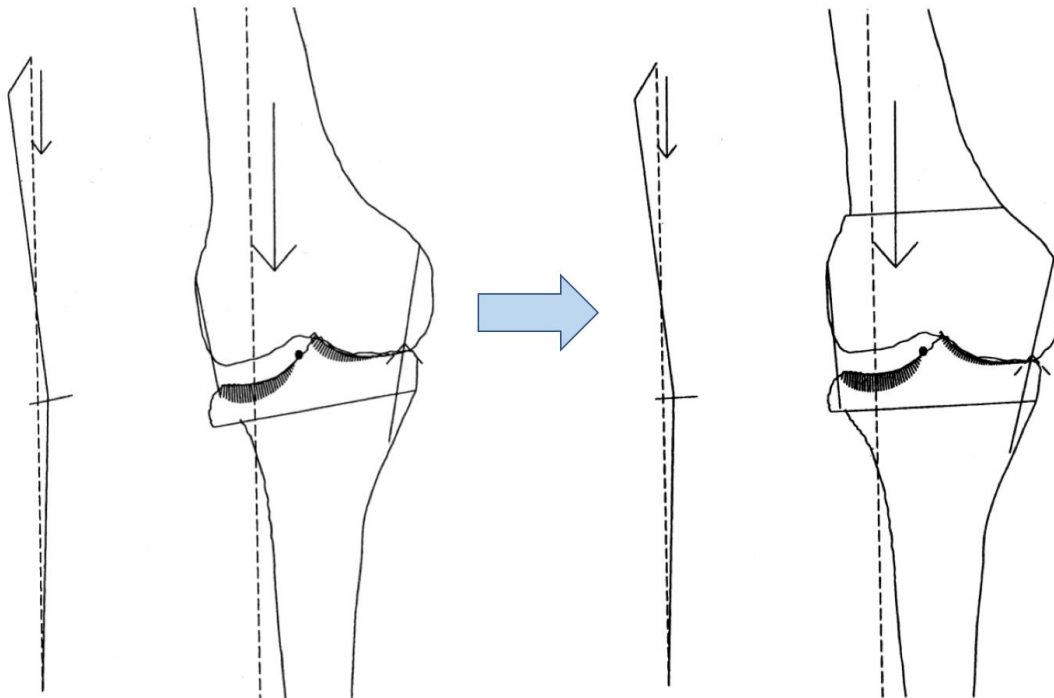


Figure 40: Babis et al [8] proposed double level osteotomy when a single level osteotomy created joint line obliquity greater than  $4^\circ$  (MPTA  $>94^\circ$ )

Seventeen years later, this work was repeated in a similar study from Schröter et al. [153] Again, this was a retrospective cohort of 24 patients (28 knees) followed up at only 18 months. The threshold for double level osteotomy was a simulated MPTA  $>93^\circ$ , where the mL DFA  $>90^\circ$ . The paper reports very similar findings to the work from Babis et al, with good outcomes (high retrospective follow up PROMS data, no revisions, and 4 patients returning for staged bilateral surgery) where double level osteotomy had enabled restoration of axis whilst maintaining acceptable joint line obliquity.

Another useful cohort study comes from Saragaglia et al [146] in France. This unit has routinely applied computer navigation and have now conducted over a thousand osteotomies [147] using navigation. 42 double osteotomies were conducted in severe genu varum ( $>8^\circ$ ) using a navigated technique. The lateral closing wedge of 4-7mm was taken from the femur and then fixed, before the MOW HTO was performed aiming for HKA  $182 \pm 2$  and MPTA  $90 \pm 2$ . They argue that computer navigation technique allows intra-operative correction and overcomes problems with landmarks moving after completion of the femoral osteotomy.

Nakayama [129] created a finite element model and simulated different conditions to judge medial or lateral stress across the knee (Figure 41). Shear stress in the medial compartment increased to almost twice normal when joint line obliquity reached  $5^\circ$  and this incrementally elevated with increasing obliquity. Not surprisingly they conclude that this unfavorable mechanical environment which may be detrimental to articular cartilage should be avoided by considering double level osteotomy.

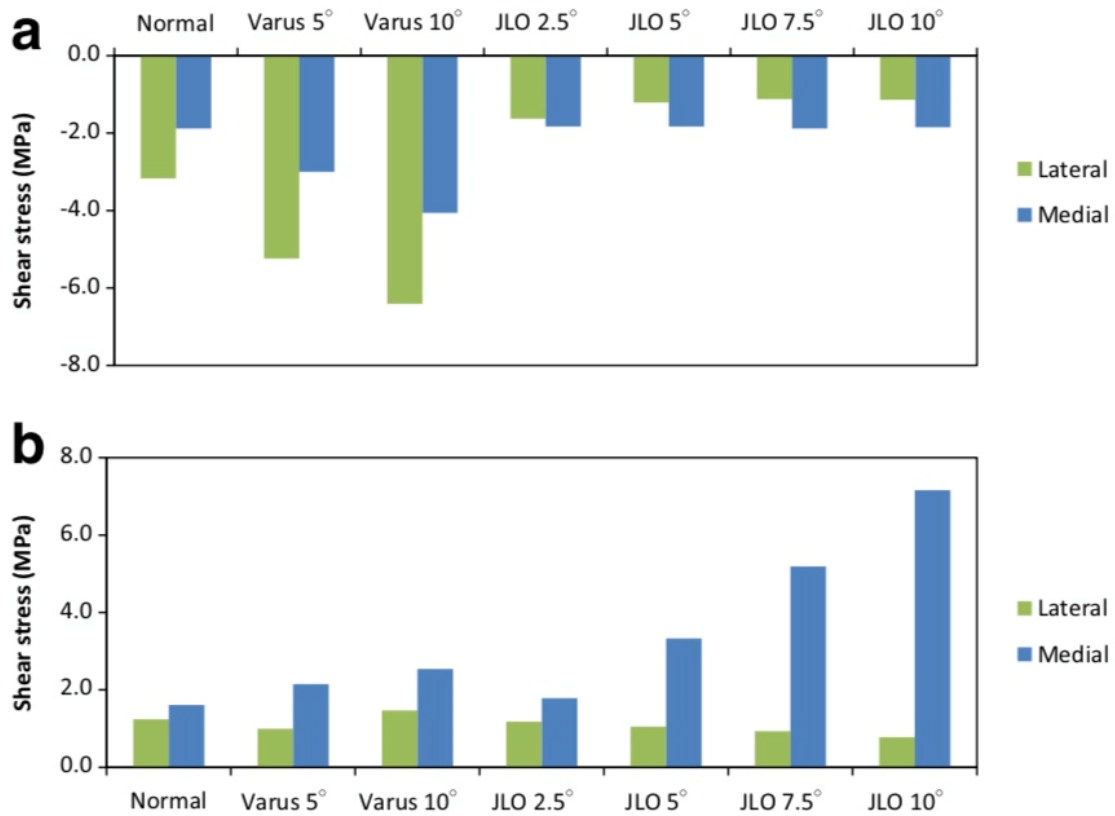


Figure 41: Maximum mediolateral shear stress in the medial and lateral compartments. Taken from Nakayama [129]. The top graph (a) shows medially directed shear stress and the bottom graph (b) displays laterally directed shear stress.

Saito [144] proposed a modification with a further intra-articular osteotomy to rotate around the medial compartment further to increase the valgizing effect

### **8) How is ankle joint line orientation influenced by osteotomy?**

Ankle joint line orientation in the coronal plane is affected by osteotomy around the knee, becoming either more or less parallel to the ground. Large corrections performed solely at the level of the proximal tibia risk placing the ankle into valgus alignment with subsequent development of ankle symptoms. A predicted clinical problem may not however be seen due to adaptive changes in the ankle and hindfoot except in patients with limited subtalar joint motion. Differences related to ethnicity require more research.

#### **Grade D**

##### **Literature review:**

There is limited evidence concerning acceptable ankle joint line orientation. However, in a retrospective study of 35 knees undergoing medial opening wedge high tibial osteotomy (MOW HTO), Shah et al. [155] noted that for patients with  $\geq 10^\circ$  change in their tibial plafond inclination, the odds ratio (OR) for developing ankle or hindfoot symptoms was 10.8 ( $p = 0.04$ ).

Of 86 knees undergoing MOW HTO, Choi et al. [26] found that the ankle joint line became less parallel to the ground in 7 cases (8.1%). Pre-operative lateral distal tibial angle (LDTA) was significantly lower and post-operative visual analogue scale (VAS) for pain at the ankle was significantly higher in this group than in the group whose ankle joint line orientation became more parallel to the ground. In a retrospective study of 40 MOW HTOs, Ariyawatkul et al. [6] observed the ankle joint line to become less parallel to the ground in 11 cases (27.5%). The change in the anatomical femorotibial angle (aFTA) correlated significantly with the change in the ankle joint line orientation and receiver operator curve (ROC) analysis determined that an aFTA correction of  $>14^\circ$  conferred a 50% chance of making the ankle joint line less parallel to the ground. Similar findings were noted in a study of total knee arthroplasty patients by Graef et al. [62]. In this study, the degree of mechanical FTA correction correlated strongly with the Foot Function Index and ROC analysis determined a cut-off value for varus arthritic knee deformities of  $14.5^\circ$ , above which the prevalence of ankle symptoms increased manifold (OR = 15.6). Furthermore, restricted subtalar joint motion was associated with worse outcomes at the ankle joint.

In a case series of two, HTO was used to treat both knee OA and ankle OA [11]. This effect was observed in another case with positive effect [49]<sup>196</sup> but has also been reported with negative clinical effect when a tibial osteotomy was overcorrected<sup>197</sup>. Krause et al [11] conducted a cadaveric study and identified that osteotomies do alter ankle pressure characteristics and this was more noticeable when the subtalar joint was fixed in varus.

**9) When correcting a varus arthritic knee how is intra-articular deformity factored into the plan?**

Additional ligament laxity and intra-articular deformity increasing the varus deformity can be measured using the joint line convergence angle (JLCA) according to Paley et al. JLCA >2 is considered abnormal and should be accounted for in overall alignment planning to prevent bony overcorrection. The degree to which this abnormality will reverse following bony correction and upon resumption of weight-bearing varies between individual cases. Various pre-operative and intra-operative methods are described to help prevent bony overcorrection in abnormal JLCA cases (see table 5 below)

**Grade C**

Paper	Theory behind the adjustment to planning	Formula or details
Micicoi G 2020 [117]	Ignore JLCA values <2° as this is normal. Therefore <b>subtract 2</b> from the measured JLCA. About <b>half</b> of this will correct with valgus osteotomy	$(JLCA - 2) / 2$
Akasaki 2020 {Akasaki:2020dm}	Simulate the valgising osteotomy by performing long leg x-rays on a lateral insole wedge	JLCA on the simulated x-rays is the patient specific JLCA after the correction
Lee DK 2020 {DokyungLee:2020gs}	Multiple logistic regression analysis	$JLCA\ change = -1.7 + (0.6 \times \text{latent medial laxity}) + (0.2 \times \text{correction angle})$
Takagawa 2019 [169]	Multiple logistic regression analysis	$\text{Post-operative soft tissue correction} = (0.69 \times JLCA) - (0.41 \times \text{valgus JLCA}) - 0.39$
So 2019 [163]	Multiple logistic regression analysis	When $\Delta JLCA$ exceeds 3°, then each degree of $\Delta JLCA$ should be subtracted
Kim 2017 [92]	Predictive additional overcorrection	Apply valgus stress if using fluoroscopic confirmation methods

*Table 5. Pre-operative equations to predict JLCA change or soft tissue correction*

**Literature review:**

Pre-operative planning prescribes the bone entry position, level, inclination and direction of the osseous cut heading towards a hinge point and taking account of the saw blade kerf. If the hinge remains intact during the opening or closing procedure, then the subsequent osseous geometry can be reasonably predicted from the pre-operative plan.

The knee is stabilized by medial and lateral collateral ligaments which become lax in arthritic conditions because joint space is lost, resulting in adjacent collateral relaxation. The resulting collateral laxity may be more marked in greater degrees of arthritis and deformity, prior to corrective osteotomy surgery. Any subsequent stretch in the collaterals after osteotomy will influence final alignment of the limb. This may be less predictable than the osseous component and



has been described by some authors as a soft tissue lottery. So, the real question here is how can we account for the unpredictability of soft tissue recruitment in our planning model?

In straightforward cases the joint line convergence angle <sup>21</sup> is typically 0° -2° when the tangent to the femur and tibia are almost parallel. In worsening uni-compartmental arthritis, intra-articular cartilage loss reduces the joint space between femur and tibia. The joint line convergence angle (JLCA) subsequently increases as the femoral and tibial joint line tangents diverge from being parallel to each other. In theory the collateral ligament on the arthritic side then becomes slack, with the potential to stretch back to its previous length at corrective osteotomy. Heijens et al. [67] compared mean change in MPTA, against mean change in mTFA, to reach the conclusion that 20% of lower limb corrections can be attributed to soft tissue changes.

In a valgizing corrective osteotomy the medial axis will shift across the knee and the medial compartment has been shown to open [56], relieving pressure on the articular cartilage with a potential regenerative effect. Heijens et al. [68] confirmed this medial opening in a pilot study of 50 cases where the influence of soft tissue structures was found to increase in more severe cases of arthritis. Subsequently the same group hypothesized that a coronal hypomochlion exists when performing a valgizing tibial osteotomy [67]. Hypomochlion is defined as the centre of rotation of a joint. This was identified occurring beyond 2° of valgus where joint line opening occurred in a linear fashion with increasing valgus, a so called “pivot or tipping point” for the knee.

Several different papers make the observation that correction errors occur more frequently in cases with severe arthritis or higher JLCA as described hereafter. This may be reported as differences in pre-operative digital planning and post-operative corrections if soft tissue laxity was unaccounted [92] [95] [163] [181]. So when is soft tissue laxity more likely to affect the achieved correction?

Park et al [137] showed overcorrection was more likely to occur in cases with pre-operative JLCA > 4° and valgus stress x-rays >1.5°. Goshima [60] published similar findings, where the overcorrected group had larger JLCA before surgery. Tsuji [181] found that pre-operative deformity and standing JLCA were higher in the outlier group. Kumagai [94] demonstrated with multiple regression analysis that post-operative JLCA on the day of surgery was the factor related to early post-operative change in TFA (early loss of achieved correction). Ogawa [133] demonstrated moderate correlation between pre-operative varus laxity and overcorrection. Lee [39] identified high correlation between correction errors and the change in JLCA. In summary correction errors were more frequent when JLCA is higher which should serve as an alarm bell reminding surgeons to account for soft tissue laxity when planning.

The fundamental unknown is the extent of JLCA reduction in each individual case, as this will influence final correction. Ji et al [84] showed that the change in JLCA was less in smaller initial JLCA (1.1° change if pre-op JLCA <2°) compared to larger initial JLCA (2° change if pre-op JLCA > 6°) suggesting a limited capacity for HTO to reduce the JLCA. It therefore cannot be assumed that the JLCA will be fully corrected by the osteotomy procedure. Bardot et al [13] have suggested that transitioning from double to single leg stance particularly in cases where the JLCA is high may be a simple way to predict patient specific changes in the JLCA.

This literature review subsequently discusses papers where an adjustment to pre-operative planning is proposed to account for the intra-articular deformity. All of these recommended adjustments are only very recently published and so an obvious limitation is that there are no subsequent papers which go on to validate or compare the accuracy of these methods. However, it may come to pass

that further studies will confirm or refute the accuracy achieved with these intra-articular adjustments. These are summarised in the table below as pre-operative equations to predict JLCA change or soft tissue correction:

- Takagawa et al [169] studied 49 knees and identified that JLCA and valgus JLCA were significantly associated with post-operative soft tissue correction. These factors were input into a multiple logistic regression to generate a prediction formula (table 9.1). The final model however only accounted for 37.1% of the variation in postoperative soft tissue correction
- Lee et al. [39] studied 34 navigated HTO cases and identified that  $\Delta$ JLCA had significant correlations with latent medial laxity and correction angle. The formula shown (table 9.1) was generated with these factors input into a multiple logistic regression. The final model accounted for 49% of the variation in JLCA
- So et al [163] conducted a study of 114 navigated tibial osteotomies and used logistical regression models to identify that the difference between standing and supine radiographs was the most important factor in predicting coronal correction discrepancy. These authors suggested that when  $\Delta$ JLCA exceeds  $3^\circ$ , then each degree of  $\Delta$ JLCA should be subtracted from the planned correction
- Kim et al. [92] proposed using intra-operative valgus stress applied to the knee during fluoroscopic alignment confirmation which reduced the number of outliers
- The approach by Akasaki is a novel pre-operative intervention using a temporary lateral  $20^\circ$  wedge insole to simulate a medial opening HTO. The resultant JLCA should match the post osteotomy JLCA as a patient specific prediction of the intra-articular changes to consider when planning
- Kristian Kley takes a pragmatic approach to the problem in his formula written up by Micicoi et al. [117] He suggests ignoring this correction when JLCA  $< 2^\circ$  but consider this solution for values greater than  $2^\circ$ . So, if we ignore values less than  $2^\circ$  this can be subtracted from the pre-operative measurement for JLCA. It is recognised that not all of the joint line convergence angle will correct. Pragmatically the suggestion is to halve the remainder because this adjustment will centre the normal distribution of this unpredictability, which should minimise this error



## **References:**

1. Aglietti P, Rinonapoli E, Stringa G, Taviani A (1983) Tibial osteotomy for the varus osteoarthritic knee. *Clin Orthop Relat Res* 176:239–251
2. Ahrend M, Winter A, Dawson MJ, Elson DW (2017, March 28) Rotation on long-leg radiographs influences the surgical accuracy of osteotomies around the knee. *British Association for Surgery of the Knee, Southport*
3. Akamatsu Y, Kumagai K, Kobayashi H, Tsuji M, Saito T (2018) Effect of Increased Coronal Inclination of the Tibial Plateau After Opening-Wedge High Tibial Osteotomy. *Arthroscopy* 34:2158–2169.e2
4. Altay MA, Ertürk C, Altay N, Mercan AŞ, Sipahioğlu S, Kalender AM, Işikan UE (2016) Clinical and radiographic outcomes of medial open-wedge high tibial osteotomy with Anthony-K plate: prospective minimum five-year follow-up data. *Int Orthop* 40:1447–1454
5. Amendola A, Rorabeck CH, Bourne RB, Apyan PM (1989) Total knee arthroplasty following high tibial osteotomy for osteoarthritis. *J Arthroplasty* 4: S11–S17
6. Ariyawatkul T, Pornrattanamaneewong C, Narkbunnam R, Chareancholvanich K (2014) Talar coronal malalignment as a consequence after high tibial osteotomy in osteoarthritic knee patients. *J Med Assoc Thai* 97 Suppl 9:S34–8
7. Asik M, Sen C, Kilic B, Goksan SB, Ciftci F, Taser OF (2006) High tibial osteotomy with Puddu plate for the treatment of varus gonarthrosis. *Knee Surg Sports Traumatol Arthrosc* 14:948–954
8. Babis GC, An K-N, Chao EYS, Rand JA, Sim FH (2002) Double level osteotomy of the knee: a method to retain joint-line obliquity. *Clinical results. J Bone Joint Surg Am* 84-A:1380–1388
9. Bachhal V, Sankhala SS, Jindal N, Dhillon MS (2011) High tibial osteotomy with a dynamic axial fixator: precision in achieving alignment. *J Bone Joint Surg Br* 93:897–903
10. Bae DK, Song SJ, Yoon KH (2009) Closed-wedge high tibial osteotomy using computer-assisted surgery compared to the conventional technique. *J Bone Joint Surg Br* 91:1164–1171
11. Baek JH, Lee SC, Jin H, Ahn HS, Nam CH (2021) Open wedge high tibial osteotomy for the treatment of osteoarthritis of both knee and ankle in the same leg: A report of two cases. *Clin Case Rep* 9:e04140
12. Bao Z, Qiao L, Qin J, Xu J, Zhou S, Chen D, Shi D, Dai J, Yao Y, Jiang Q, Xu Z (2017) The assessment of femoral shaft morphology in the sagittal plane in Chinese patients with osteoarthritis—a radiographic analysis. *J Orthop Surg Res* 12:127–7





13. Bardot L-P, Micicoi G, Favreau H, Zeman P, Khakha R, Ehlinger M, Ollivier M (2021) Global varus malalignment increase from double-leg to single-leg stance due to intra-articular changes. *Knee Surg Sports Traumatol Arthrosc* 20:586–6
14. Bauer GC, Insall J, Koshino T (1969) Tibial osteotomy in gonarthrosis (osteo-arthritis of the knee). *J Bone Joint Surg Am* 51:1545–1563
15. Bellemans J, Colyn W, Vandenuecker H, Victor J (2012) The Chitranjan Ranawat award: is neutral mechanical alignment normal for all patients? The concept of constitutional varus. *Clin Orthop Relat Res* 470:45–53
16. Benjamin A (1969) Double osteotomy for the painful knee in rheumatoid arthritis and osteoarthritis. *J Bone Joint Surg Br* 51:694–699
17. Birmingham TB, Giffin JR, Chesworth BM, Bryant DM, Litchfield RB, Willits K, Jenkyn TR, Fowler PJ (2009) Medial opening wedge high tibial osteotomy: A prospective cohort study of gait, radiographic, and patient-reported outcomes. *Arthr Care Res* 61:648–657
18. Birmingham TB, Moyer R, Leitch K, Chesworth B, Bryant D, Willits K, Litchfield R, Fowler PJ, Giffin JR (2017) Changes in biomechanical risk factors for knee osteoarthritis and their association with 5-year clinically important improvement after limb realignment surgery. *Osteoarthr Cartil* 25:1999–2006
19. Bonnin M, Chambat P (2004) Der Stellenwert der valgusierenden, zuklappenden Tibiakopfosteotomie bei der medialen Gonarthrose. *Der Orthopäde* 33:135–142
20. Brazier J, Migaud H, Gougeon F, Cotten A, Fontaine C, Duquennoy A (1996) [Evaluation of methods for radiographic measurement of the tibial slope. A study of 83 healthy knees]. *Rev Chir Orthop Reparatrice Appar Mot* 82:195–200
21. Brosset T, Pasquier G, Migaud H, Gougeon F (2011) Opening wedge high tibial osteotomy performed without filling the defect but with locking plate fixation (TomoFix™) and early weight-bearing: prospective evaluation of bone union, precision and maintenance of correction in 51 cases. *Orthop Traumatol Surg Res* 97:705–711
22. Brouwer GM, van Tol AW, Bergink AP, Belo JN, Bernsen RMD, Reijman M, Pols HAP, Bierma-Zeinstra SMA (2007) Association between valgus and varus alignment and the development and progression of radiographic osteoarthritis of the knee. *Arthritis Rheum* 56:1204–1211
23. Brouwer RW, Bierma-Zeinstra SMA, van Raaij TM, Verhaar JAN (2006) Osteotomy for medial compartment arthritis of the knee using a closing wedge or an opening wedge controlled by a Puddu plate. A one-year randomised, controlled study. *J Bone Joint Surg Br* 88:1454–1459
24. Chao EY, Neluheni EV, Hsu RW, Paley D (1994) Biomechanics of malalignment. *Orthop Clin North Am* 25:379–386



25. Cho YJ, Song SJ, Rhyu KH, Jang TS, Park CH (2018) Clinical and radiologic results after open-wedge high tibial osteotomy in haemophilic knee arthropathy with varus deformity. *Haemophilia* 24:792–799
26. Choi GW, Yang JH, Park JH, Yun HH, Lee YI, Chae JE, Yoon J-R (2017) Changes in coronal alignment of the ankle joint after high tibial osteotomy. *Knee Surg Sports Traumatol Arthrosc* 25:838–845
27. Choi WC, Kim B, Kim U, Lee Y, Kim J-H (2017) Gap healing after medial open-wedge high tibial osteotomy using injectable beta-tricalcium phosphate. *J Orthop Surg (Hong Kong)* 25:2309499017727942
28. Cooke D, Scudamore A, Li J, Wyss U, Bryant T, Costigan P (1997) Axial lower-limb alignment: comparison of knee geometry in normal volunteers and osteoarthritis patients. *Osteoarthr Cartil* 5:39–47
29. Cooke TD, Li J, Scudamore RA (1994) Radiographic assessment of bony contributions to knee deformity. *Orthop Clin North Am* 25:387–393
30. Cooke TD, Scudamore RA, Bryant JT, Sorbie C, Siu D, Fisher B (1991) A quantitative approach to radiography of the lower limb. Principles and applications. *J Bone Joint Surg Br* 73:715–720
31. Cooke TDV, Harrison L, Khan B, Scudamore A, Chaudhary MA (2002) Analysis of limb alignment in the pathogenesis of osteoarthritis: a comparison of Saudi Arabian and Canadian cases. *Rheumatol Int* 22:160–164
32. Cooke TDV, Sled EA (2009) Optimizing limb position for measuring knee anatomical axis alignment from standing knee radiographs. *J Rheumatol* 36:472–477
33. Coventry MB (1965) Osteotomy of the upper portion of the tibia for degenerative arthritis of the knee. A preliminary report. *J Bone Joint Surg Am* 47:984–990
34. Coventry MB (1973) Osteotomy about the knee for degenerative and rheumatoid arthritis. *J Bone Joint Surg Am* 55:23–48
35. Coventry MB (1979) Upper tibial osteotomy for gonarthrosis. The evolution of the operation in the last 18 years and long-term results. *Orthop Clin North Am* 10:191–210
36. Coventry MB (1987) Proximal tibial varus osteotomy for osteoarthritis of the lateral compartment of the knee. *J Bone Joint Surg Am* 69:32–38
37. Da Cunha RJ, Kraszewski AP, Hillstrom HJ, Fragomen AT, Rozbruch SR (2020) Biomechanical and Functional Improvements Gained by Proximal Tibia Osteotomy Correction of Genu Varum in Patients with Knee Pain. *HSS Journal* 16:30–38
38. Deakin AH, Sarungi M (2014) A comparison of variable angle versus fixed angle distal femoral resection in primary total knee arthroplasty. *J Arthroplasty* 29:1133–1137



39. Do kyung Lee, Wang JH, Won Y, Min YK, Jaiswal S, Lee BH, Kim J-Y (2020) Preoperative latent medial laxity and correction angle are crucial factors for overcorrection in medial open-wedge high tibial osteotomy. *Knee Surg Sports Traumatol Arthrosc* 28:1411–1418
40. Dugdale TW, Noyes FR, Styer D (1992) Preoperative planning for high tibial osteotomy. The effect of lateral tibiofemoral separation and tibiofemoral length. *Clin Orthop Relat Res* 274:248–264
41. Duivenvoorden T, Brouwer RW, Baan A, Bos PK, Reijman M, Bierma-Zeinstra SMA, Verhaar JAN (2014) Comparison of closing-wedge and opening-wedge high tibial osteotomy for medial compartment osteoarthritis of the knee: a randomized controlled trial with a six-year follow-up. *J Bone Joint Surg Am* 96:1425–1432
42. Duparc J, Massare C (1967) [Radiological measurement of the angular deviation of the knee in the frontal plane]. *Ann Radiol (Paris)* 10:635–656
43. Ekeland A, Nerhus TK, Dimmen S, Thornes E, Heir S (2017) Good functional results following high tibial opening-wedge osteotomy of knees with medial osteoarthritis: A prospective study with a mean of 8.3 years of follow-up. *Knee* 24:380–389
44. El-Azab HM, Morgenstern M, Ahrens P, Schuster T, Imhoff AB, Lorenz SGF (2011) Limb alignment after open-wedge high tibial osteotomy and its effect on the clinical outcome. *Orthopedics* 34:e622–8
45. Elson DW (2017) The surgical accuracy of knee osteotomy. *Knee* 24:167–169
46. Elson DW (2017) The surgical accuracy of knee osteotomy. *Knee* 24:167–169
47. Elson DW, Dawson M, Wilson C, Risebury M, Wilson A (2015) The UK Knee Osteotomy Registry (UKKOR). *Knee* 22:1–3
48. Elson DW, Harry Charles P, Thomas B, Alexander P (2018) The United Kingdom Knee Osteotomy Registry. <https://www.ukkor.co.uk/>
49. Elson DW, Paweleck JE, Shields DW, Dawson MJ, Ferrier GM (2013) Stretching the indications: high tibial osteotomy used successfully to treat isolated ankle symptoms. *BMJ Case Rep* 2013:1–4
50. Elson DW, Petheram TG, Dawson MJ (2015) High reliability in digital planning of medial opening wedge high tibial osteotomy, using Miniaci's method. *Knee Surg Sports Traumatol Arthrosc* 23:2041–2048
51. Engel GM, Lippert FG (1981) Valgus tibial osteotomy: avoiding the pitfalls. *Clin Orthop Relat Res* 160:137–143
52. Feucht MJ, Minzlaff P, Saier T, Cotic M, Südkamp NP, Niemeyer P, Imhoff AB, Hinterwimmer S (2014) Degree of axis correction in valgus high tibial osteotomy: proposal of an individualised approach. *Int Orthop* 38:2273–2280

53. Frank W, Oest O, Rettig H (1974) [The total x-ray-picture in the planning of correction-osteotomy-operations on legs (author's transl)]. *Z Orthop Ihre Grenzgeb* 112:344–347
54. Fujisawa Y, Masuhara K, Shiomi S (1979) The effect of high tibial osteotomy on osteoarthritis of the knee. An arthroscopic study of 54 knee joints. *Orthop Clin North Am* 10:585–608
55. Gaasbeek RDA, Nicolaas L, Rijnberg WJ, van Loon CJM, van Kampen A (2010) Correction accuracy and collateral laxity in open versus closed wedge high tibial osteotomy. A one-year randomised controlled study. *Int Orthop* 34:201–207
56. Galla M, Lobenhoffer P (2009) Physiological axes of the lower limb. In *Osteotomies around the Knee*, Thieme, New York, pp 5–14
57. Gebhard F, Krettek C, Hübner T, Grützner PA, Stöckle U, Imhoff AB, Lorenz S, Ljungqvist J, Keppler P, AO CSEG (2011) Reliability of computer-assisted surgery as an intraoperative ruler in navigated high tibial osteotomy. *Arch Orthop Trauma Surg* 131:297–302
58. Gelber PE, Isart A, Erquicia JI, Pelfort X, Tey-Pons M, Monllau JC (2015) Partial meniscus substitution with a polyurethane scaffold does not improve outcome after an open-wedge high tibial osteotomy. *Knee Surg Sports Traumatol Arthrosc* 23:334–339
59. Glasser O (1995) W. C. Roentgen and the discovery of the Roentgen rays. *Am J Roentgenol* 165:1033–1040
60. Goshima K, Sawaguchi T, Shigemoto K, shintaro I, fujita K, yamamuro Y (2019) Comparison of Clinical and Radiologic Outcomes Between Normal and Overcorrected Medial Proximal Tibial Angle Groups After Open-Wedge High Tibial Osteotomy. *Arthroscopy* 35:2898–2908.e1
61. Gouin F, Yaouanc F, Waast D, Melchior B, Delecrin J, Passuti N (2010) Open wedge high tibial osteotomies: Calcium-phosphate ceramic spacer versus autologous bonegraft. *Orthop Traumatol Surg Res* 96:637–645
62. Graef F, Falk R, Tsitsilonis S, Perka C, Zahn RK, Hommel H (2020) Correction of excessive intraarticular varus deformities in total knee arthroplasty is associated with deteriorated postoperative ankle function. *Knee Surg Sports Traumatol Arthrosc* 28:3758–3765
63. Hankemeier S, Mommsen P, Krettek C, Jagodzinski M, Brand J, Meyer C, Meller R (2010) Accuracy of high tibial osteotomy: comparison between open- and closed-wedge technique. *Knee Surg Sports Traumatol Arthrosc* 18:1328–1333
64. Hantes ME, Natsaridis P, Koutalos AA, Ono Y, Doxariotis N, Malizos KN (2018) Satisfactory functional and radiological outcomes can be expected in young patients under 45 years old after open wedge high tibial osteotomy in a long-term follow-up. *Knee Surg Sports Traumatol Arthrosc* 26:3199–3205
65. Harding ML (1976) A fresh appraisal of tibial osteotomy for osteoarthritis of the knee. *Clin Orthop Relat Res* 114:223–234



66. Harris WR, Kostuik JP (1970) High tibial osteotomy for osteo-arthritis of the knee. *J Bone Joint Surg Am* 52:330–336
67. Heijens E, Kornherr P, Meister C (2016) The coronal hypomochlion: a tipping point of clinical relevance when planning valgus producing high tibial osteotomies. *Bone Joint J* 98-B:628–633
68. Heijens E, Kornherr P, Meister C (2009) The role of navigation in high tibial osteotomy: a study of 50 patients. *Orthopedics* 32:40–43
69. Hernandez RJ, Tachdjian MO, Poznanski AK, Dias LS (1981) CT determination of femoral torsion. *Am J Roentgenol* 137:97–101
70. Hernigou P, Medevielle D, Debeyre J, Goutallier D (1987) Proximal tibial osteotomy for osteoarthritis with varus deformity. A ten to thirteen-year follow-up study. *J Bone Joint Surg Am* 69:332–354
71. Hess S, Moser LB, Amsler F, Behrend H, Hirschmann MT (2019) Highly variable coronal tibial and femoral alignment in osteoarthritic knees: a systematic review. *Knee Surg Sports Traumatol Arthrosc* 27:1368–1377
72. Hirschmann MT, Hess S, Behrend H, Amsler F, Leclercq V, Moser LB (2019) Phenotyping of hip–knee–ankle angle in young non-osteoarthritic knees provides better understanding of native alignment variability. *Knee Surg Sports Traumatol Arthrosc* 27:1378–1384
73. Hovinga KR, Lerner AL (2009) Anatomic variations between Japanese and Caucasian populations in the healthy young adult knee joint. *J Orthop Res* 27:1191–1196
74. Hsu RW, Himeno S, Coventry MB, Chao EY (1990) Normal axial alignment of the lower extremity and load-bearing distribution at the knee. *Clin Orthop Relat Res* 255: 215–227
75. Insall J, Shoji H, Mayer V (1974) High tibial osteotomy. A five-year evaluation. *J Bone Joint Surg Am* 56:1397–1405
76. Insall JN, Joseph DM, Msika C (1984) High tibial osteotomy for varus gonarthrosis. A long-term follow-up study. *J Bone Joint Surg Am* 66:1040–1048
77. Iorio R, Pagnottelli M, Vadalà A, Giannetti S, Di Sette P, Papandrea P, Conteduca F, Ferretti A (2013) Open-wedge high tibial osteotomy: comparison between manual and computer-assisted techniques. *Knee Surg Sports Traumatol Arthrosc* 21:113–119
78. Ishimatsu T, Takeuchi R, Ishikawa H, Yamaguchi Y, Maeyama A, Osawa K, Jung W-H (2019) Hybrid closed wedge high tibial osteotomy improves patellofemoral joint congruity compared with open wedge high tibial osteotomy. *Knee Surg Sports Traumatol Arthrosc* 27:1299–1309
79. Jabalameli M, Moghimi J, Yeganeh A, Nojomi M (2015) Parameters of Lower Extremities Alignment View in Iranian Adult Population. *Acta Med Iran* 53: 293–296

80. Jabalameli M, Moradi A, Bagherifard A, Radi M, Mokhtari T (2016) Evaluation of Distal Femoral Rotational Alignment with Spiral CT Scan before Total Knee Arthroplasty (A Study in Iranian population). *Arch Bone Jt Surg* 4:122–127
81. Jackson JP, Waugh W (1961) Tibial osteotomy for osteoarthritis of the knee. *J Bone Joint Surg Br* 43-B:746–751
82. Jackson JP, Waugh W (1974) The technique and complications of upper tibial osteotomy. A review of 226 operations. *J Bone Joint Surg Br* 56:236–245
83. Jarrett DY, Oliveira AM, Zou KH, Snyder BD, Kleinman PK (2010) Axial Oblique CT to Assess Femoral Anteversion. *American Journal of Roentgenology* 194:1230–1233
84. Ji W, Luo C, Zhan Y, Xie X, He Q, Zhang B (2019) A residual intra-articular varus after medial opening wedge high tibial osteotomy (HTO) for varus osteoarthritis of the knee. *Arch Orthop Trauma Surg* 139:743–750
85. Kaiser P, Attal R, Kammerer M, Thauerer M, Hamberger L, Mayr R, Schmoelz W (2016) Significant differences in femoral torsion values depending on the CT measurement technique. *Arch Orthop Trauma Surg* 136:1259–1264
86. Kanto R, Nakayama H, Iseki T, Onishi S, Ukon R, Kanto M, Kambara S, Yoshiya S, Tachibana T (2021) Return to sports rate after opening wedge high tibial osteotomy in athletes. *Knee Surg Sports Traumatol Arthrosc* 29:381–388
87. Keene JS, Dyreby JR (1983) High tibial osteotomy in the treatment of osteoarthritis of the knee. The role of preoperative arthroscopy. *J Bone Joint Surg Am* 65:36–42
88. Kettelkamp DB, Wenger DR, Chao EY, Thompson C (1976) Results of proximal tibial osteotomy. The effects of tibiofemoral angle, stance-phase flexion-extension, and medial-plateau force. *J Bone Joint Surg Am* 58:952–960
89. Khattak MJ, Umer M, Davis ET, Habib M, Ahmed M (2010) Lower-Limb Alignment and Posterior Tibial Slope in Pakistanis: A Radiographic Study. *Journal of Orthopaedic Surgery* 18:22-25
90. Khurana D, Sankhala SS, Malik M, Shekhawat V, Rathore DS (2015) Comparative study of high tibial osteotomy using dynamic axial fixator and locked low-profile plate in medial osteoarthritis of knee. *Eur J Orthop Surg Traumatol* 25:763–773
91. Kim MK, Ha JK, Lee DW, Nam SW, Kim JG, Lee YS (2015) No correction angle loss with stable plates in open-wedge high tibial osteotomy. *Knee Surg Sports Traumatol Arthrosc* 23:1999–2006
92. Kim MS, Son JM, Koh IJ, Bahk JH, In Y (2017) Intraoperative adjustment of alignment under valgus stress reduces outliers in patients undergoing medial opening-wedge high tibial osteotomy. *Arch Orthop Trauma Surg* 137:1035–1045

93. Kraus VB, Vail TP, Worrell T, McDaniel G (2005) A comparative assessment of alignment angle of the knee by radiographic and physical examination methods. *Arthritis Rheum* 52:1730–1735
94. Kumagai K, Fujimaki H, Yamada S, Nejima S, Matsubara J, Inaba Y (2021) Difference in the early postoperative change of the joint line convergence angle between opening wedge and closed wedge high tibial osteotomies. *J Orthop Surg Res* 16:66–7
95. Kumagai K, Yamada S, Akamatsu T, Nejima S, Ogino T, Sotozawa M, Inaba Y (2021) Intraoperatively accurate limb alignment after opening wedge high tibial osteotomy can be lost by large knee joint line convergence angle during surgery. *Arch Orthop Trauma Surg* 141:23–28
96. Lee DH, Han S-B, Oh K-J, Lee JS, Kwon J-H, Kim J-I, Patnaik S, Shetty GM, Nha KW (2014) The weight-bearing scanogram technique provides better coronal limb alignment than the navigation technique in open high tibial osteotomy. *Knee* 21:451–455
97. Lee DH, Nha KW, Park S-J, Han S-B (2012) Preoperative and postoperative comparisons of navigation and radiologic limb alignment measurements after high tibial osteotomy. *Arthroscopy* 28:1842–1850
98. Lee DH, Park S-C, Park H-J, Han S-B (2016) Effect of soft tissue laxity of the knee joint on limb alignment correction in open-wedge high tibial osteotomy. *Knee Surg Sports Traumatol Arthrosc* 24:3704–3712
99. Lee KM, Chang CB, Park MS, Kang S-B, Kim TK, Chung CY (2015) Changes of knee joint and ankle joint orientations after high tibial osteotomy. *Osteoarthr Cartil* 23:232–238
100. Lee YS, Oh SH, Seon J-K, Song E-K, Yoon TR (2006) 3D femoral neck anteversion measurements based on the posterior femoral plane in ORTHODOC<sup>®</sup> system. *Med Bio Eng Comput* 44:895–906
101. Lin Y-H, Chang F-S, Chen K-H, Huang K-C, Su K-C (2018) Mismatch between femur and tibia coronal alignment in the knee joint: classification of five lower limb types according to femoral and tibial mechanical alignment. *BMC Musculoskelet Disord* 19:1–9
102. Liodakis E, Doxastaki I, Chu K, Krettek C, Gaulke R, Citak M, Kenaway M (2012) Reliability of the assessment of lower limb torsion using computed tomography: analysis of five different techniques. *Skeletal Radiol* 41:305–311
103. Luites JWH, Brinkman J-M, Wymenga AB, van Heerwaarden RJ (2009) Fixation stability of opening- versus closing-wedge high tibial osteotomy: a randomised clinical trial using radiostereometry. *J Bone Joint Surg Br* 91:1459–1465
104. Luyckx T, Zambianchi F, Catani F, Bellemans J, Victor J (2013) Coronal alignment is a predictor of the rotational geometry of the distal femur in the osteo-arthritic knee. *Knee Surg Sports Traumatol Arthrosc* 21:2331–2337





105. MacDessi SJ, Griffiths-Jones W, Harris IA, Bellemans J, Chen DB (2021) Coronal Plane Alignment of the Knee (CPAK) classification. *Bone & Joint* 360 103-B:329–337
106. Macewen W (1879) Antiseptic Osteotomy in Genu Valgum and Anterior Tibial Curves: With a Few Remarks on the Pathology of Knock-Knee. *Br Med J* 2:607–609
107. Macewen W (1880) *Osteotomy*. Churchill, London
108. Maderbacher G, Schaumburger J, Baier C, Zeman F, Springorum H-R, Dornia C, Grifka J, Keshmiri A (2014) Predicting knee rotation by the projection overlap of the proximal fibula and tibia in long-leg radiographs. *Knee Surg Sports Traumatol Arthrosc* 22:2982–2988
109. Maffulli N, Loppini M, Longo UG, Denaro V, Oliva F (2013) Bovine xenograft locking Puddu plate versus tricalcium phosphate spacer non-locking Puddu plate in opening-wedge high tibial osteotomy: a prospective double-cohort study. *Int Orthop* 37:819–826
110. Magyar G, Ahl TL, Vibe P, Toksvig-Larsen S, Lindstrand A (1999) Open-wedge osteotomy by hemicallotasis or the closed-wedge technique for osteoarthritis of the knee. A randomised study of 50 operations. *J Bone Joint Surg Br* 81:444–448
111. Maini L, Singh S, Kushwaha NS, Saini A, Rohilla S, Sharma H, Sharma V (2015) Radiographic analysis of the axial alignment of the lower extremity in Indian adult males. *J Arthro Joint Surg* 2:128–131
112. Maquet P (1980) The biomechanics of the knee and surgical possibilities of healing osteoarthritic knee joints. *Clin Orthop Relat Res* 146: 102–110
113. Marti CB, Gautier E, Wachtl SW, Jakob RP (2004) Accuracy of frontal and sagittal plane correction in open-wedge high tibial osteotomy. *Arthroscopy* 20:366–372
114. McClelland D, Barlow D, Moores TS, Wynn-Jones C, Griffiths D, Ogrodnik PJ, Thomas PBM (2016) Medium- and long-term results of high tibial osteotomy using Garches external fixator and gait analysis for dynamic correction in varus osteoarthritis of the knee. *Bone & Joint* 360 98-B:601–607
115. Mcnamara IR, Birmingham TB, Marsh JD, Chesworth BM, Bryant DM, Giffin JR (2014) A preference-based single-item measure of quality of life following medial opening wedge high tibial osteotomy: large improvements similar to arthroplasty. *Knee* 21:456–461
116. Mesgarzadeh M, Revesz G, Bonakdarpour A (1987) Femoral Neck Torsion Angle Measurement by Computed Tomography. *Journal of Computer Assisted Tomography* 11:799
117. Micicoi G, Khakha R, Kley K, Wilson A, Cerciello S, Ollivier M (2020) Managing intra-articular deformity in high Tibial osteotomy: a narrative review. *J Exo Orthop* 7:65–10
118. Mondanelli N, Giron F, Losco M, Buzzi R, Aglietti P (2017) Opening wedge high tibial osteotomy using a monoaxial dynamic external fixator. *Knee Surg Sports Traumatol Arthrosc* 25:306–313



119. Moore TM, Harvey JP (1974) Roentgenographic measurement of tibial-plateau depression due to fracture. *J Bone Joint Surg Am* 56:155–160
120. Moreland JR, Bassett LW, Hanker GJ (1987) Radiographic analysis of the axial alignment of the lower extremity. *J Bone Joint Surg Am* 69:745–749
121. Morin V, Pailhé R, Duval BR, Mader R, Cognault J, Rouchy R-C, Saragaglia D (2018) Gait analysis following medial opening-wedge high tibial osteotomy. *Knee Surg Sports Traumatol Arthrosc* 26:1838–1844
122. Moser LB, Hess S, Amsler F, Behrend H, Hirschmann MT (2019) Native non-osteoarthritic knees have a highly variable coronal alignment: a systematic review. *Knee Surg Sports Traumatol Arthrosc* 27:1359–1367
123. Moyer R, Wirth W, Duryea J, Eckstein F (2016) Anatomical alignment, but not goniometry, predicts femorotibial cartilage loss as well as mechanical alignment: data from the Osteoarthritis Initiative. *Osteoarthr Cartil* 24:254–261
124. Mullaji AB, Marawar SV, Mittal V (2009) A comparison of coronal plane axial femoral relationships in Asian patients with varus osteoarthritic knees and healthy knees. *J Arthroplasty* 24:861–867
125. Murphy SB, Simon SR, Kijewski PK, Wilkinson RH, Griscom NT (1987) Femoral anteversion. *J Bone Joint Surg Am* 69:1169–1176
126. Müller M, Strecker W (2008) Arthroscopy prior to osteotomy around the knee? *Arch Orthop Trauma Surg* 128:1217–1221
127. Na YG, Chang MJ, Eom SH, Kim SJ, Park SC, Kim TK (2017) Coronal alignment on the single-limb stance radiograph in posterolateral rotatory instability, osteoarthritis and healthy knees. *Knee* 24:63–69
128. Nakano N, Matsumoto T, Hashimura M, Takayama K, Ishida K, Araki D, Matsushita T, Kuroda R, Kurosaka M (2016) Coronal lower limb alignment in normal knees--A radiographic analysis of 797 normal knee subjects. *Knee* 23:209–213
129. Nakayama H, Schröter S, Yamamoto C, Iseki T, Kanto R, Kurosaka K, Kambara S, Yoshiya S, Higa M (2018) Large correction in opening wedge high tibial osteotomy with resultant joint-line obliquity induces excessive shear stress on the articular cartilage. *Knee Surg Sports Traumatol Arthrosc* 26:1873–1878
130. Nerhus TK, Ekeland A, Solberg G, Olsen BH, Madsen JE, Heir S (2017) No difference in time-dependent improvement in functional outcome following closing wedge versus opening wedge high tibial osteotomy: a randomised controlled trial with two-year follow-up. *Bone & Joint* 360 99-B:1157–1166
131. Nha KW, Oh SM, Ha YW, Patel MK, Seo JH, Lee BH (2019) Radiological grading of osteoarthritis on Rosenberg view has a significant correlation with clinical outcomes after

- medial open-wedge high-tibial osteotomy. *Knee Surg Sports Traumatol Arthrosc* 27:2021–2029
132. Odenbring S, Egund N, Knutson K, Lindstrand A, Larsen ST (1990) Revision after osteotomy for gonarthrosis. A 10-19-year follow-up of 314 cases. *Acta Orthop Scand* 61:128–130
  133. Ogawa H, Matsumoto K, Ogawa T, Takeuchi K, Akiyama H (2016) Preoperative varus laxity correlates with overcorrection in medial opening wedge high tibial osteotomy. *Arch Orthop Trauma Surg* 136:1337–1342
  134. Oh K-J, Ko YB, Bae JH, Yoon ST, Kim JG (2016) Analysis of Knee Joint Line Obliquity after High Tibial Osteotomy. *J Knee Surg* 29:649–657
  135. Ozel O, Yucel B, Mutlu S, Orman O, Mutlu H (2017) Changes in posterior tibial slope angle in patients undergoing open-wedge high tibial osteotomy for varus gonarthrosis. *Knee Surg Sports Traumatol Arthrosc* 25:314–318
  136. Paley D, Herzenberg JE, Tetsworth K, McKie J, Bhav A (1994) Deformity planning for frontal and sagittal plane corrective osteotomies. *Orthop Clin North Am* 25:425–465
  137. Park J-G, Kim J-M, Lee B-S, Lee S-M, Kwon O-J, Bin S-I (2020) Increased preoperative medial and lateral laxity is a predictor of overcorrection in open wedge high tibial osteotomy. *Knee Surg Sports Traumatol Arthrosc* 28:3164–3172
  138. Park J-Y, Chang CB, Kang D-W, Oh S, Kang S-B, Lee MC (2019) Development and validation of a prediction model for knee joint line orientation after high tibial osteotomy. *BMC Musculoskelet Disord* 20:434–9
  139. Paternostre F, Schwab P-E, Thienpont E (2014) The difference between weight-bearing and non-weight-bearing alignment in patient-specific instrumentation planning. *Knee Surg Sports Traumatol Arthrosc* 22:674–679
  140. Reikerås O, Bjerkreim I, Kolbenstvedt A (1983) Anteversion of the acetabulum and femoral neck in normals and in patients with osteoarthritis of the hip. *Acta Orthop Scand* 54:18–23
  141. Roos EM, Lohmander LS (2003) The Knee injury and Osteoarthritis Outcome Score (KOOS): from joint injury to osteoarthritis. *Health Qual Life Outcomes BioMed Central Ltd* 1:64
  142. Sadek AF, Osman MK, Laklok MA (2016) Management of combined knee medial compartmental and patellofemoral osteoarthritis with lateral closing wedge osteotomy with anterior translation of the distal tibial fragment: Does the degree of anteriorization affect the functional outcome and posterior tibial slope? *Knee* 23:857–861
  143. Sailhan F, Jacob L, Hamadouche M (2017) Differences in limb alignment and femoral mechanical-anatomical angles using two dimension versus three dimension radiographic imaging. *Int Orthop* 41:2009–2016
  144. Saito H, Yonekura A, Saito K, Shimada Y, Yamamura T, Sato T, Nozaka K, Kijima H, Fujii M, Kawano T, Murata S, Miyakoshi N (2021) A new double level osteotomy procedure to

restore a joint line and joint angles in severe varus osteoarthritis. - Double level osteotomy associated with tibial condylar valgus osteotomy (DLOTO). *Asia Pac J Sports Med Arthrosc Rehabil Technol* 24:9–13

145. Salzmann GM, Ahrens P, Naal FD, El-Azab H, Spang JT, Imhoff AB, Lorenz S (2009) Sporting activity after high tibial osteotomy for the treatment of medial compartment knee osteoarthritis. *Am J Sports Med* 37:312–318
146. Saragaglia D, Blaysat M, Mercier N, Grimaldi M (2012) Results of forty two computer-assisted double level osteotomies for severe genu varum deformity. *Int Orthop* 36:999–1003
147. Saragaglia D, Chedal-Bornu B, Rouchy RC, Rubens-Duval B, Mader R, Pailhé R (2016) Role of computer-assisted surgery in osteotomies around the knee. *Knee Surg Sports Traumatol Arthrosc* 24:3387–3395
148. Saragaglia D, Roberts J (2005) Navigated osteotomies around the knee in 170 patients with osteoarthritis secondary to genu varum. *Orthopedics* 28:s1269–74
149. Sawaguchi T, Takeuchi R, Nakamura R, Yonekura A, Akiyama T, Kerstan M, Goldhahn S (2020) Outcome after treatment of osteoarthritis with open-wedge high-tibial osteotomy with a plate: 2-year results of a Japanese cohort study. *J Orthop Surg (Hong Kong)* 28:2309499019887997
150. Schröter S, Elson DW, Ateschrang A, Ihle C, Stöckle U, Dickschas J, Harrer J (2017) Lower Limb Deformity Analysis and the Planning of an Osteotomy. *J Knee Surg* 30:393–408
151. Schröter S, Elson DW, Ateschrang A, Ihle C, Stöckle U, Dickschas J, Harrer J (2017) Lower Limb Deformity Analysis and the Planning of an Osteotomy. *J Knee Surg* 30:393–408
152. Schröter S, Ihle C, Elson DW, Döbele S, Stöckle U, Ateschrang A (2016) Surgical accuracy in high tibial osteotomy: coronal equivalence of computer navigation and gap measurement. *Knee Surg Sports Traumatol Arthrosc* 24:1–8
153. Schröter S, Nakayama H, Yoshiya S, Stöckle U, Ateschrang A, Gruhn J (2019) Development of the double level osteotomy in severe varus osteoarthritis showed good outcome by preventing oblique joint line. *Arch Orthop Trauma Surg* 139:519–527
154. Schuster P, Geßlein M, Schlumberger M, Mayer P, Mayr R, Oremek D, Frank S, Schulz-Jahrsdörfer M, Richter J (2018) Ten-Year Results of Medial Open-Wedge High Tibial Osteotomy and Chondral Resurfacing in Severe Medial Osteoarthritis and Varus Malalignment. *Am J Sports Med* 46:1362–1370
155. Shah SM, Roberts J, Picard F (2019) Ankle and Hindfoot Symptoms after Medial Open Wedge High Tibial Osteotomy. *J Knee Surg* 32:269–273
156. Sharma L, Song J, Felson DT, Cahue S, Shamiyeh E, Dunlop DD (2001) The role of knee alignment in disease progression and functional decline in knee osteoarthritis. *JAMA* 286:188–195



157. Shetty GM, Mullaji A, Bhayde S, Nha KW, Oh HK (2014) Factors contributing to inherent varus alignment of lower limb in normal Asian adults: role of tibial plateau inclination. *Knee* 21:544–548
158. Shetty GM, Mullaji A, Bhayde S, Nha KW, Oh HK (2014) Factors contributing to inherent varus alignment of lower limb in normal Asian adults: role of tibial plateau inclination. *Knee* 21:544–548
159. Shoji H, Insall J (1973) High tibial osteotomy for osteoarthritis of the knee with valgus deformity. *J Bone Joint Surg Am* 55:963–973
160. Sischek EL, Birmingham TB, Leitch KM, Martin R, Willits K, Giffin JR (2014) Staged medial opening wedge high tibial osteotomy for bilateral varus gonarthrosis: biomechanical and clinical outcomes. *Knee Surg Sports Traumatol Arthrosc* 22:2672–2681
161. Slocum DB, Larson RL, James SL, Grenier R (1974) High tibial osteotomy. *Clin Orthop Relat Res* 104:239–243
162. Smith JO, Wilson AJ, Thomas NP (2013) Osteotomy around the knee: evolution, principles and results. *Knee Surg Sports Traumatol Arthrosc* 21:3–22
163. So S-Y, Lee S-S, Jung EY, Kim JH, Wang JH (2020) Difference in joint line convergence angle between the supine and standing positions is the most important predictive factor of coronal correction error after medial opening wedge high tibial osteotomy. *Knee Surg Sports Traumatol Arthrosc* 28:1516–1525
164. Song J-H, Bin S-I, Kim J-M, Lee B-S (2020) What Is An Acceptable Limit of Joint-Line Obliquity After Medial Open Wedge High Tibial Osteotomy? Analysis Based on Midterm Results. *Am J Sports Med* 48: 3028-3035
165. Song M-H, Yoo S-H, Kang S-W, Kim Y-J, Park G-T, Pyeun Y-S (2015) Coronal alignment of the lower limb and the incidence of constitutional varus knee in korean females. *Knee Surg Relat Res Korean Knee Society* 27:49–55
166. Sprenger TR, Doerzbacher JF (2003) Tibial osteotomy for the treatment of varus gonarthrosis. Survival and failure analysis to twenty-two years. *J Bone Joint Surg Am* 85-A:469–474
167. Stanley JC, Robinson KG, Devitt BM, Richmond AK, Webster KE, Whitehead TS, Feller JA (2016) Computer assisted alignment of opening wedge high tibial osteotomy provides limited improvement of radiographic outcomes compared to flourosopic alignment. *Knee* 23:289–294
168. Strecker W, Keppler P, Gebhard F, Kinzl L (1997) Length and torsion of the lower limb. *J Bone Joint Surg Br* 79:1019–1023



169. Takagawa S, Kobayashi N, Yukizawa Y, Oishi T, Tsuji M, Inaba Y (2020) Preoperative soft tissue laxity around knee was associated with less accurate alignment correction after hybrid closed-wedge high tibial osteotomy. *Knee Surg Sports Traumatol Arthrosc* 28:3022–3030
170. Tanaka T, Takayama K, Hashimoto S, Kanzaki N, Hayashi S, Kuroda R, Matsumoto T (2017) Radiographic analysis of the lower limbs using the hip-calcaneus line in healthy individuals and in patients with varus knee osteoarthritis. *Knee* 24:1146–1152
171. Tang WC, Henderson IJP (2005) High tibial osteotomy: long term survival analysis and patients' perspective. *Knee* 12:410–413
172. Tang WM, Zhu YH, Chiu KY (2000) Axial Alignment of the Lower Extremity in Chinese Adults. *J Bone Joint Surg Am* 82:1603-1608
173. Tawy G, Shahbaz H, McNicholas M, Biant L (2021) The Relationships between Coronal Plane Alignments and Patient-Reported Outcomes Following High Tibial Osteotomy: A Systematic Review. *Cartilage* 13(1S): 132S-146S
174. Terauchi M, Shirakura K, Katayama M, Higuchi H, Takagishi K, Kimura M (2002) Varus inclination of the distal femur and high tibial osteotomy. *J Bone Joint Surg Br* 84:223–226
175. Than P, Szuper K, Somoskeöy S, Warta V, Illés T (2012) Geometrical values of the normal and arthritic hip and knee detected with the EOS imaging system. *Int Orthop* 36:1291–1297
176. Thienpont E, Schwab P-E, Paternostre F, Koch P (2014) Rotational alignment of the distal femur: anthropometric measurements with CT-based patient-specific instruments planning show high variability of the posterior condylar angle. *Knee Surg Sports Traumatol Arthrosc* 22:2995–3002
177. Tomczak RJ, Guenther KP, Rieber A, Mergo P, Ros PR, Brambs HJ (1997) MR imaging measurement of the femoral antetorsional angle as a new technique: comparison with CT in children and adults. *Am J Roentgenol American Public Health Association* 168:791–794
178. Torgerson WR, Kettelkamp DB, Igou RA, Leach RE (1974) Tibial osteotomy for the treatment of degenerative arthritis of the knee. *Clin Orthop Relat Res* 46–52
179. Torres-Claramunt R, Pelfort X, Hinarejos P, Gil-González S, Leal J, Sánchez-Soler JF, Monllau JC (2018) Pressure algometry is an excellent tool to measure knee pain relief after a closing-wedge high tibial osteotomy. *Orthop Traumatol Surg Res* 104:193–196
180. Tseng TH, Hsu KH, Wang JH (2020) Knee ankle joint line angle: a critical value at 10. for decompensated knee joint line obliquity in medial opening wedge osteotomy. <https://doi.org/10.21203/rs.3.rs-61775/v1>
181. Tsuji M, Akamatsu Y, Kobayashi H, Mitsugi N, Inaba Y, Saito T (2020) Joint line convergence angle predicts outliers of coronal alignment in navigated open-wedge high tibial osteotomy. *Arch Orthop Trauma Surg* 140:707–715



182. Mhaskar VA, Maheshwari J, Ugrasen H (2020) Bilateral HTO in the same sitting: perioperative challenge or feasible option? *J Arthrosc Joint Surg* 7:69–73
183. Vainionpää S, Läike E, Kirves P, Tiusanen P (1981) Tibial osteotomy for osteoarthritis of the knee. A five to ten-year follow-up study. *J Bone Joint Surg Am* 63:938–946
184. Van den Bempt M, Van Genechten W, Claes T, Claes S (2016) How accurately does high tibial osteotomy correct the mechanical axis of an arthritic varus knee? A systematic review. *Knee* 23:925–935
185. van der Woude JAD, Wiegant K, van Heerwaarden RJ, Spruijt S, van Roermund PM, Custers RJH, Mastbergen SC, Lafeber FPJG (2017) Knee joint distraction compared with high tibial osteotomy: a randomized controlled trial. *Knee Surg Sports Traumatol Arthrosc* 25:876–886
186. van Heerwaarden R (2008, December) Osteotomies of the lower limb - the importance of making a surgical plan. [www.esska.org](http://www.esska.org)
187. W-Dahl A, Toksvig-Larsen S, Roos EM (2009) Association between knee alignment and knee pain in patients surgically treated for medial knee osteoarthritis by high tibial osteotomy. A one-year follow-up study. *BMC Musculoskelet Disord BioMed Central* 10:154
188. W-Dahl A, Toksvig-Larsen S, Roos EM (2005) A 2-year prospective study of patient-relevant outcomes in patients operated on for knee osteoarthritis with tibial osteotomy. *BMC Musculoskelet Disord BioMed Central* 6:18–9
189. Waidelich HA, Strecker W, Schneider E (1992) [Computed tomographic torsion-angle and length measurement of the lower extremity. The methods, normal values and radiation load]. *Rofo* 157:245–251
190. Weinberg DS, Tucker BJ, Drain JP, Wang DM, Gilmore A, Liu RW (2016) A cadaveric investigation into the demographic and bony alignment properties associated with osteoarthritis of the patellofemoral joint. *Knee* 23:350–356
191. Whelton C, Thomas A, Elson DW, Metcalfe A, Forrest S, Wilson C, Holt C, Whatling G (2017) Combined effect of toe out gait and high tibial osteotomy on knee adduction moment in patients with varus knee deformity. *Clin Biomech (Bristol, Avon)* 43:109–114
192. Yazdanpanah O, Mobarakeh MK, Nakhaei M, Baneshi MR (2017) Comparison of Double and Single Leg Weight-Bearing Radiography in Determining Knee Alignment. *Arch Bone Jt Surg Mashhad University of Medical Sciences* 5:174–180
193. Yin Y, Zhang L, Hou Z, Yang Z, Zhang R, Chen W, Wang P (2016) Measuring femoral neck torsion angle using femoral neck oblique axial computed tomography reconstruction. *Int Orthop* 40:371–376
194. Yoshioka Y, Cooke TDV (1987) Femoral anteversion: Assessment based on function axes. *J Orthop Res* 5:86–91





195. Zampogna B, Vasta S, Amendola A, Uribe-Echevarria Marbach B, Gao Y, Papalia R, Denaro V (2015) Assessing Lower Limb Alignment: Comparison of Standard Knee Xray vs Long Leg View. *Iowa Orthop J University of Iowa* 35:49–54
196. Zhang R-Y, Su X-Y, Zhao J-X, Li J-T, Zhang L-C, Tang P-F (2020) Three-dimensional morphological analysis of the femoral neck torsion angle-an anatomical study. *J Orthop Surg Res* 15:192
197. Zhang Y, Wang X, Shao Y, Xia Q (2018) The orientation of the surgical epicondylar axis varies in varus and non-varus knees in the coronal plane. *Knee Surg Sports Traumatol Arthrosc* 26:2580–2586



### **Section 3 : SURGICAL STRATEGY**

- 1) Is there an ideal position of the hinge for varus knee MOWHTO and LCWDFO?
- 2) Should the hinge be protected when doing an osteotomy?
- 3) Is there an advantage of biplanar cut in MOWHTO and LCWDFO?
- 4) Should the technique be adjusted, based on the amount of correction required and the level of the deformity?
- 5) How does the osteotomy technique (Opening Wedge vs Closing Wedge) influence leg length?
- 6) Should the tibial osteotomy technique (Opening Wedge, Closing Wedge or direction of biplane cut) be modified in cases of patello-femoral disorder including patella baja?
- 7) Is there an ideal fixation to be promoted for MOWHTO or LCWDFO?
- 8) Should the gap be filled in MOWHTO?
- 9) What is the place for PSI in MOWHTO and LCWDFO?

MOWHTO      Medial opening wedge high tibial osteotomy

LCWDFO      Lateral closing wedge distal femoral osteotomy

PSI            Patient specific instrumentation

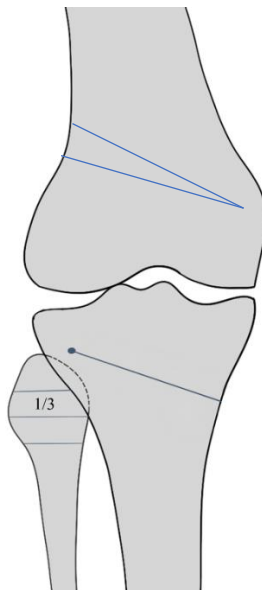
**1) Is there an ideal position of the Hinge for varus knee MOWHTO and LCWDFO?**

The final hinge position for the MOWHTO should be in the region of the proximal third of or just above the fibula head. The initial k-wire placement to determine the final hinge position should be immediately above this level for the final osteotomy cut to be at the optimal level. The hinge should be in a lateral position to avoid changes in the posterior tibial slope.

**Grade C**

The final hinge position for the LCWDFO should be located just above the level of the medial femoral condyle, adjacent to the downslope of the flare of the distal femur.

**Grade D**



The ideal hinge position minimises risk of type 2 and type 3 fracture

**Literature Review:**

Wang and Moon et al identified in a controlled laboratory study that the position of the hinge can have multiple effects on the resultant osteotomy. The location of the hinge influences the posterior tibial slope during medial opening wedge high tibial osteotomy. The change of the slope is significantly affected if the hinge is positioned in the posterolateral aspect of the tibia [21, 23, 39]. Similar studies by Lustig and Jo et al confirmed a more laterally based hinge position resulted in a reduced effect on the tibial slope [15, 21]. Therefore, positioning the hinge in a lateral position, can help to prevent a change in the posterior tibial slope. The position of the hinge also dictates its ability to withstand a hinge fracture. A study by Nakamura et al divided the region of the lateral cortex in relation to the fibula head. The abbreviation 'W' represented within the tibio-fibular joint



and 'A' represented above the tibio-fibular joint. 'M' or 'L' represented medial or lateral to the medial margin of the proximal tibio-fibular joint. This study recommended the 'WL' zone to be the safest area to prevent a hinge fracture during high tibial osteotomy surgery [25].

There are currently no clinical trials defining the optimal hinge point for a distal femoral osteotomy. The ideal position has been suggested by the expert panel on the ESSKA osteotomy committee.

## **2) Should the hinge be protected when doing an osteotomy?**

**Despite some technical notes supporting the use of a temporary hinge wire or screw in providing additional protection there is no clear evidence in the literature that the use of a hinge wire or screw is mandatory during osteotomy surgery**

### **Grade D**

#### **Literature Review:**

Various techniques to protect the hinge point have been described in the literature. Jacobi et al described the use of 5 wires in defined directions to help protect the hinge point [12]. This technique also utilised an external fixator device. The use of an antero-posterior drill hole was popularised by the study from Reyle et al which demonstrated a 78% increased medial opening during high tibial osteotomy surgery before a hinge fracture occurred [33]. However, correction angles more than 5° all specimens showed a hinge fracture. Ogawa and Nakamura et al demonstrated that performing an adequate osteotomy by cutting through the anterior and posterior cortex up to the level of the fibula head, was a protective approach in preventing a hinge fracture [25, 29]. More recently, the addition of a K-wire at the level of the hinge has been shown to significantly reduce the stresses going through the hinge point and reduce the incidence of a hinge fracture [10, 13].

## **3) Is there an advantage of biplanar cut in MOWHTO and LCWDFO?**

**In general, the biplane osteotomy provides additional stability, a larger surface contact area for bony union and rotational control in the presence of a hinge fracture. Further benefit is derived from avoidance of the patella tendon insertion during HTO.**

### **Grade C**

**Despite the lack of strong clinical evidence and limited biomechanical studies the recommendation is to use a biplanar cut in DFO for those learning the technique.**

### **Grade D**

#### **Literature review:**

The use of a biplane has been proven to provide increased rotational and anteroposterior stability [5]. Pape et al demonstrated the effects of the biplane osteotomy in a biomechanical cadaveric study where it was shown that the biplane cut adds to the primary stability in addition to the plate fixation [31]. The additional volume and surface area created by the biplane osteotomy results in a greater potential for bony union as demonstrated by van Heerwaarden et al [38]. The effect on the patellofemoral joint remains a debated area of research. A study by Yang et al investigated the use of proximal biplane osteotomy and its effect on patellar height, tilt and shift. They found that there was no significant change in patellar tilt however, there was an effect to lower the patella and increase the tibial slope [40]. Work by Suh et al confirmed the unintentional increase in tibial slope with a proximal biplane osteotomy [37]. Erquica et al utilised a distal biplane osteotomy and found that there was no effect on the patellofemoral joint [9]. Little has been published on the clinical outcomes of performing a proximal over distal biplane osteotomy.

#### **4) Should the technique be adjusted, based on the amount of correction required and the level of the deformity?**

**The consensus group recommends the use pre-operative planning in osteotomy surgery to determine the expected bony morphology after correction of the coronal alignment to determine optimal technique and level of osteotomy for surgical correction.**

#### **Grade B**

#### **Literature review:**

Early work by Babis et al in 2002 described the utilization of a double level osteotomy in order to maintain joint line obliquity [3]. This work described that in large varus corrections, performing a double level osteotomy prevented an adverse outcome with regards to the joint line obliquity that could not be achieved with a single level osteotomy [3]. Nakayama et al performed a 3D finite element analysis of performing large corrections for severe varus. This study demonstrated that if the correction was performed at a single level, this induced increased shear stresses across the articular cartilage, however, this was not observed if the correction was performed across the femur and tibia. An increased obliquity of greater than 5 degrees may induce detrimental shear stresses across the articular cartilage [26]. Various studies have looked at the effect of early weight bearing after osteotomy surgery and the benefits of improved early mobilization without a significant increased risk of complications has been universally advocated [18, 34].

#### **5) How does the osteotomy technique (Opening Wedge vs Closing Wedge) influence leg length?**

**When performing an opening wedge osteotomy (tibial or femoral), there may be a resultant increase in the leg length. Conversely, a closing wedge osteotomy (tibial or femoral), will tend to**

maintain an equal length. Although each case must be taken on its merits there is no evidence to support any adverse effect on clinical outcomes for either technique. It is therefore reasonable to consider pre-existing leg length discrepancy in surgical strategy and the appropriate selection of opening or closing wedge at the relevant level.

#### **Grade A**

##### **Literature review:**

Mathematical models looking at change in leg length following tibial osteotomy surgery demonstrate a change in length depending on whether a lateral closing wedge tibial osteotomy (LCWTO) or medial opening wedge tibial osteotomy (MOWTO) is performed. Magnussen et al performed a clinical study looking at the change in leg length following lateral closing wedge and medial opening wedge osteotomies. They found a mean significant reduction in the leg length of 2.7mm in the lateral closing wedge osteotomies and a mean significant increase of 5.5mm in medial opening wedge osteotomy surgery. It was noted that this clinical change was less than had been predicted in pre-operative mathematical models [22]. Bae et al utilised computer navigation to determine change in length comparing LCWTO and MOWTO osteotomies and found minimal change in limb length following LCWTO osteotomies and an increase in limb length following MOWTO osteotomy [4]. Randomised controlled studies by Nerhus et al and Kim et al also concluded a significant increase in leg length following MOWTO and a significant decrease following LCWHTO [17, 28].

#### **6) Should the tibial osteotomy technique (Opening Wedge, Closing Wedge or direction of biplane cut) be modified in cases of patello-femoral disorder including patella baja?**

The effects of various osteotomy techniques upon patello-femoral disorders is the subject of ongoing discussion and further research is required in this area . There are no clinical studies to strongly influence surgical technique in the presence of patello-femoral disorders. The effect of reducing patella height in medial opening wedge osteotomies and increasing the patella height in lateral closing wedge osteotomies appears negligible for routine corrections and therefore should not influence surgical strategy for this indication.

#### **Grade B**

Pending results of further investigation and in large opening wedge corrections a distal tuberosity osteotomy may be considered to prevent adverse effects on patella height and patellofemoral cartilage forces.

#### **Grade D**

##### **Literature review:**

Various studies have looked at the effect on the patella height depending on the osteotomy technique used. Several studies suggest a reduction in the patellar height following MOWHTO and a reduction in patellar height following LCWHTO [2, 6, 40]. A randomised controlled study by Nerhus et al comparing the MOWHTO and LCWHTO found no significant radiological changes in the patellar height between the two techniques [28]. Park et al and Erquicia et al considered the effects on patellar height in performing a MOWHTO with a distal biplane osteotomy and found it had no effect on the patellar height [9, 32]. No studies to date have looked at the clinical outcomes on the patellofemoral joint following surgery to correct varus malalignment.

### **7) Is there an ideal fixation to be promoted for MOWHTO or LCWDFO?**

**The consensus group recommends angle-stable locking plate fixators because they have been demonstrated to provide better clinical outcomes and a reduced correction loss when compared to non-locking plates. Long plate fixators are recommended in preference to short spacer plates as they have superior stability.**

#### **Grade A**

#### **Literature review:**

Angle stabled devices allow for early mobilization without the need for application of immobilization such as plaster of Paris [1]. Luites et al concluded in their radio-isometric study that the TomoFix plate fixator offered equalled levels off stability compared to a lateral closing wedge construct, which has traditionally been thought to have greater stability [20]. Many studies have evaluated the use of short spacer plates versus long locking plate fixation [16, 27, 30, 35]. The consensus amongst the literature is that the long locking plate fixation devices are superior at maintaining the desired coronal correction and have lower complications rates. Agarwala et al demonstrated that staples are sufficient in holding LCWHTO, however, a locking plate construct offers greater stability [1]. Little evidence exists to compare locking, non-locking and spacer devices for distal femoral osteotomies. There is evidence to support the use of locking plate devices for distal femoral osteotomies whether they are opening or closing wedges.

### **8) Should the gap be filled in MOWHTO?**

**The use of graft to fill the osteotomy gap is not required for routine use in MOWHTO surgery. Where required additional stability may be achieved with the use of structural void fillers. Ideally a choice of void filler where required should be available to the surgeon. Autograft bone void fillers can increase the rate of bony union but may be associated with donor site morbidity. Allograft options provide a potential solution especially in larger opening gaps but availability is not universal due to regulatory restrictions in some countries. Synthetic void fillers may have an increased risk of non-union and infection.**

#### **Grade B**



## Literature review:

Lash et al. [19] performed a systematic review to research this question. Their initial review included 56 peer reviewed articles and 3,033 cases of MOWHTO with a mean patient age of 50 and mean follow up period of 42 months. Of the 56 studies included, only 17 reported on time to union of the osteotomy site. The types of fillers used were autograft bone (29.5%), allograft bone (25.9%), tricalcium Phosphate (12.6%), calcium phosphate (7.2%), HA/tricalcium phosphate (3.4%), bioglass (1.7%), combined fillers (0.9%), coralline wedge (0.9%) and no filler (17.3%).

Autograft was associated with the shortest mean time to union (3.1 months), followed by allograft bone (3.8 months). Calcium phosphate, tricalcium phosphate and no filler had mean union times of 25 months, 10.6 months and 9 months respectively. Bioglass was only used in 2 cases with a mean union time of 4 months.

There was a combined delayed union rate of 2% (60 cases) and 1.4% non-union (43 cases). Delayed/non-union rates were 1.4%, 2.6%, 4.6% and 4.5% for the no filler group, autologous bone graft, allograft bone graft and synthetic bone substitutes respectively. They concluded that in terms of union timing and overall healing rates, the use of autograft shown statistically significant superiority compared to allograft use. Similarly, the use of allograft showed a statistically significant benefit compared to not using a void filler at all. Comparative rates using autograft or no filler showed no statistically significant benefit.

In terms of loss of correction, interestingly the cases that reported this outcome all used HA/tricalcium phosphate filler and were associated with a mean loss of 4 degrees of correction. This review also noted that the use of locking plates had a mean loss of correction of 2.3 degrees compared to non-locking plates that had a mean loss of 0.5 degrees. However, all cases that used HA/tricalcium phosphate filler were included in the locking plate analysis and thus might be a confounding factor.

Finally, HA/tricalcium phosphate use appeared to be associated with a superficial wound infection rate of 6.2% compared to 0.6% with other fillers. However, caution should be noted in analyzing this finding as all cases came from a single study.

Han et al. [11] performed a metanalysis to compare the radiological outcomes of MOWHTO with bone graft (autograft, allograft and synthetic bone) and those without bone graft. The hypotheses were that the use of bone graft would produce superior radiological outcomes. This included 25 studies and 1841 patients who underwent MOWHTO using four different void fillers. Out of 1841 patients 352 had autograft, 547 had allograft, 541 had synthetic graft and 401 had no void filler. Overall, they reported comparable results in all four void filler options with regards to delayed union, non union and loss of correction. However, based on their observation they reported union time of about three months for autograft, synthetic graft and no void filler group whereas longer union time over five months with allografts. A hinge fracture was found to be a significantly negative

prognostic factor to failure of the procedure. With this in mind, one may consider whether a procedure that undergoes a larger correction should be supplemented with a void filler. The authors attempted to extrapolate the data based on osteotomy gap size. They concluded that a void filler of any type is not recommended if the osteotomy is smaller than 14 mm as long as it has been stabilised with a rigid fixation using a locking system.

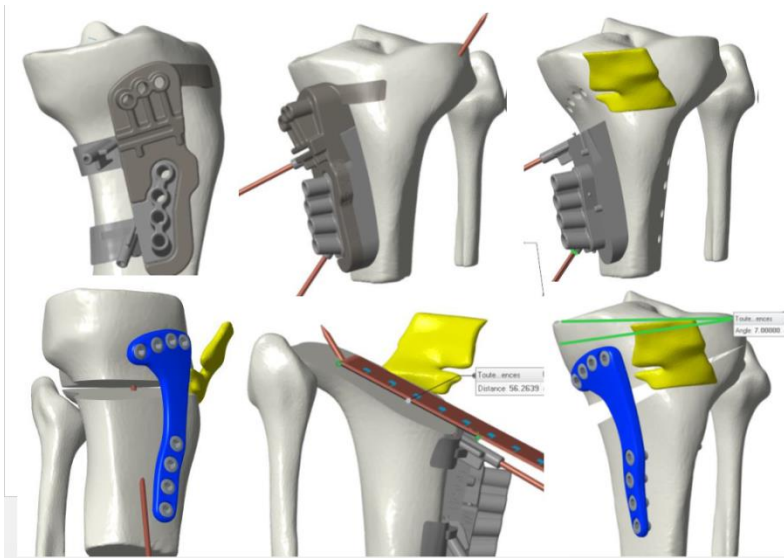
Another systematic review was performed by Slevin et al [36]. Of the 1421 MOWHTO included from the 22 studies, 647 underwent MOWHTO using allografts, 367 using synthetic material ( $\beta$ -TCP, hydroxyapatite or combination of both), in 208 no bone void filler and in 199 iliac crest autograft was used. With a mean follow up of 41 months (range 6 months-9 years) and mean gap of 9.9 mm, they demonstrated similar results in terms of union rates and loss of correction with or without the use of gap filler. This was irrespective of the type of filler used. They made an important observation that the gap size had direct correlation with the healing time. For gaps less than 9 mm, 90% of the osteotomies had healed within 12 weeks. Based on this observation, they recommended that standard osteotomies with gap around 10mm can be safely performed without the use of any void filler. They also recommended the use of autograft for osteotomy gaps larger than 10 mm. They observed that when bone grafting was needed, autograft bone provides higher rates of clinical and radiographic union. They also analyzed the deep infection and non-union rates. The infection rate was lowest 0.3% in the allograft group, 0.4% in the no filler group followed by 1.1% in both autograft and synthetic group. Non-union rate was lowest 0.4% in the no filler group followed by 0.5% in both autograft and allograft. It was highest 1.1% in the synthetic group. Based on these observations, the authors recommended that the standard MOWHTO procedure, with gaps smaller than 10 mm and a locking plate fixation, should be performed without bone grafting. Furthermore, they concluded that the use of synthetic void filler cannot be recommended in opening wedge high tibial osteotomy.

### **9) What is the place for PSI in MOWHTO and LCWDFO?**

**The consensus group recommends gaining experience with conventional techniques prior to adopting the use of PSI which may be a demanding technique.**

**The adoption of PSI for basic MOWHTO or LCWDFO is recommended for experienced surgeons who require familiarisation prior to using the technique for more demanding cases.**

**Nuanced presentations with the existence of multiplanar deformity (especially including elements such as torsion and intra-articular malunion) are ideal situations for the PSI in the hands of an experienced surgeon who has ascended the learning curve in this technique.**



#### Grade D

#### Literature review:

Recent improvements in CT analysis of deformity and 3D printing tools have allowed for the advancement of PSI. Extensive work by the Marseille group looking at safety studies considering the use of PSI in high tibial osteotomy have advocated its use in achieving optimal correction in a safe and reliable manner [24]. Further accuracy studies looking at multiplanar deformities confirm its use as a reliable and reproducible technique in achieving the desired correction [8, 24]. A clinical study by Chaoche et al demonstrated accurate coronal correction for varus malalignment with good functional outcomes at 2 years with no increase in complications [7]. Jacquet et al found a short learning curve in the use of PSI, with reduced use of fluoroscopy, operative time and surgeon anxiety levels [14].

#### References:

1. Agarwala S, Shah SB (2008) Staple versus locking compression plate fixation after lateral closing wedge high tibial osteotomy. *J Orthop Surg (Hong Kong)* SAGE PublicationsSage UK: London, England 16:303–307
2. Amzallag J, Pujol N, Maqdes A, Beaufile P, Judet T, Catonne Y (2013) Patellar height modification after high tibial osteotomy by either medial opening-wedge or lateral closing-wedge osteotomies. *Knee Surg Sports Traumatol Arthrosc* 21
3. Babis GC, An KN, Chao EY, Rand JA, Sim FH (2002) Double level osteotomy of the knee: a method to retain joint-line obliquity. Clinical results. *J Bone Joint Surg Am* 84-A:1380–1388
4. Bae DK, Song SJ, Kim HJ, Seo JW (2012) Change in limb length after high tibial osteotomy using computer-assisted surgery: a comparative study of closed- and open-wedge osteotomies. *Knee Surg Sports Traumatol Arthrosc*
5. Brinkman JM, Lobenhoffer P, Agneskirchner JD, Staubli AE, Wymenga AB, van Heerwaarden RJ (2008) Osteotomies around the knee: patient selection, stability of fixation and bone healing in high tibial osteotomies. *J Bone Joint Surg Br* 90:1548–1557

6. Brouwer RW, Bierma-Zeinstra SM, van Koeveringe AJ, Verhaar JA (2005) Patellar height and the inclination of the tibial plateau after high tibial osteotomy. The open versus the closed-wedge technique. *J Bone Joint Surg Br* 87:1227–1232
7. Chaouche S, Jacquet C, Fabre-Aubrespy M, Sharma A, Argenson J-N, Parratte S, Ollivier M (2019) Patient-specific cutting guides for open-wedge high tibial osteotomy: safety and accuracy analysis of a hundred patients continuous cohort. *Int Orthop Springer Berlin Heidelberg* 43:2757–2765
8. Donnez M, Ollivier M, Munier M, Berton P, Podgorski J-P, Chabrand P, Parratte S (2018) Are three-dimensional patient-specific cutting guides for open wedge high tibial osteotomy accurate? An in vitro study. *J Orthop Surg Res BioMed Central* 13:171–8
9. Erquicia J, Gelber PE, Perelli S, Ibañez F, Ibañez M, Pelfort X, Monllau JC (2019) Biplane opening wedge high tibial osteotomy with a distal tuberosity osteotomy, radiological and clinical analysis with minimum follow-up of 2 years. *J Exp Orthop SpringerOpen* 6:10–9
10. Gulagaci F, Jacquet C, Ehlinger M, Sharma A, Kley K, Wilson A, Parratte S, Ollivier M (2020) A protective hinge wire, intersecting the osteotomy plane, can reduce the occurrence of perioperative hinge fractures in medial opening wedge osteotomy. *Knee Surg Sports Traumatol Arthrosc Springer Berlin Heidelberg* 28:3173–3182
11. Han JH, Kim HJ, Song JG, Yang JH, Bhandare NN, Fernandez AR, Park HJ, Nha KW (2015) Is Bone Grafting Necessary in Opening Wedge High Tibial Osteotomy? A Meta-Analysis of Radiological Outcomes. *Knee Surg Relat Res* 27:207–220
12. Jacobi M, Wahl P, Jakob RP (2010) Avoiding intraoperative complications in open-wedge high tibial valgus osteotomy: technical advancement. *Knee Surg Sports Traumatol Arthrosc* 18:200–203
13. Jacquet C, Marret A, Myon R, Ehlinger M, Bahlouli N, Wilson A, Kley K, Rossi J-M, Parratte S, Ollivier M (2020) Adding a protective screw improves hinge's axial and torsional stability in High Tibial Osteotomy. *Clin Biomech (Bristol, Avon)* 74:96–102
14. Jacquet C, Sharma A, Fabre M, Ehlinger M, Argenson J-N, Parratte S, Ollivier M (2020) Patient-specific high-tibial osteotomy's 'cutting-guides' decrease operating time and the number of fluoroscopic images taken after a Brief Learning Curve. *Knee Surg Sports Traumatol Arthrosc Springer Berlin Heidelberg* 28:2854–2862
15. Jo H-S, Park J-S, Byun J-H, Lee Y-B, Choi Y-L, Cho S-H, Moon D-K, Lee S-H, Hwang S-C (2018) The effects of different hinge positions on posterior tibial slope in medial open-wedge high tibial osteotomy. *Knee Surg Sports Traumatol Arthrosc Springer Berlin Heidelberg* 26:1851–1858
16. Jung WH, Chun CW, Lee JH, Ha JH, Kim JH, Jeong JH (2013) Comparative study of medial opening-wedge high tibial osteotomy using 2 different implants. *Arthroscopy* 29:1063–1071
17. Kim JI, Kim BH, Lee KW, Lee O, Han HS, Lee S, Lee MC (2016) Lower Limb Length Discrepancy After High Tibial Osteotomy: Prospective Randomized Controlled Trial of Lateral Closing Versus Medial Opening Wedge Osteotomy. *Am J Sports Med SAGE PublicationsSage CA: Los Angeles, CA* 44:3095–3102
18. Lansdaal JR, Mouton T, Wascher DC, Demey G, Lustig S, Neyret P, Servien E (2017) Early weight bearing versus delayed weight bearing in medial opening wedge high tibial osteotomy: a randomized controlled trial. *Knee Surg Sports Traumatol Arthrosc Springer Berlin Heidelberg* 25:3670–3678
19. Lash NJ, Feller JA, Batty LM, Wasiak J, Richmond AK (2015) Bone grafts and bone substitutes for opening-wedge osteotomies of the knee: a systematic review. *Arthroscopy* 31:720–730
20. Luites JWH, Brinkman JM, Wymenga AB, van Heerwaarden RJ (2009) Fixation stability of opening- versus closing-wedge high tibial osteotomy: A RANDOMISED CLINICAL TRIAL USING RADIOSTEREOMETRY. *J Bone Joint Surg Br* 91-B:1459–1465

21. Lustig S, Scholes CJ, Costa AJ, Coolican MJ, Parker DA (2013) Different changes in slope between the medial and lateral tibial plateau after open-wedge high tibial osteotomy. *Knee Surg Sports Traumatol Arthrosc Springer-Verlag* 21:32–38
22. Magnussen RA, Lustig S, Demey G, Neyret P, Servien E (2011) The effect of medial opening and lateral closing high tibial osteotomy on leg length. *Am J Sports Med SAGE PublicationsSage CA: Los Angeles, CA* 39:1900–1905
23. Moon SW, Park SH, Lee BH, Oh M, Chang M, Ahn JH, Wang JH (2015) The Effect of Hinge Position on Posterior Tibial Slope in Medial Open-Wedge High Tibial Osteotomy. *Arthroscopy* 31:1128–1133
24. Munier M, Donnez M, Ollivier M, Flecher X, Chabrand P, Argenson JN, Parratte S (2017) Can three-dimensional patient-specific cutting guides be used to achieve optimal correction for high tibial osteotomy? Pilot study. *Orthop Traumatol Surg Res* 103:245–250
25. Nakamura R, Komatsu N, Fujita K, Kuroda K, Takahashi M, Omi R, Katsuki Y, Tsuchiya H (2017) Appropriate hinge position for prevention of unstable lateral hinge fracture in open wedge high tibial osteotomy. *Bone Joint J* 99-B:1313–1318
26. Nakayama H, Schröter S, Yamamoto C, Iseki T, Kanto R, Kurosaka K, Kambara S, Yoshiya S, Higa M (2018) Large correction in opening wedge high tibial osteotomy with resultant joint-line obliquity induces excessive shear stress on the articular cartilage. *Knee Surg Sports Traumatol Arthrosc Springer Berlin Heidelberg* 26:1873–1878
27. Nelissen EM, van Langelaan EJ, Nelissen RG (2010) Stability of medial opening wedge high tibial osteotomy: a failure analysis. *Int Orthop* 34:217–223
28. Nerhus TK, Ekland A, Solberg G, Sivertsen EA, Madsen JE, Heir S (2015) Radiological outcomes in a randomized trial comparing opening wedge and closing wedge techniques of high tibial osteotomy. *Knee Surg Sports Traumatol Arthrosc Springer Berlin Heidelberg* 25:910–917
29. Ogawa H, Matsumoto K, Akiyama H (2017) The prevention of a lateral hinge fracture as a complication of a medial opening wedge high tibial osteotomy: a case control study. *Bone Joint J* 99-B:887–893
30. Pape D, Kohn D, van Giffen N, Hoffmann A, Seil R, Lorbach O (2013) Differences in fixation stability between spacer plate and plate fixator following high tibial osteotomy. *Knee Surg Sports Traumatol Arthrosc* 21:82–89
31. Pape D, Lorbach O, Schmitz C, Busch LC, Van Giffen N, Seil R, Kohn DM (2010) Effect of a biplanar osteotomy on primary stability following high tibial osteotomy: a biomechanical cadaver study. *Knee Surg Sports Traumatol Arthrosc* 18:204–211
32. Park H, Kim HW, Kam JH, Lee DH (2017) Open Wedge High Tibial Osteotomy with Distal Tubercle Osteotomy Lessens Change in Patellar Position. *Biomed Res Int Hindawi* 2017:4636809
33. Reyle G, Lorbach O, Dikko Kaze A, Hoffmann A, Pape D (2017) [Prevention of lateral cortex fractures in open wedge high tibial osteotomies : The anteroposterior drill hole approach]. *Orthopade Springer Medizin* 46:610–616
34. Schroter S, Ateschrang A, Lowe W, Nakayama H, Stockle U, Ihle C (2015) Early full weight-bearing versus 6-week partial weight-bearing after open wedge high tibial osteotomy leads to earlier improvement of the clinical results: a prospective, randomised evaluation. *Knee Surg Sports Traumatol Arthrosc*
35. Schröter S, Gonser CE, Konstantinidis L, Helwig P, Albrecht D (2011) High Complication Rate After Biplanar Open Wedge High Tibial Osteotomy Stabilized With a New Spacer Plate (Position HTO Plate) Without Bone Substitute. *Arthroscopy: The Journal of Arthroscopic & Related Surgery* 27:644–652



36. Slevin O, Ayeni OR, Hinterwimmer S, Tischler T, Feucht MJ, Hirschmann MT (2016) The role of bone void fillers in medial opening wedge high tibial osteotomy: a systematic review. *Knee Surg Sports Traumatol Arthrosc* 24:3584–3598
37. Suh DW, Nha KW, Han S-B, Cheong K, Kyung BS (2021) Biplane Medial Opening-Wedge High Tibial Osteotomy Increases Posterior Tibial Slope more than Uniplane Osteotomy. *J Knee Surg* Thieme Medical Publishers, Inc.
38. van Heerwaarden R, Najfeld M, Brinkman M, Seil R, Madry H, Pape D (2012) Wedge volume and osteotomy surface depend on surgical technique for distal femoral osteotomy. *Knee Surg Sports Traumatol Arthrosc*
39. Wang JH, Bae JH, Lim HC, Shon WY, Kim CW, Cho JW (2009) Medial open wedge high tibial osteotomy: the effect of the cortical hinge on posterior tibial slope. *Am J Sports Med* 37:2411–2418
40. Yang JH, Lee S-H, Nathawat KS, Jeon S-H, Oh KJ (2013) The effect of biplane medial opening wedge high tibial osteotomy on patellofemoral joint indices. *Knee* 20:128–132





## **Section 4 : REHABILITATION**

- 1) How soon can full weight-bearing commence in MOWHTO / LCWDFO surgery?
- 2) When may patients return to work after osteotomy for the painful varus degenerative knee?
- 3) When may patients return to sports (RTS) after osteotomy for the painful varus degenerative knee?

MOWHTO      Medial opening wedge high tibial osteotomy

LCWDFO      Lateral closing wedge distal femoral osteotomy

### **1) How soon can full weight-bearing commence in MOWHTO, LCWHTO / LCWDFO surgery?**

Rehabilitation is the same after surgery in both MOWHTO and LCWHTO managed with plate fixators and is aimed at functional mobilisation and early full weightbearing, provided that soft tissue healing is not compromised.

#### **Grade B**

The biomechanical situation is less stable in distal femoral osteotomy compared to the high tibial osteotomy and therefore requires greater discretion with regards to weightbearing. A LCWDFO therefore requires a more cautious approach to weight-bearing than HTO. The consensus group agrees to a period of restricted weight-bearing followed by carefully monitored FWB at 6/52.

#### **Grade C**

An unstable configuration diagnosed either intra-operatively or post-operatively mandates a restriction of full weight-bearing and possible surgical augmentation of the fixation or both. This is further discussed in detail in the Complications section.

#### **Grade C**

##### **Literature review:**

In the Modern Early Years of osteotomy (1940-2000) it was conventional for high tibial osteotomy to be performed with little or no internal fixation and to be immobilized in plaster of Paris with very limited opportunity for a speedy recovery [24]. The advent of angle stable plates revolutionised routine rehabilitation for high tibial osteotomy and spawned several case-control studies [3][25] [5] regarding early full weight-bearing with long fixator plates.

2 randomized studies compared early full weight-bearing with a period of reduced or non-weight bearing [15][21] again using the same long fixator plate. The larger of these studies, a randomized prospective trial involved 120 patients assigned to 2 groups. Patients under the age of 18, showing



signs of previous or current infection and those with osteoporosis were excluded. The group performing early weight-bearing reached rehabilitation goals earlier than the reduced weight-bearing group although all participants achieved equally good results by 18 months. There were no recorded complications attributable to early weight-bearing in comparison with the reduced weight-bearing group.

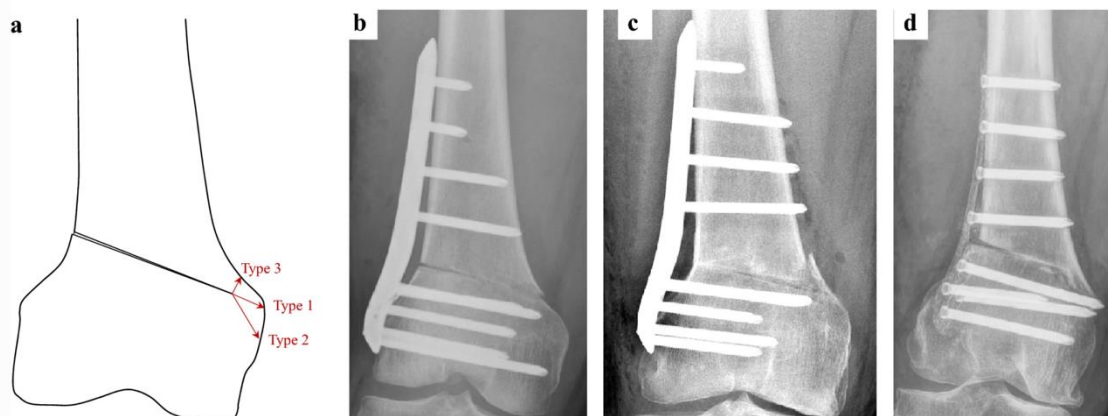
There are several studies in the literature reporting satisfactory outcome following an early weight-bearing regime which utilizes a long fixator plate [4][16][6]

The importance of the chosen implant to early weight-bearing has been investigated in the materials testing laboratory [1] and in a prospective non-randomised clinical study[19] which compared short spacer plates with long fixator plates. The short spacer plate, even if equipped with locking screws does not provide the same level of stability as the long fixator plate and requires a longer period of protected weight-bearing to achieve similar outcomes.

Further studies reflect other factors such as gap size, hinge fracture and smoking regarding a delay in introduction of full weight-bearing [22]. Furthermore, a rehabilitation regime is proposed in one series for eventuality of hinge fracture during or after the procedure [9] whereby toe-touch weight bearing is extended to 6 weeks when appropriate after hinge fracture.

Lateral closing wedge and indeed double level osteotomy which includes LCW-DFO have generally been treated with a more cautious post-operative weight-bearing regime and this is largely predicated by the high incidence of medial hinge fractures [20]. In this retrospective series of 79 cases there was a 48% incidence of medial cortical hinge fracture classified into one of three types(below). There was a 14% incidence of malunion associated with these hinge fractures. The standard regime for all these patients had been 20kg weight-bearing for 6 weeks. The authors suggest the use of a medial plate where diagnosis of hinge fracture is made intraoperatively or prolonged restriction of weight-bearing beyond 6 weeks if diagnosed post-operatively.

From: [Dislocated hinge fractures are associated with malunion after lateral closing wedge distal femoral osteotomy](#)



Morphology and classification of medial cortical hinge fractures. **a** Schematic illustration of the three different fracture types. **b** Type 1 fracture, extension of the osteotomy plane. **c** Type 2 fracture, distal to the osteotomy hinge. **d** Type 3 fracture, proximal to the osteotomy hinge

In a smaller study of 36 knees undergoing LCW-DFO there was an incidence of 30.6% medial hinge fracture [18](16). All patients underwent Xray and CT scan at 1 week post operatively. In the absence of hinge fracture the standard rehabilitation regime was 1/3 body weight at 3 weeks and full weight-bearing at 4 weeks. Those with hinge fractures were protected from weight bearing until callus formation was seen at the hinge fracture site.

## **2) When may patients return to work after osteotomy for the painful varus degenerative knee?**

**The steering committee recommends a discussion around intensity of the patient's employment with attention to the specific physical demands of a job. Each case will have its individual characteristics. Employment with low levels of physical stress may be compatible with return in under three months but higher levels of physical burden are likely to exceed 3 months). Mental health must be factored in, but patients can generally be reassured that they are likely to return to the same or higher level of work after surgery.**

### **Grade C**

#### **Literature review:**

Patients have high expectations of their osteotomy surgery and rate the return to work as the function of highest importance [8]. Furthermore 67% of patients expected to return to work without any limitations and 19% with only minor adaptations. This makes an informed discussion between surgeon and patient very important in the interest of proper informed consent. A study from 2005 [23] put fitness for return to work at 13.9 weeks following MOW-HTO. There was, however, no specification of the type of work involved and whether this factor would influence the time at which return to work was possible. The nature of work concerned was considered in a study where employment type was classified by a national association for work design, 'REHA', in Germany which graded work from 0 (work without special physical strain – eg desk work) up to 4 (physical jobs involving the carrying of over 50Kgs / climbing or working in stressed postures). The median duration of incapacity was 87 days (range 14 – 450) and 9.4% of patients were unable to return to work at the same level. Although the numbers were small a relationship was established with longer durations of incapacitation as the grade of work increased [23]

A group of 51 patients were studied and divided into three groups according to work intensity. Patients returned to work at a mean of 16.7 +/- 15.6 weeks and 93.8% of the patients returned at the pre-operative workload [11].

A systematic review from 2016 (19 studies, 1,189 patients) recorded 84.5% of patients overall returned to work within one year of high tibial osteotomy with 65.5% at equal or greater level than pre-operatively (4).

A smaller study of 38 patients yielded a return to work of 2.9+/-2.0 months in 35 patients (94.5%). The rate of RTW for sedentary, light, moderate and heavy duties were 87.5%, 100%, 100% and 93% respectively and the associated duration until RTW was 1.0 months, 1.1 months, 2.4 months and 3.3 months respectively (5) .

In the systematic review and meta-analysis of 2017 Hoorntje et al (6) demonstrated that in 7 studies 364 patients (85%) from 429 were able to return to work. In 6 studies a total of 276 patients were unable to work for 16.3 weeks. The study generally demonstrated their ability to return to work at the same or higher level than prior to surgery. Factors which delayed return to work were the greater intensity types of work and poor mental health. They did not demonstrate that specific device implants has any effect on return to work.

Being the main provider for the family income appears to be a good motivation for early return to work. [11]

### **3) When may patients return to sports (RTS) after osteotomy for the painful varus degenerative knee?**

**Patients may be counselled that RTS is highly likely after osteotomy provided that rehabilitation is completed. The majority can expect RTS within 6 months especially those practicing low impact activities. Most of the Patients will return to an higher level as compared to their preoperative period, however, patients are less likely to achieve return to sport at the level they enjoyed prior to the onset of symptoms.**

#### **Grade C**

#### **Literature review:**

Return to sport, in all studies, was deemed safe when the osteotomy had radiographically healed [13]

Patients return to sports after HTO at the same or a higher level within 1 year of surgery [2].

On the other hand, the weekly frequency of practicing certain sports decreases postoperatively [7] [12]. Return to play averages at 4.9 - 7.5 months. [14] [17]

Compared to HTO, DFO patients show a lower participation in high-impact activities (10 vs. 6%) and higher participation in intermediate-impact activities (32 vs. 39%). Also, half of the patients returned to sports within 15 weeks of the surgery and 71% returned within 6 months. [10] [13]

From the systematic review / meta-analysis of 2017 [16] overall RTS in 463 patients (16 studies) was 94% with 85% at pre symptomatic level. Patients participated in an average of 1.9 sports post-operatively including 58% low impact, 32% intermediate impact and 10% high impact.

#### **References:**

1. Agneskirchner JD, Freiling D, Hurschler C, Lobenhoffer P (2006) Primary stability of four different implants for opening wedge high tibial osteotomy. *Knee Surg Sports Traumatol Arthrosc Off J ESSKA* 14:291–300
2. Bastard C, Mirouse G, Potage D, Silbert H, Roubineau F, Hernigou P, Flouzat-Lachaniette C-H (2017) Return to sports and quality of life after high tibial osteotomy in patients under 60 years of age. *Orthop Traumatol Surg Res OTSR* 103:1189–1191
3. Brinkman J-M, Lobenhoffer P, Agneskirchner JD, Staubli AE, Wymenga AB, Van Heerwaarden RJ (2008) Osteotomies around the knee: patient selection, stability of fixation and bone healing in high tibial osteotomies. *J Bone Joint Surg Br British Editorial Society of Bone and Joint Surgery, London* 90:1548–1557
4. Brinkman J-M, Luites JWH, Wymenga AB, van Heerwaarden RJ (2010) Early full weight bearing is safe in open-wedge high tibial osteotomy. *Acta Orthop* 81:193–198
5. Brosset T, Pasquier G, Migaud H, Gougeon F (2011) Opening wedge high tibial osteotomy performed without filling the defect but with locking plate fixation (TomoFix™) and early weight-bearing: Prospective evaluation of bone union, precision and maintenance of correction in 51 cases. *Orthop Traumatol Surg Res* 97:705–711

6. Dares M, Putman S, Brosset T, Roumazeille T, Pasquier G, Migaud H (2018) Opening-wedge high tibial osteotomy performed with locking plate fixation (TomoFix) and early weight-bearing but without filling the defect. A concise follow-up note of 48 cases at 10 years' follow-up. *Orthop Traumatol Surg Res* 104:477–480
7. Faschingbauer M, Nelitz M, Urlaub S, Reichel H, Dornacher D (2015) Return to work and sporting activities after high tibial osteotomy. *Int Orthop* 39:1527–1534
8. Grünwald L, Angele P, Schröter S, Dickschas J, Harrer J, Hinterwimmer S, Feucht MJ, Preiss A, Minzlaff P, Saier T (2019) Patients' expectations of osteotomies around the knee are high regarding activities of daily living. *Knee Surg Sports Traumatol Arthrosc Off J ESSKA* 27:3022–3031
9. Gulagaci F, Jacquet C, Ehlinger M, Sharma A, Kley K, Wilson A, Parratte S, Ollivier M (2020) A protective hinge wire, intersecting the osteotomy plane, can reduce the occurrence of perioperative hinge fractures in medial opening wedge osteotomy. *Knee Surg Sports Traumatol Arthrosc* 28:3173–3182
10. Hoorntje A, van Ginneken BT, Kuijer PPFM, Koenraadt KLM, van Geenen RCI, Kerkhoffs GMMJ, van Heerwaarden RJ (2019) Eight respectively nine out of ten patients return to sport and work after distal femoral osteotomy. *Knee Surg Sports Traumatol Arthrosc Springer Berlin Heidelberg* 27:2345–2353
11. Hoorntje A, Kuijer PPFM, van Ginneken BT, Koenraadt KLM, van Geenen RCI, Kerkhoffs GMMJ, van Heerwaarden RJ (2019) Predictors of Return to Work After High Tibial Osteotomy: The Importance of Being a Breadwinner. *Orthop J Sports Med* 7:1–10
12. Hoorntje A, Kuijer PPFM, van Ginneken BT, Koenraadt KLM, van Geenen RCI, Kerkhoffs GMMJ, van Heerwaarden RJ (2019) Prognostic Factors for Return to Sport After High Tibial Osteotomy: A Directed Acyclic Graph Approach. *Am J Sports Med* 47:1854–1862
13. Hoorntje A, Witjes S, Kuijer PPFM, Koenraadt KLM, van Geenen RCI, Daams JG, Getgood A, Kerkhoffs GMMJ (2017) High Rates of Return to Sports Activities and Work After Osteotomies Around the Knee: A Systematic Review and Meta-Analysis. *Sports Med Springer International Publishing* 47:2219–2244
14. Jacquet C, Gulagaci F, Schmidt A, Pendse A, Parratte S, Argenson J-N, Ollivier M (2020) Opening wedge high tibial osteotomy allows better outcomes than unicompartmental knee arthroplasty in patients expecting to return to impact sports. *Knee Surg Sports Traumatol Arthrosc Off J ESSKA* 28:3849–3857
15. Lansdaal JR, Mouton T, Wascher DC, Demey G, Lustig S, Neyret P, Servien E (2017) Early weight bearing versus delayed weight bearing in medial opening wedge high tibial osteotomy: a randomized controlled trial. *Knee Surg Sports Traumatol Arthrosc* 25:3670–3678
16. Lee O-S, Ahn S, Lee YS (2017) Effect and safety of early weight-bearing on the outcome after open-wedge high tibial osteotomy: a systematic review and meta-analysis. *Arch Orthop Trauma Surg* 137:903–911
17. Liu JN, Agarwalla A, Garcia GH, Christian DR, Redondo ML, Yanke AB, Cole BJ (2019) Return to sport following isolated opening wedge high tibial osteotomy. *The Knee* 26:1306–1312
18. Nakayama H, Kanto R, Onishi S, Kambara S, Amai K, Yoshiya S, Schröter S, Tachibana T, Iseki T (2021) Hinge fracture in lateral closed-wedge distal femoral osteotomy in knees undergoing double-level osteotomy: assessment of postoperative change in rotational alignment using CT evaluation. *Knee Surg Sports Traumatol Arthrosc Off J ESSKA* 29:3337–3345
19. Pape D, Kohn D, van Giffen N, Hoffmann A, Seil R, Lorbach O (2013) Differences in fixation stability between spacer plate and plate fixator following high tibial osteotomy. *Knee Surg Sports Traumatol Arthrosc Off J ESSKA* 21:82–89



20. Rupp M-C, Winkler PW, Lutz PM, Irger M, Forkel P, Imhoff AB, Feucht MJ (2022) Dislocated hinge fractures are associated with malunion after lateral closing wedge distal femoral osteotomy. *Knee Surg Sports Traumatol Arthrosc Off J ESSKA* 30:982–992
21. Schröter S, Ateschrang A, Löwe W, Nakayama H, Stöckle U, Ihle C (2017) Early full weight-bearing versus 6-week partial weight-bearing after open wedge high tibial osteotomy leads to earlier improvement of the clinical results: a prospective, randomised evaluation. *Knee Surg Sports Traumatol Arthrosc Off J ESSKA* 25:325–332
22. Schröter S, Freude T, Kopp MM, Konstantinidis L, Döbele S, Stöckle U, Heerwaarden R van (2015) Smoking and Unstable Hinge Fractures Cause Delayed Gap Filling Irrespective of Early Weight Bearing After Open Wedge Osteotomy. *Arthroscopy Elsevier* 31:254–265
23. Schröter S, Mueller J, van Heerwaarden R, Lobenhoffer P, Stöckle U, Albrecht D (2013) Return to work and clinical outcome after open wedge HTO. *Knee Surg Sports Traumatol Arthrosc Off J ESSKA* 21:213–219
24. Smith JO, Wilson AJ, Thomas NP (2013) Osteotomy around the knee: evolution, principles and results. *Knee Surg Sports Traumatol Arthrosc Off J ESSKA* 21:3–22
25. Takeuchi R, Ishikawa H, Aratake M, Bito H, Saito I, Kumagai K, Akamatsu Y, Saito T (2009) Medial Opening Wedge High Tibial Osteotomy With Early Full Weight Bearing. *Arthroscopy Elsevier Inc, New York, NY* 25:46–53

## Section 5 : “COMPLICATIONS”

1. What is the definition of a complication in osteotomy around the knee?
2. What routine measures aid in prevention of soft tissue, nerve and vascular injury?
3. What is the definition of a hinge fracture and how should it be managed intra-operatively during MOWHTO?
4. What is the management of hinge fractures diagnosed post operatively?
5. When is early interventional surgery indicated for loss of correction?
6. What perioperative antibiotic prophylaxis is appropriate?
7. How is infection diagnosed and treated after osteotomy?
8. How is aseptic non-union diagnosed and treated after osteotomy?
9. Should metalware be removed after bone union?

### 1) What is the definition of a complication in osteotomy around the knee?

**A complication following osteotomy surgery may be defined as a significant deviation from the normal course of events during surgery or post-operatively. Complications may be subdivided into those requiring no treatment or non-operative treatment and those requiring surgical treatment according to Martin et al [52]. Failure to cure is not in itself a complication and plate removal may be regarded as a normal consequence of surgery.**

#### **Grade C**

	<b>Complication</b>
Class 1: No additional treatment required	Delayed wound healing
	Increased tibial slope $\geq 10^\circ$
	Undisplaced hinge fracture
	Haematoma
Class 2: Short-term nonoperative treatment required	Postoperative stiffness
	Limited hardware failure
	Delayed union
	Complex regional pain syndrome type 1
	Cellulitis
Class 3: Additional surgery or long-term nonoperative treatment required	Neurovascular injury
	Compartment syndrome
	Hardware failure with loss of

	correction
	Deep infection
	Aseptic non-union
	Intra-articular screw
	Complex regional pain syndrome type 2
	Displaced hinge fracture

3 classes of complication, derived from Martin et al [52]

**Literature review:**

The general definition of a surgical complication is any deviation from the normal post-operative course. If the original purpose of surgery has not been achieved, this is not to be considered as a complication but rather as a “failure to cure”. [21]

Current literature contains multiple studies focusing specifically on complications after osteotomy around the knee. [22, 52, 56, 96, 109] However, the precise definition of a complication is often lacking or unclear, ranging from benign findings to severe adverse events that require further medical and/or surgical interventions. Interestingly, in 2014 Martin et al. [52] classified complications and adverse events of opening wedge high tibial osteotomy (OWHTO) into different grades of severity based on the treatments required:

Class I: No additional treatment required.

Class II: Short-term non-operative treatment required.

Class III: Additional surgery or long-term non-operative treatment required.

By contrast, Woodacre et al. [106] stated in 2016 that complications of OWHTO are typically subcategorized into the following groups:

1. Persistence of medial compartment arthritic pain, or progression of lateral and retro-patella arthritis, requiring conversion to TKR.
2. Complications occurring from the resulting medial opening wedge bone defect.
3. Complications related to the implant used to stabilise the osteotomy.
4. General complications of surgery (infection, scar, deep vein thrombosis (DVT) etc.)

Furthermore, complications can also be broadly categorized as either patient-related or procedure-related, and to occur either intra-operatively or post-operatively, with the later further divided into early or late post-operative complications. [78]

Overall, the following complications of HTO can be found in literature:

	Complication
Intra-operatively	Hinge fracture
	Slope alteration
	Changes in patellar height (patella baja)
	Nerve injury
	Vascular injury



Early post-operative	Infection
	Deep vein thrombosis/pulmonary embolism
	Compartment syndrome
	Wound healing problems
	Complex regional pain syndrome (CRPS)
Late post-operative	Loss of Correction/hardware failure
	Delayed and non-union
	Hardware irritation

**Table 1.** Overview of different complications as a consequence of HTO found in literature.

More undesirable outcomes were described in the studies focusing on complications after osteotomy around the knee, besides the complications mentioned in table 1. Some studies indeed also report the number of patient with early regression of symptoms and/or early conversion to total knee arthroplasty. Following the definition of a complication, these patients should be categorized as “failure to cure” rather than as a complication per se.

It is interesting to note that in many studies hardware removal is not listed as a complication, unless screws or plate have broken[52, 86, 107]. Willey et al.[101] on the other hand described hardware pain explicitly as a “minor complication”. Other studies report hardware removal rates of 100% and seem to accept hardware removal after knee osteotomy as a part of the procedure and not as a complication.

In conclusion, although a formal definition of a complication after knee osteotomy might be lacking, classifying adverse events in three grades of severity based on the treatments required, as suggested by Martin et al. [52] seems useful for patients and clinicians faced with treatment options, as well as for streamlining future research efforts.

**Level of Evidence: 3**

## **2) What routine measures aid in prevention of soft tissue, nerve and vascular injury**

**A meticulous surgical technique combined with the careful use of retractors is essential in preventing injury to the neurovascular structures posteriorly and the patella tendon anteriorly during all osteotomy surgery . During HTO particular attention must be paid to the direction of the saw blade which after cutting the immediately visible cortical bone should be directed so that the long axis of the saw blade is angled at a minimum of 30 degrees anteriorly to the posterior cortex in MOWHTO and 40 degrees in LCWHTO. There is no scientifically proven evidence that knee flexion or extension protects the neurovascular bundle.**

### **Grade C**

#### **Literature review:**

Several neurovascular structures are at risk when performing high tibial osteotomy. The relative risk for each structure however largely depends on the osteotomy technique (opening wedge high tibial osteotomy, OWHTO or closing wedge high tibial osteotomy CWHTO) as explained below.

In general, a proper surgical technique for both procedures is desired to avoid neurovascular injuries. [50] A comprehensive review of the anatomical structures at risk during HTO surgery is provided below and measures to prevent each specific injury are discussed.

### **Nerve injury**

#### *Tibial nerve injury*

- Injury of the tibial nerve in OWHTO is only reported in 1 case report. This injury originated from protrusion of a temporary K-wire or lag screw through the posterolateral cortex. [83]

Although no evidence-based recommendation can be made, a proper surgical technique with avoiding excessive posterolateral protrusion of pins and screws can be a measure to avoid tibial nerve injury. Posterior plate position to avoid posterolateral direction of pins and screws also can be advised to minimize risk of tibial nerve injury.

#### *Peroneal nerve injury*

- Historically, peroneal injury is mainly a concern in LCWHTO, [22, 74] but more recently is also reported in MOWHTO. [43, 44] The origin of this injury is different in both techniques. In CWHTO it mostly is a result of the fibular neck osteotomy or proximal tibiofibular joint release and especially a branch to the extensor hallucis longus muscle is at risk as a result of its proximity to the bone. In MOWHTO it is considered as a result of lateral cortex perforation of pins or screws in the tibia distal to the osteotomy. [44]

No evidence-based recommendations for measures to avoid peroneal nerve injury were found. A proper surgical technique could result in a lower risk for these injuries. In LCWHTO a safe zone for fibular neck osteotomy, 20mm below the tip of the fibular head is suggested. In MOWHTO excessive lateral protrusion of pins and screws should be avoided, a more anteromedial plate position to avoid anterolateral direction of pins and screws can be advised to minimize the risk of peroneal nerve injuries.

- Tourniquet time over 60 minutes resulted in reversible peroneal nerve excitability during HTO surgery in 10 out of 18 patients in a perioperative surface EMG study. [103] This study suggests long tourniquet time induces temporary peroneal nerve injury, even though in all cases the effect was temporary and no data about postoperative peroneal nerve palsy is provided in this study.

No recommendations concerning the use and duration of a tourniquet can be made. The use of a tourniquet probably does not induce the risk for postoperative peroneal nerve injuries as every personal nerve palsy was reversible after deflating the tourniquet.

### **Vascular injury**

Even though popliteal and anterior tibial artery injuries after HTO are rare, they have been reported by multiple case reports in both MOWHTO [4, 6, 17, 81] and LCWHTO. [31, 73, 75, 91, 94]

- Precautious placement of a retractor is advised to prevent popliteal artery injury but its efficacy has only been studied in 1 publication supporting the use of a blunt retractor. [49]

No evidence-based recommendations can be made, but the use of a blunt retractor is intuitive and logical to protect against vascular injury during MOWHTO.

- In 6% an anatomical variance of the popliteal/anterior tibial artery has been shown. [32] In general the anterior tibial artery originates well below the level of the osteotomy and the popliteal artery runs over the popliteal muscle. In this anatomical variant the origin of the tibial

artery is more proximal, and it runs between the popliteal muscle and the periosteum of the posterior tibial cortex. This variant is more prone to vascular injury because of its intimate relation to the posterior tibial cortex and the risk of failing proper retractor placement under the artery, leaving it unprotected.

Placement of a blunt retractor under the popliteus muscle can fail to protect the popliteal/anterior tibial artery in the presence of an anatomical variant. Subperiosteal placement of the retractor most likely is safer to prevent vascular injury, although feasibility of subperiosteal retractor placement is unknown.

- Applying knee flexion during osteotomy is intuitively believed to move the popliteal artery further away from the posterior cortex of the tibia and therefore reducing the risk for popliteal artery injury. Studies report conflicting results on this topic as several studies showed an increased distance [84, 87, 110], while others showed a closer relation of the popliteal artery with knee flexion. [16, 82, 87, 112].

Applying knee flexion during osteotomy cannot be considered as a proper measure to prevent vascular injury during HTO.

- A recent study used three-dimensional knee models of 16 subjects to calculate a frontal plane safety index and maximum axial safety angle to minimize the risk for vascular injury.[16] When using a normal oscillating saw, a new 'frontal plane safety index' (an index representing the depth of the osteotomy) was developed and represented about 30% for closing wedge and 40% for opening wedge. [16] The maximum axial safety angle (an angle representing the direction of the sawblade in relation to the posterior cortex) was 40° for LCWHTO and 30° for MOWHTO. [16] A similar safety angle of 30° was found in a cadaveric study. [49]

A proper surgical technique with reducing posterior direction of the sawblade and reducing depth of the osteotomy is suggested to be an effective measure against vascular injury in HTO.

- Different surgical tools to complete the osteotomy exist. A standard oscillating saw, a tip-based "precision" oscillating saw, a reciprocating saw or chisels can be used. No studies comparing these surgical tools exist.
- Concerning surgical tools used to perform HTO, no recommendations to avoid neurovascular injuries can be made. Even though intuitively, a standard oscillating saw probably creates the biggest risk as a result of its wide and less manageable movements and more precise surgical tools probably are advisable.

**Level of evidence: 3**

### **3) What is the definition of a hinge fracture and how should it be managed intra-operatively during MOWHTO?**

**Hinge fractures are propagations of the osteotomy plane to the opposite (lateral) tibial cortex or to the tibial articular surface in the case of MOWHTO. These fractures have been classified by Takeuchi into types I, II and III (7). A type I fracture is the continuation of the osteotomy to an exit point on the lateral cortex above or at the proximal tibia-fibular joint (PTFJ). A type II fracture exits at the inferior aspect or distal to the PTFJ. A type III fracture exits into the joint producing a lateral**

plateau fracture. All hinge fractures (especially type II and III) may become unstable. Any displacement discovered intraoperatively under scrutiny by image intensifier must be addressed by reduction and fixation. A type I fracture may be satisfactorily reduced, and the hinge compressed by the selected medial plate fixator, but displaced type II and III fractures will require reduction and interfragmentary screw or small additional lateral locking plate fixation in addition to the osteotomy plate. The type II fracture is fixed at the lateral side and the type III by interfragmentary screws introduced from the medial side. A pre-emptive hinge reinforcement screw may be deployed in 'at risk' cases but the introduction of an apical drill hole does not reliably prevent hinge fractures especially in older patients and in larger corrections.

### Grade B

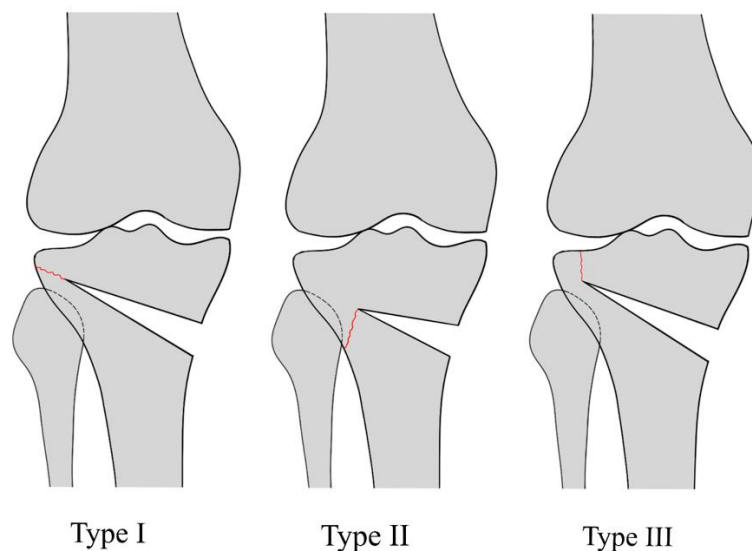


Figure 1: Takeuchi classification of hinge fractures: A type I fracture is the continuation of the osteotomy to an exit point on the lateral cortex above or at the proximal tibio-fibular joint (PTFJ). A type II fracture exits at the inferior aspect of or distal to the PTFJ. A type III fracture exits into the joint producing a lateral plateau fracture.

### Literature review:

Hinge fractures are unwanted fracture lines which propagate from the osteotomy apex during both opening- or closing-wedge high tibial osteotomies. [69] They are considered to be most frequent intra-operative complications of MOWHTO (in 13.8% of the cases [36]), even if they are not entirely preventable while correcting large deformities.

As a hinge fracture occurs as an extension of the artificial cut in any possible direction, Takeuchi et al. [93] described three different types of lateral cortical hinge fractures, with osteotomy site healing being influenced by these differences:



Type I: The fracture involves an extension of the osteotomy line laterally and is just proximal to or within the tibiofibular joint. In general, these are relatively stable because the soft tissue near the proximal tibiofibular joint (PTFJ) area is dense and solid.

Type II: The fracture reaches the distal portion of the PTFJ. This will result in external rotation of the two fragments with subsequent loss of correction and potential delayed union or non-union of the osteotomy site.

Type III: The fracture extends proximally, resulting in a lateral tibial plateau fracture. These are serious complications because the articular surface of the lateral compartment is damaged.

These last two types are unstable which decreases bone healing and leads to correction loss and non-union, thus, require specific postoperative treatments. [4, 6]

Several surgical modifications have been suggested to reduce the risk of a lateral hinge fracture in MOWHTO. Nakamura et al. [58] suggested that hinge fractures are maximally avoided when the apex of the osteotomy is within the proximal tibiofibular joint zone and when 10mm lateral cortex is left intact. Hinge fractures are also more likely to occur when the wedge size is over 10mm, but no significant relation is observed between the opening distance and the direction of the fracture. [62] Recently, a finite element analysis showed that using a 4mm apical drill hole centered at a distance of 10mm from the intact lateral cortex, maintains sufficient cortical bone and reduces the force required to open the osteotomy, thus making a more controlled distraction process.[11] Kaze et al performed mechanical testing which demonstrated that drilling a hole at the end of the osteotomy reduces the stresses in the lateral cortex and increases the critical opening angle prior to cracking of the opposite cortex in specimens with small correction angles. But the difference from having a drill hole or not is not so significant, especially for older patients. The ductility of the cortical bone is the decisive parameter for the critical opening angle

Finally the use of a K-wire intersecting the cutting plane at the theoretical lateral hinge location in MOWHTO, has been demonstrated to help preserve the lateral hinge during the opening of the osteotomy. [20]

**Level of evidence: 2**

#### **4) What is the management of hinge fractures diagnosed post-operatively?**

**Undisplaced type 1 hinge fractures may be managed by standard rehabilitation but undisplaced type 2 and 3 fractures should not be exposed to early post-operative full weight-bearing especially if no additional fixation or gap filling has been applied. Displacement of any hinge fracture on either of minimum two radiographic projections post operatively should be considered for operative intervention. If the displacement is considered minor an altered rehabilitation regime will be necessary until the osteotomy has united or considered stable.**

#### **Grade C**

##### **Literature review:**

An intact lateral hinge is crucial in providing adequate stability after opening wedge high tibial osteotomy (MOWHTO). Lateral hinge fractures (LHF) can indeed result in displacement, marked instability at the osteotomy site, and subsequent loss of correction with recurrent varus deformity [55, 78, 93], and should therefore be maximally avoided and handled correctly.[58, 63]

In order to determine the weight-bearing regimen for an OWHTO case complicated with LHF, the Takeuchi classification can be used. [59] Dense and solid connective tissues around the proximal tibiofibular joint (PTFJ) are an anatomical advantage for fracture healing in type 1 LHF.[93] The load from the fibula to the fracture plane during weight-bearing may even improve the healing of the

fracture. Therefore, type 1 fractures have been shown to exhibit a biomechanical effect similar to non-LHF [46, 92], and thus a normal rehabilitation program can be performed.

Type 2 fractures, on the contrary, are not loaded as the fracture exits below the PTFJ, which can lead to a delay in bony union. Type 3 fractures are unstable as the proximal medial fragment is only supported by the plate. This leads to instability of the knee joint and causes increased stress in the medial locking plate and screws, a decreased bone stress and thus a stress-shielding (not load sharing) effect. [46] Consequently, early full weight-bearing is not recommended for type 2 and 3 fractures if left untreated, [59] and thereby require a modified rehabilitation protocol. [60]

Chen et al. [15] suggested bilateral plating to restore mechanical stability in LHF using finite element analysis. The authors demonstrated that with double plating in type 2, and in particular type 3 fractures, a stress-shielding effect occurred, eventually leading to callus formation.

Another successful add-on in the salvage of LHF is the additional screw fixation from the lateral cortex to the medial tibial plateau, used for angular correction and for improving biomechanical stability. [27, 64] Yang et al. [108] verified that the use of a supplemental screw insertion technique can also be applied as a protective strategy to LHF.

A more stable construct in case of LHF can also be achieved by using allograft augmentation, showed in biomechanical studies with artificial bone. It also helps to prevent LHF postoperatively by reducing the valgus malrotation of the tibial head. [8, 9]

In conclusion, current literature supports the use of the Takeuchi classification in order to determine post-operative rehabilitation regimens in open wedge high tibial osteotomies complicated with a lateral hinge fracture (LHF). In order to further improve mechanical stability in type 2 and type 3 fractures during surgery, bilateral plating, additional lateral screw fixation and the use of allograft augmentation have been suggested.

**Level of evidence: 3**

### **5) In which situation is early interventional surgery indicated for loss of correction?**

**Loss of correction occurs in the case of MOWHTO where there is a measurable change in the MPTA, a displaced hinge fracture or broken implant prior to bony union. The use of locking plates dramatically decreases risk for post-operative loss of correction. The Interventional surgery for loss of correction should be gauged on a case-by-case basis. Determining the cause, degree and effects of failure will determine whether to treat conservatively or to revise the osteotomy.**

#### **Grade C**

#### **Literature review:**

Loss of intended correction towards recurrent varus is a potential complication that needs to be considered after both open and closing wedge high tibial osteotomy (HTO)[106]. As far as it has been described in the literature, the complication entity 'correction loss' is not well-defined and so it can range from progressive partial loss over months to complete early collapse of the osteotomy site due to hardware failure before bone healing has occurred. A benchmark literature review which considered 15 years of complications in osteotomy surgery, showed an overall correction loss ranging from 2.2 to 22.9% after HTO[106].

The chosen fixation device seems to be a critical factor in decreasing the risk of postoperative correction loss and has evolved over years[7, 37, 89, 90, 106]. In 2012, the use of a locking plate without bone graft was directly compared with a non-locking plate with bone graft with correction loss as primary outcome[67]. The study showed a correction loss of 0.3 +- 3.3° in the first group compared to a 2.0+-2.7° loss in the second group over a 2-year follow-up period. Correction loss was



mainly observed during the first year after surgery and reoperation was not performed for partial progressive correction loss[67]. Moreover, it was recommended to overcorrect the osteotomy with 2° of valgisation in order to counter the expected correction loss over time when using a non-locking plate[67]. On the other hand, locking plate devices have shown to give a consistent 1% early failure risk without the need for anticipating progressive correction loss[37, 90]. However, the timing of intervention after acute failure seems rather a case-specific matter. Nakamura et al. described a correction failure (closing-wedge, non-union) at 6 months after surgery which was immediately revised by an opening-wedge HTO[61]. Another case report by Brandao et al. showed successful revision osteotomy 3 months after initial surgery[25]. Reoperation was organized as soon as the failed osteotomy was diagnosed[25].

To summarize, early loss of correction after HTO has sporadically been published as a minor percentage in large case series or in the form of a single case report[25, 37, 57, 61, 89, 90, 106]. If correction loss is already described in clinical studies, the timing of revision is largely underreported. Although nowadays unfrequently observed when using locking plates, evidence-based guidelines are lacking regarding the timing and choice of surgical intervention if early correction failure after osteotomy would occur. It is hypothesized that arthroplasty can be considered when union has occurred while revision osteotomy is prioritized in non-union cases[61]. Overall, the underlying cause of correction loss should be well determined (hardware failure, non-union, smoking, obesity, intra-articular degeneration, infection) and guide further therapeutic options (revision osteotomy, external fixation, UKA, TKA) to optimize outcomes.

**Level of Evidence: 3**

## **6) What peri-operative antibiotic prophylaxis is appropriate?**

**Peri-operative antibiotics are strongly recommended for routine use in osteotomy surgery. No standard regimen has been proved to be superior to any other. Osteotomy surgery should be accompanied by a standard antibiotic prophylaxis regime as would be used for knee arthroplasty in the hospital involved.**

### **Grade D**

#### **Literature review:**

With regard to periprosthetic joint infection, it has been postulated that “administration of prophylactic antibiotics is probably one of the most important steps in the prevention of infection”[39]. By extension, it is widely agreed that the same is valid for high tibial osteotomy, although the extra-articular nature of this procedure might affect post-operative infection risk.

In general, most clinical series indeed report on the use of some sort of antibiotic prophylaxis when performing high tibial osteotomy (HTO), however further details on specific antibiotic drug, timing and/or dosing are most often lacking. [70][26][22][30][59][86] In a Swedish registry report from 2015, Cloxacillin was reported for 90 % of the surgeries, most commonly dosed using 2 grams in a single -shot before surgery, with a timing of 45-15 minutes before the start of the surgery being considered the most optimal timing. [97] Specific reports exist on the use of antibiotic prophylaxis with pin-using osteotomies using the so-called hemicallotasis technique.[98] In a comparative study, there were no differences between 3 days of administration of prophylactic antibiotics and one single dose. Due to the lack of standardisation of antibiotic prophylaxis in current practice, this variable could also explicitly not be included in a large national cohort analysis for risk factor identification with regard to surgical site infection after HTO.[48]





In conclusion, the administration of prophylactic antibiotics before HTO procedures can be considered the gold standard, although consensus is lacking on precise treatment regimens.

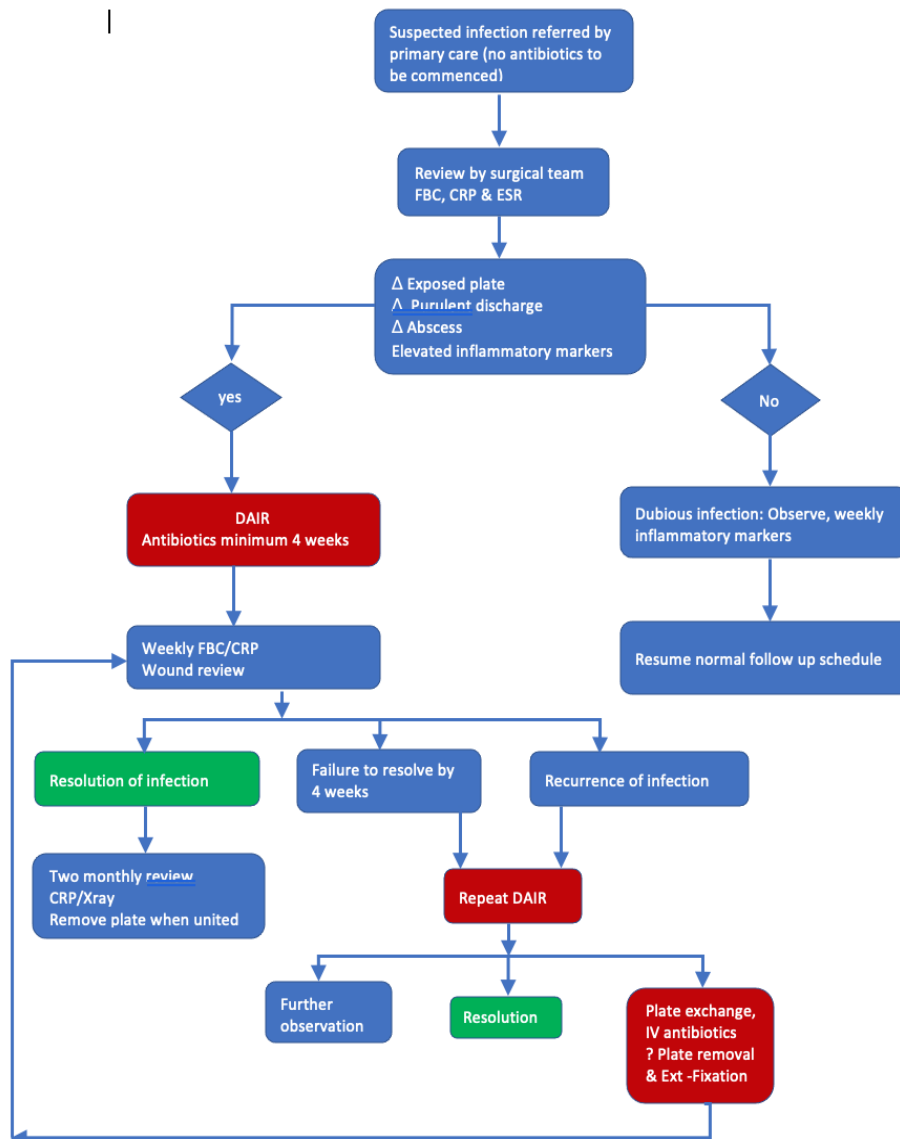
**Level of Evidence: 3**

### **7) How is infection diagnosed and treated in MOWHTO?**

**No diagnostic criteria exist to distinguish between superficial and deep infection which is specific to osteotomy. Because MOWHTO does not involve muscular or fascial coverage of the implant any suspected osteotomy infection must be regarded as potentially requiring surgical intervention because of the proximity of the implant to the skin surface. The consensus group recommends that antibiotics are not commenced prior to review by the surgical team. It is suggested the following algorithm is used for diagnosis and treatment of infection:**

**Grade C**

### Algorithm for suspected infection in HTO



FBC: Full blood count CRP: C reactive protein ESR: Erythrocyte sedimentation rate

DAIR: Debridement and implant retention IV: Intravenous

#### Literature review – diagnosis:

Clinical studies mentioning infection as a complication after knee osteotomy rarely mention the modalities/criteria for the diagnosis of infection. [70] [77] Even more, a systematic review on infections after high tibial osteotomy from 2012 does not report the diagnostic criteria of any of the 26 included studies.[1]

According to Martin et al., “deep infection” after HTO is defined by the association of local signs (skin redness, warmth, swelling, with or without sinus and purulent drainage) with elevated erythrocyte sedimentation rate and C-reactive protein ( $\geq 20$  mm/h and 10 mg/L, respectively).[52] In contrast, a combination of extensive wound secretion and a non-specified elevation of C-reactive

protein was rated as “deep infection” only when clinical conditions necessitated surgical revision surgery by Ferner et al.[26]

In conclusion, whereas diagnostic criteria for periprosthetic knee infection are clearly validated[66], current literature does not provide a consensus on the definition and diagnosis of infection after HTO.

**Level of evidence: 3**

#### **Literature review - treatment**

Several management options for treatment of infection after knee osteotomy have been reported in the literature.[1] Most studies distinguish “superficial” from “deep” infections, and treat both pathologies differently, although often no specification of the clinical difference between the two conditions is provided.[88]

In general “superficial” or “wound” infections are successfully treated by systemic antibiotics alone [3, 10, 23, 24], whereas “deep” infections involve surgical re-intervention. In 3 cases with a “late” manifestation of a “deep” infection, Reischl et al. suggest surgical debridement with concomitant hardware removal, while in 1 case with an early infection, hardware could be successfully retained after debridement.[70] For recurring early infection cases, Martin et al. proposed repeated irrigation and debridement procedures until hardware could be safely removed. [52] Staubli et al. report on a case where early plate removal for recurring infection led to a loss of correction of 3 degrees.[90] The management of an infected non-union indeed has been reported to be particularly challenging. Karatosun et al. suggest a two-stage procedure consisting of a first stage involving extensive debridement with removal of the hardware, followed by a total knee replacement with a long-stemmed tibial component, the latter being performed a month after normalization of inflammatory blood parameters. [47] Some of these cases have been successfully treated with the use of either calcium phosphate- or PMMA cement combined with external fixation.[42, 53, 80]

In conclusion, “superficial” infections can successfully be treated by antibiotics alone, while deep infections require surgical re-intervention with repeated irrigation/debridement procedures as long as bony union is obtained. Only then, plate removal can be safely performed in order to definitively cure the infection without the risk of loss of correction. The management of infected persistent non-unions remains cumbersome.

**Level of Evidence: 3**

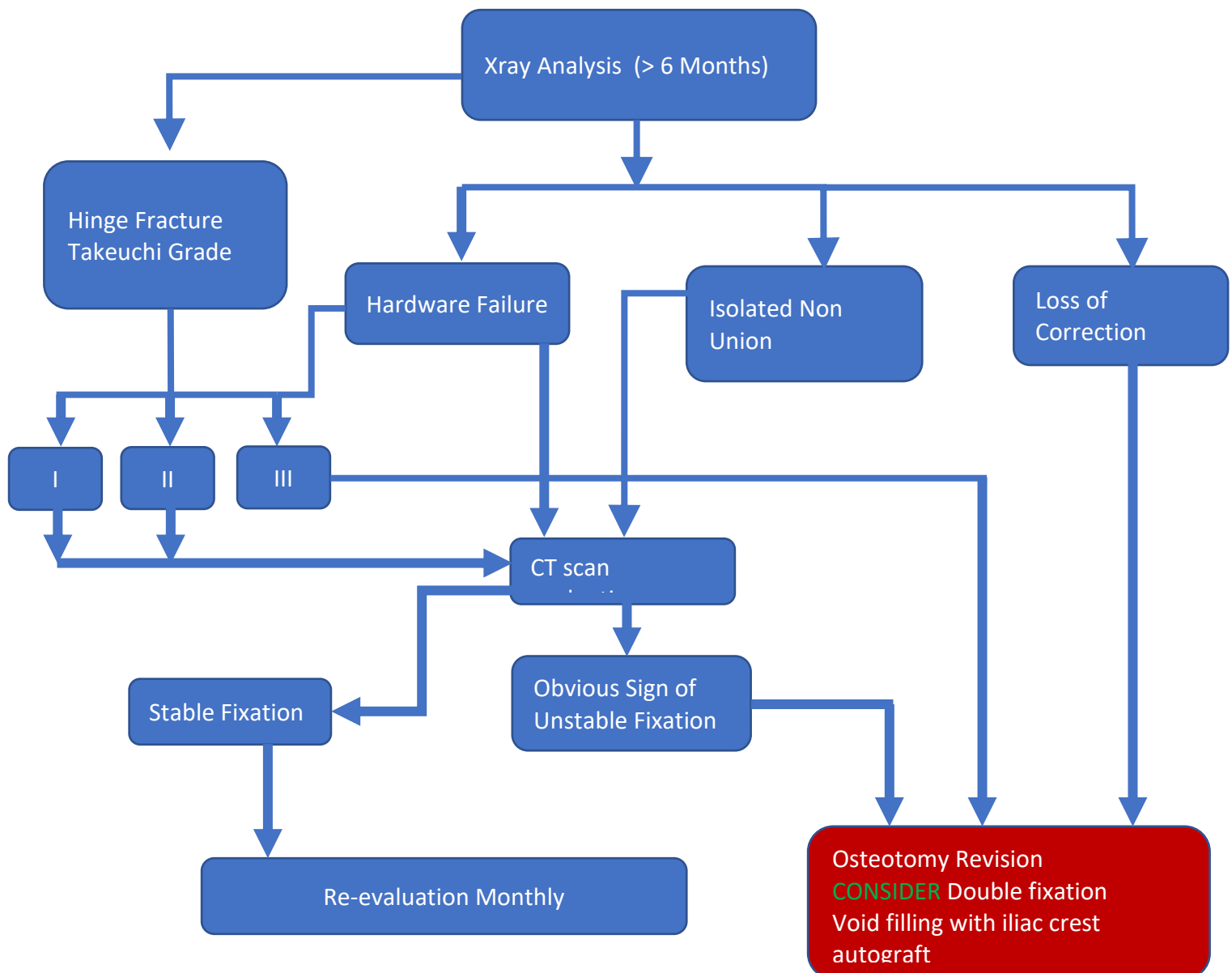
#### **8) How is aseptic non-union diagnosed and treated after osteotomy?**

**Aseptic non-union is a rare complication of MOWHTO even when performed without void filler. It is essential to combine clinical assessment with the radiological findings on a case-by-case basis. Obvious mechanical factors including loss of correction, hardware failure or lateral hinge fracture may confirm the diagnosis and should direct surgical management. Close clinical follow up is essential and CT scan may be helpful.**

**Rosteius et al. [72] described a spectrum of 4 operative treatment strategies in their series. The consensus group suggests the following algorithm for the diagnosis and treatment of aseptic non-union in MOWHTO**

**Grade C**

## Algorithm for Aseptic Non-Union in HTO



### Literature review – diagnosis:

Only a few studies describe non-union following high tibial osteotomy, and generally a low incidence is reported, ranging between 0 and 12.2 %. [42, 56, 85, 96, 99, 106] However, in most of these clinical series, a clear definition of delayed or non-union is not provided. Rosteius et al. [72] used a

combination of clinical characteristics (load-dependent pain at osteotomy site and pain on examination) together with radiological criteria. Non-union was radiologically diagnosed as absence of progressive bony healing 6 months after surgery, or earlier when in combination with loss of correction or hardware failure.

With cortical continuity being shown as the best single predictor of bone healing on an radiograph[65], Whelan et al.[100] developed the Radiographic Union Score for Tibial fractures (RUST) score in order to assess radiographic fracture healing. Van Houten et al. [42] then further expanded the use of this RUST score to high tibial osteotomy. Originally, the RUST assigns a score to each tibial cortex on plain radiographs: 1 point if a fracture line and no callus is visible; 2 points if a fracture line is visible and callus is visible; and 3 points if bridging callus and no evidence of a fracture line is visible. Because the authors considered scoring the anterior cortex on the lateral radiograph difficult for open wedge HTOs as a result of the fixation device's location, they altered the RUST by scoring the lateral and medial cortex on an AP radiograph and the posterior cortex on a lateral radiograph. Thus, the minimum score became 3 and the maximum 9. The modified RUST score at 6 weeks and 3 months was found a strong predictor for delayed or nonunion, although the authors "did not validate the modified RUST score for open wedge HTO".

Brosset et al.[12] used a different approach to evaluate bone healing after opening wedge HTO. They developed a radiological index to measure filling of the osteotomy gap, while dividing the triangular osteotomy gap in 5 zones each corresponding to 20% of the surface area. The osteotomy was considered stable if the site was 40% to 60% filled, in combination with the absence of pain during weight bearing. However, no measurement reliability tests were reported.

Van Hemert et al.[40] proposed another rating system to monitor bone healing after HTO, modified from an existing fracture healing system described by McKibbin[54]. They delineate five stages of bone remodeling while using a tricalcium phosphate bone filler based on standard AP and lateral radiographs.

In conclusion, different radiographic scoring systems have been described in literature in order to evaluate bone healing after HTO, but no gold standard exists. It seems appropriate to combine clinical characteristics together with radiological features of the absence of progressive bony healing when diagnosing non-union in knee osteotomy.

#### **Literature review – treatment:**

As non-union is a rare complication after HTO,[99] only rare reports exist on its preferred treatment. In general, the current literature reports on high healing rates for osteotomy non-union treatments, while applying a variety of different therapeutic strategies, both conservative and surgical.

In a study by Martin et al. looking at the adverse events following high tibial osteotomy, non-operative treatment with continued protected weight bearing regimen was able to achieve union in 7 out of 10 patients demonstrating absence of bony union at 6 months post-op.[52] On the other hand, Takeuchi et al. [93] report good results using an extra-corporal low-intensity pulsed ultrasound (LIPUS) device on cases with delayed bone union 3 months after knee osteotomy. It has indeed been theorized that the micromechanical strains produced by its pressure waves in biological tissues may result in biochemical events that regulate fracture healing.[18] Therefore, LIPUS has been shown to appear as an effective and safe treatment of delayed and non-unions in various fracture cases, with a healing rate ranging from 70% to 93% in different, nonrandomized, studies.[71] However, although promising given its non-invasive nature, extremely limited data exists on the use of LIPUS in knee osteotomy non-unions.

Most literature on the treatment HTO non-union reports on various surgical treatment modalities. Historically, before the advent of internal plate fixators, good results have been reported using



external fixation as a treatment for osteotomy non-union.[76, 95] However, the metaphyseal location of the non-union after high tibial osteotomy can make stable fixation problematic because the proximal fragment is small and difficult to control with most conventional methods of internal fixation. In order to overcome the problematic situation where the non-union was not amenable to traditional external or internal fixation due to the size of the proximal fragment and magnitude of deformity, Gillooly et al. more recently proposed a successful technique using an Ilizarov external fixator in five non-unions, although all patients had complications related to the external fixator (three superficial pin site infections, one broken wire, one sinus that required debridement).[33]

Recent history has witnessed the use of internal fixation as the treatment of choice for aseptic non-union. Most of the older studies beyond the scope of this review however described treatment with lateral closing-wedge osteotomies (CWHTO).[104] The healing rates and therapeutic strategies in these cases are less comparable to those of contemporary medial opening wedge HTO due to the difference in osteotomy type (no bony contact, osteotomy gap). Additionally, the use of cancellous bone grafting is handled differently.

With the recent advent of locking plates, opening wedge HTO (OWHTO) has become more popular than CWHTO over the past two decades [41], and therefore various recent reports describe revision procedures utilizing internal fixation as the treatment of choice for non-union cases after OWHTO. [72, 85, 106] Because of the presence of a bony gap in OWHTO non-unions, these small series uniformly advise autologous bone grafting from the iliac crest with or without revision osteosynthesis. Rosteius et al. [72] provide a particular helpful treatment algorithm for dealing with aseptic non-unions after OWHTO., four different treatment strategies are proposed. All cases underwent local debridement with autologous bone grafting, augmented with revision (medial) osteosynthesis in case of loss of correction/hardware failure and lateral augmentation plating in case of the presence of a lateral hinge fracture.

Orthobiologic agents have been demonstrated to be helpful in optimizing the biologic environment of a delayed union or non-union in various fracture treatments.[19, 28, 51] With regard to knee osteotomy, only one report augmented their revision procedures, which consisted of locking plate fixation and bone grafting, with either BMP-2, BMP-7, or PRP.[52]

Finally, if revision surgery of osteotomy non-union fails or is considered inappropriate, conversion to total knee arthroplasty (TKA) might be considered, as is more frequently proposed in acute or non-union settings of traumatic fractures around the knee in elderly patients with arthritic knees.[2, 105] However, with regard to knee osteotomy non-union, only a handful of cases have been described to date. [29, 111] Therefore, TKA should not be considered as a primary treatment for aseptic non-unions after HTO.

Overall, apart from early non-operative management, the recent literature suggests autologous bone grafting with or without revision osteosynthesis as the treatment of choice in treatment of aseptic non-unions after knee osteotomy. In specific indications, (multiplanar) external fixation or TKA can be considered.

### **9) Should metalware be removed after bone union?**

**Removal of hardware after bone union is reasonable if it is deemed to be symptomatic to a significant degree or if arthroplasty is considered likely to become necessary. Consideration must, however, be made of cost and risk of complications from a further surgical procedure. As such, hardware removal should not be considered as a routine procedure.**

#### **Grade C**

**Literature review:**

In general, current literature is clearly lacking exact data on the incidence of hardware-related pain and discomfort after knee osteotomy. Nevertheless, hardware removal is very often performed after bony union, with prevalence up to 97% and 100% in some series.[35, 38, 107]

In view of these high numbers, it's interesting to note that in most papers removal of hardware is not listed as a complication, unless screws or plate have broken[52, 86, 107]. Willey et al.[101]described hardware pain explicitly as a minor complication (in 9/78 patients). Most authors seem to accept hardware removal after knee osteotomy as “part of the game”.

Optimal timing for plate removal in symptomatic patients can be questioned. Goshima et al.[34] suggest that plates in OWHTO can be safely removed without loss of correction when the posterior cortex bone union reaches the osteotomy gap center even if the total gap is incompletely filled.

No specific data on clinical results after hardware removal in osteotomy patients could be found, but in contrast, the literature is far more comprehensive regarding post-traumatic cases.

For instance, Williams et al. [102] reported in a prospective study implant removal in trauma cases presents significant improvement in dysfunction in both the upper and lower extremity with rare complications. Symptomatic hardware complaints are well described in ankle and distal tibia fractures[13, 45] with some authors even suggesting systematic removal of the hardware in asymptomatic patients[45]. A recent review[68] on elective removal vs. retainment of hardware after osteosynthesis in asymptomatic trauma and osteotomy patients concluded that insufficient data was found to allow a meaningful assessment of the effectiveness of elective hardware removal. Importantly, it should be kept in mind that high rates of complications have been reported with hardware removal below the knee, especially with regard to postoperative wound infections (12.2%).[5] Technical difficulties during the removal of locking screws from compression plates have been estimated as high as 20.1 %.[79]

Finally the decision to remove hardware has significant economic implications, including the costs of the procedure as well as possible work time lost for post-operative recovery.[14]

In conclusion, once bony union is achieved, removal of the hardware is often performed after knee osteotomy, especially if significant hardware related complaints are present. Complications as infection and technical issues are not uncommon, and there is a lack of data on clinical results with regard to hardware removal after knee osteotomy.

### **Level of Evidence: 3**

1. Anagnostakos K, Mosser P, Kohn D (2013) Infections after high tibial osteotomy. *Knee Surgery, Sport Traumatol Arthrosc* 21:161–169
2. Anderson SP, Matthews LS, Kaufer H (1990) Treatment of juxtaarticular nonunion fractures at the knee with long-stem total knee arthroplasty. *Clin Orthop Relat Res* 104–109
3. Asik M, Sen C, Kilic B, Goksan SB, Ciftci F, Taser OF (2006) High tibial osteotomy with Puddu plate for the treatment of varus gonarthrosis. *Knee Surgery, Sport Traumatol Arthrosc* 14:948–954
4. Attinger MC, Behrend H, Jost B (2014) Complete rupture of the popliteal artery complicating high tibial osteotomy. *J Orthop* 11:192–196
5. Backes M, Schep NW., Luitse JS., Goslings J., Schepers T (2015) High Rates of Postoperative Wound Infection Following Elective Implant Removal. *Open Orthop J* 9:418–421
6. Bartoli MA, Lerussi GB, Gulino R, Schroeder M, Branchereau A (2010) False aneurysm at the origin of the anterior tibial artery after opening wedge osteotomy. *Vascular* 18:45–48
7. Van Den Bekero MPJ, Patt TW, Kleinhout MY, Van Der Vis HM, Rob Albers GH (2008) Early



- Complications After High Tibial Osteotomy. *J Knee Surg* 21:68–74
8. Belsey J, Dikko Kaze A, Jobson S, Faulkner J, Maas S, Khakha R, Wilson AJ, Pape D (2019) Graft materials provide greater static strength to medial opening wedge high tibial osteotomy than when no graft is included. *J Exp Orthop Journal of Experimental Orthopaedics* 6:13
  9. Belsey J, Kaze AD, Jobson S, Faulkner J, Maas S, Khakha R, Pape D, Wilson AJ (2019) The biomechanical effects of allograft wedges used for large corrections during medial opening wedge high tibial osteotomy. *PLoS One* 14:1–14
  10. Billings A, Scott DF, Camargo MP, Hofmann AA (2000) High tibial osteotomy with a calibrated osteotomy guide, rigid internal fixation, and early motion: Long-term follow-up. *J Bone Jt Surg - Ser A* 82:70–79
  11. Bostrom A, Amin A, Macpherson G, Pankaj P, Scott C (2020) Hinge location and apical drill holes in opening wedge high tibial osteotomy: A finite element analysis. *Knee* 27:S10–S11
  12. Brosset T, Pasquier G, Migaud H, Gougeon F (2011) Opening wedge high tibial osteotomy performed without filling the defect but with locking plate fixation (Tomofix™) and early weight-bearing: Prospective evaluation of bone union, precision and maintenance of correction in 51 cases. *Orthop Traumatol Surg Res* 97:705–711
  13. Brown OL, Dirschl DR, Obremskey WT (2001) Incidence of hardware-related pain and its effect on functional outcomes after open reduction and internal fixation of ankle fractures. *J Orthop Trauma J Orthop Trauma* 15:271–274
  14. Busam ML, Esther RJ, Obremskey WT (2006) Hardware removal: Indications and expectations. *J Am Acad Orthop Surg American Association of Orthopaedic Surgeons* 14:113–120
  15. Chen YN, Chuang CH, Yang TH, Chang CW, Li CT, Chang CJ, Chang CH (2020) Computational comparison of different plating strategies in medial open-wedge high tibial osteotomy with lateral hinge fractures. *J Orthop Surg Res* 15:409
  16. Choi CH, Lee WS, Jung M, Moon HS, Lee YH, Oh J, Kim SJ, Kim SH (2020) Adequate protection rather than knee flexion prevents popliteal vascular injury during high tibial osteotomy: analysis of three-dimensional knee models in relation to knee flexion and osteotomy techniques. *Knee Surgery, Sport Traumatol Arthrosc Springer* 28:1425–1435
  17. Chun KC, So BJ, Kang HT, Chun C-H (2018) Pseudoaneurysm Formation due to Popliteal Artery Injury Caused by Drilling during Medial Opening Wedge High Tibial Osteotomy. *Knee Surg Relat Res* 30:364–368
  18. Claes L, Willie B (2007) The enhancement of bone regeneration by ultrasound. *Prog Biophys Mol Biol Prog Biophys Mol Biol* 93:384–398
  19. Desai P, Hasan SM, Zambrana L, Hegde V, Saleh A, Cohn MR, Lane JM (2015) Bone Mesenchymal Stem Cells with Growth Factors Successfully Treat Nonunions and Delayed Unions. *HSS J* 11:104–111
  20. Dessyn E, Sharma A, Donnez M, Chabrand P, Ehlinger M, Argenson JN, Parratte S, Ollivier M (2020) Adding a protective K-wire during opening high tibial osteotomy increases lateral hinge resistance to fracture. *Knee Surgery, Sport Traumatol Arthrosc* 28:751–758
  21. Dindo D, Demartines N, Clavien PA (2004) Classification of surgical complications: A new proposal with evaluation in a cohort of 6336 patients and results of a survey. *Ann Surg* 240:205–213
  22. Duivenvoorden T, Van Diggele · P, Reijman · M, Bos · P K, Van Egmond · J, Bierma-Zeinstra · S M A, Verhaar JAN (2017) Adverse events and survival after closing- and opening-wedge high tibial osteotomy: a comparative study of 412 patients. *Knee Surg Sport Traumatol Arthrosc* 25:895–901
  23. Efe T, Ahmed G, Heyse TJ, Boudriot U, Timmesfeld N, Fuchs-Winkelmann S, Ishaque B, Lakemeier S, Schofer MD (2011) Closing-wedge high tibial osteotomy: Survival and risk factor

- analysis at long-term follow up. *BMC Musculoskelet Disord BioMed Central* 12:46
24. El-Assal MA, Khalifa YE, Abdel-Hamid MM, Said HG, Bakr HMA (2010) Opening-wedge high tibial osteotomy without bone graft. *Knee Surgery, Sport Traumatol Arthrosc Springer* 18:961–966
  25. Fernando Colen Milagres B, Renan Alves R, Rafael Zambelli P (2018) Failed High tibial osteotomy. *AAOS Compr Orthop Rev* 2 1:160–166
  26. Ferner F, Lutter C, Schubert I, Schenke M, Strecker W, Dickschas J (2021) Perioperative complications in osteotomies around the knee: a study in 858 cases. *Arch Orthop Trauma Surg* 142:769–775
  27. de Freitas RL, Rosa RC, Paccola CAJ, Shimano AC, Kfuri M (2010) Open wedge tibial osteotomy: Biomechanical relevance of the opposite cortex for the fixation method. *Acta Ortop Bras* 18:224–229
  28. Friedlaender GE, Perry CR, Cole JD, Cook SD, Cierny G, Muschler GF, Zych GA, Calhoun JH, LaForte AJ, Yin S (2001) Osteogenic protein-1 (bone morphogenetic protein-7) in the treatment of tibial nonunions. *J Bone Joint Surg Am NIH Public Access* 83 A Suppl:S151
  29. Gandhi R, Alomran A, Mahomed N (2008) Bilateral non-union of high tibial osteotomies treated by total knee arthroplasty: A case report. *Knee* 15:242–245
  30. Van Genechten W, Van den Bempt M, Van Tilborg W, Bartholomeeusen S, Van Den Bogaert G, Claes T, Claes S (2020) Structural allograft impaction enables fast rehabilitation in opening-wedge high tibial osteotomy: a consecutive case series with one year follow-up. *Knee Surgery, Sport Traumatol Arthrosc* 28:3747–3757
  31. Georgoulis AD, Makris CA, Papageorgiou CD, Moebius UG, Xenakis T, Soucacos PN (1999) Nerve and vessel injuries during high tibial osteotomy combined with distal fibular osteotomy: A clinically relevant anatomic study. *Knee Surgery, Sport Traumatol Arthrosc* 7:15–19
  32. Gerich T, Lens V, Seil R, Pape D (2014) Open wedge osteotomy of the tibial head: Management of vascular complications. *Orthopade* 43:1008–1015
  33. Gillooly JJ, Tilkeridis K, Simonis RB, Monsell F (2012) The treatment of high tibial osteotomy non-union with the Ilizarov external fixator. *Strateg Trauma Limb Reconstr* 7:93–97
  34. Goshima K, Sawaguchi T, Takeshi, Shigemoto K, Iwai S, Fujita K, Kataoka T, Tomoyuki (2020) Plate removal without loss of correction after open-wedge high tibial osteotomy is possible when posterior cortex bone union reaches osteotomy gap center even in incompletely filled gaps. *Sport Traumatol Arthrosc* 28:1827–1834
  35. Goshima K, Sawaguchi T, Shigemoto K, Iwai S, Nakanishi A, Inoue D, Shima Y (2019) Large opening gaps, unstable hinge fractures, and osteotomy line below the safe zone cause delayed bone healing after open-wedge high tibial osteotomy. *Knee Surgery, Sport Traumatol Arthrosc* 27:1291–1298
  36. Han SB, Choi JH, Mahajan A, Shin YS (2019) Incidence and Predictors of Lateral Hinge Fractures Following Medial Opening-Wedge High Tibial Osteotomy Using Locking Plate System: Better Performance of Computed Tomography Scans. *J Arthroplasty* 34:846–851
  37. Han SB, In Y, Oh KJ, Song KY, Yun ST, Jang KM (2019) Complications Associated With Medial Opening-Wedge High Tibial Osteotomy Using a Locking Plate: A Multicenter Study. *J Arthroplasty* 34:439–445
  38. Hartz C, Wischatta R, Klostermeier E, Paetzold M, Gerlach K, Pries F (2019) Plate-related results of opening wedge high tibial osteotomy with a carbon fiber reinforced poly-ether-ether-ketone (CF-PEEK) plate fixation: A retrospective case series of 346 knees. *J Orthop Surg Res* 14:1–9
  39. Heller S, Rezapoor M, Parvizi J (2016) Minimising the risk of infection. *Bone Joint J British Editorial Society of Bone & Joint Surgery* 98-B:18–22

40. Van Hemert WLW, Willems K, Anderson PG, Van Heerwaarden RJ, Wymenga AB (2004) Tricalcium phosphate granules or rigid wedge preforms in open wedge high tibial osteotomy: A radiological study with a new evaluation system. *Knee* 11:451–456
41. Hoell S, Suttmoeller J, Stoll V, Fuchs S, Gosheger G (2005) The high tibial osteotomy, open versus closed wedge, a comparison of methods in 108 patients. *Arch Orthop Trauma Surg* Springer 125:638–643
42. Van Houten AH, Heesterbeek PJC, Van Heerwaarden RJ, Van Tienen TG, Wymenga AB (2014) Medial open wedge high tibial osteotomy: Can delayed or nonunion be predicted? *Clin Orthop Relat Res* 472:1217–1223
43. Itou J, Itoh M, Maruki C, Tajimi T, So T, Kuwashima U, Okazaki K (2020) Deep peroneal nerve has a potential risk of injury during open-wedge high tibial osteotomy. *Knee Surgery, Sport Traumatol Arthrosc* 28:1372–1379
44. Jeong JH, Chang MC, Lee SA (2019) Deep peroneal nerve palsy after opening wedge high tibial osteotomy: A case report. *Medicine (Baltimore)* 98:e16253
45. Jung HG, Kim J II, Park JY, Park JT, Eom JS, Lee DO (2016) Is Hardware Removal Recommended after Ankle Fracture Repair? *Biomed Res Int* 2016:1–7
46. Kang KT, Koh YG, Lee JA, Lee JJ, Kwon SK (2020) Biomechanical effect of a lateral hinge fracture for a medial opening wedge high tibial osteotomy: finite element study. *J Orthop Surg Res* 15:63
47. Karatosun V, Demir T, Unver B, Gunal I (2011) A brief report on managing infected nonunion of a high tibial osteotomy in two stages. *J Bone Joint Surg Br The British Editorial Society of Bone and Joint Surgery* 93-B:904–906
48. Kawata M, Jo T, Taketomi S, Inui H, Yamagami R, Matsui H, Fushimi K, Yasunaga H, Tanaka S (2021) Type of bone graft and primary diagnosis were associated with nosocomial surgical site infection after high tibial osteotomy: analysis of a national database. *Knee Surgery, Sport Traumatol Arthrosc* 29:429–436
49. Kim J, Allaire R, Harner CD (2010) Vascular Safety during High Tibial Osteotomy. *Am J Sports Med* 38:810–815
50. Madry H, Goebel L, Hoffmann A, Dück K, Gerich T, Seil R, Tschernig T, Pape D (2017) Surgical anatomy of medial open-wedge high tibial osteotomy: crucial steps and pitfalls. *Knee Surgery, Sport Traumatol Arthrosc* 25:3661–3669
51. Malhotra R, Kumar V, Garg B, Singh R, Jain V, Coshic P, Chatterjee K (2015) Role of autologous platelet-rich plasma in treatment of long-bone nonunions: a prospective study. *Musculoskelet Surg* 99:243–248
52. Martin R, Birmingham TB, Willits K, Litchfield R, Lebel ME, Giffin JR (2014) Adverse event rates and classifications in medial opening wedge high tibial osteotomy. *Am J Sports Med* 42:1118–1126
53. McHale KA, Ross AE (2004) Treatment of infected tibial nonunions with debridement, antibiotic beads, and the Ilizarov method. *Mil Med Association of Military Surgeons of the US* 169:728–734
54. McKibbin B (1978) The biology of fracture healing in long bones. *J Bone Jt Surg - Ser B* 60 B:150–162
55. Miller BS, Dorsey WOP, Bryant CR, Austin JC (2005) The effect of lateral cortex disruption and repair on the stability of the medial opening wedge high tibial osteotomy. *Am J Sports Med* 33:1552–1557
56. Miller BS, Downie B, McDonough EB, Wojtys EM (2009) Complications After Medial Opening Wedge High Tibial Osteotomy. *Arthrosc - J Arthrosc Relat Surg* 25:639–646
57. Morris J, Grant A, Kulkarni R, Doma K, Harris A, Hazratwala K (2019) Early results of medial opening wedge high tibial osteotomy using an intraosseous implant with accelerated

- rehabilitation. *Eur J Orthop Surg Traumatol* 29:147–156
58. Nakamura R, Komatsu N, Fujita K, Kuroda K, Takahashi M, Omi R, Katsuki Y, Tsuchiya H (2017) Appropriate hinge position for prevention of unstable lateral hinge fracture in open wedge high tibial osteotomy. *Bone Jt J* 99B:1313–1318
  59. Nakamura R, Komatsu N, Fujita K, Nishimura H, Katsuki Y (2016) The validity of the classification for lateral hinge fractures in open wedge high tibial osteotomy. *Osteoarthr Cartil* 24:S515–S516
  60. Nakamura R, Komatsu N, Murao T, Okamoto Y, Nakamura S, Fujita K, Nishimura H, Katsuki Y (2015) The validity of the classification for lateral hinge fractures in open wedge high tibial osteotomy. *Bone Jt J* 97-B:1226–1231
  61. Nakamura R, Nishimura H, Katsuki Y (2017) Re-correction osteotomy with osteophyte graft for correction loss with non-union after high tibial osteotomy. *BMJ Case Rep* 2017:1–4
  62. Nelissen EM, Van Langelaan EJ, Nelissen RGHH (2010) Stability of medial opening wedge high tibial osteotomy: A failure analysis. *Int Orthop* 34:217–223
  63. Ogawa H, Matsumoto K, Akiyama H (2017) The prevention of a lateral hinge fracture as a complication of a medial opening wedge high tibial osteotomy. *Bone Jt J British Editorial Society of Bone and Joint Surgery* 99B:887–893
  64. Paccola CAJ, Fogagnolo F (2005) Open-wedge high tibial osteotomy: A technical trick to avoid loss of reduction of the opposite cortex. *Knee Surgery, Sport Traumatol Arthrosc* 13:19–22
  65. Panjabi MM, Walter SD, Karuda M, White AA, Lawson JP (1985) Correlations of radiographic analysis of healing fractures with strength: A statistical analysis of experimental osteotomies. *J Orthop Res* 3:212–218
  66. Parvizi J, Tan TL, Goswami K, Higuera C, Della Valle C, Chen AF, Shohat N (2018) The 2018 Definition of Periprosthetic Hip and Knee Infection: An Evidence-Based and Validated Criteria. *J Arthroplasty* 33:1309-1314.e2
  67. Pornrattanamaneewong C, Harnroongroj T, Chareancholvanich K (2012) Loss of correction after medial opening wedge high tibial osteotomy: a comparison of locking plates without bone grafts and non-locking compression plates with bone grafts. *J Med Assoc Thai* 95 Suppl 9:21–28
  68. Prediger B, Mathes T, Probst C, Pieper D (2020) Elective removal vs. retaining of hardware after osteosynthesis in asymptomatic patients—a scoping review. *Syst. Rev.* 9:225
  69. Van Raaij TM, Brouwer RW, De Vlieger R, Reijman M, Verhaar JAN (2008) Opposite cortical fracture in high tibial osteotomy: Lateral closing compared to the medial opening-wedge technique. *Acta Orthop* 79:508–514
  70. Reischl N, Wahl P, Jacobi M, Clerc S, Gautier E, Jakob RP (2009) Infections after high tibial open wedge osteotomy: a case control study. *Arch Orthop Trauma Surg* 129:1483–1487
  71. Romano CL, Romano D, Logoluso N (2009) Low-Intensity Pulsed Ultrasound for the Treatment of Bone Delayed Union or Nonunion: A Review. *Ultrasound Med Biol* 35:529–536
  72. Rosteius T, Rausch V, Lotzien S, Seybold D, Schildhauer TA, Geßmann J (2021) Treatment of aseptic nonunion after medial opening-wedge high tibial osteotomy. *Eur J Orthop Surg Traumatol* 31:755–762
  73. Rubens F, Wellington JL, Bouchard AG (1990) Popliteal artery injury after tibial osteotomy: Report of two cases. *Can J Surg Can J Surg* 33:294–297
  74. Satku K, Kumar VP (1993) Palsy of the deep peroneal nerve after proximal tibial osteotomy. An anatomical study. *J Bone Joint Surg Am* 75:1736
  75. Sawant MR, Ireland J (2001) Pseudo-aneurysm of the anterior tibial artery complicating high tibial osteotomy - A case report. *Knee* 8:247–248
  76. Schatzker J, Burgess RC, Glynn MK (1985) The management of nonunions following high tibial osteotomies. *Clin Orthop Relat Res Clin Orthop Relat Res* 193:230–233

77. Schenke M, Dickschas J, Simon · Michael, Strecker · Wolf (2018) Corrective osteotomies of the lower limb show a low intra- and perioperative complication rate—an analysis of 1003 patients. *Knee Surg Sport Traumatol Arthrosc* 26:1867–1872
78. Schubert MF, Sidhu R, Getgood AM, Sherman SL (2020) Failures of Realignment Osteotomy. *Oper Tech Sports Med* 28:150714
79. Schwarz N, Euler S, Schlittler M, Ulbing T, Wilhelm P, Fronhöfer G, Irnstorfer M (2013) Technical complications during removal of locking screws from locking compression plates: A prospective multicenter study. *Eur J Trauma Emerg Surg* 39:339–344
80. Seki K, Sakka A, Tokushige A, Imagama T, Mutou M, Taguchi T (2014) Treatment for *Staphylococcus aureus* infection following open wedge high tibial osteotomy using antibiotic-impregnated calcium phosphate cement. *Knee Surgery, Sport Traumatol Arthrosc* 22:2614–2617
81. Shenoy PM, Oh HK, Choi JY, Yoo SH, Han SB, Yoon JR, Koo JS, Nha KW (2009) Pseudoaneurysm of the popliteal artery complicating medial opening wedge high tibial osteotomy. *Orthopedics* 32:442
82. Shetty AA, Tindall AJ, Qureshi F, Divekar M, Fernando KWK (2003) The effect of knee flexion on the popliteal artery and its surgical significance. *J Bone Jt Surg - Ser B* 85:218–222
83. Shin YS, Sim HB, Yoon JR (2017) Tibial nerve neuropathy following medial opening-wedge high tibial osteotomy—case report of a rare technical complication. *Eur J Orthop Surg Traumatol* 27:563–567
84. Shiomi J, Takahashi T, Imazato S, Yamamoto H (2001) Flexion of the knee increases the distance between the popliteal artery and the proximal tibia - MRI measurements in 15 volunteers. *Acta Orthop Scand* 72:626–628
85. Siboni R, Beaufils P, Boisrenoult P, Steltzlen C, Pujol N (2018) Opening-wedge high tibial osteotomy without bone grafting in severe varus osteoarthritic knee. Rate and risk factors of non-union in 41 cases. *Orthop Traumatol Surg Res* 104:473–476
86. Sidhu R, Moatshe G, Firth A, Litchfield R, Getgood A (2021) Low rates of serious complications but high rates of hardware removal after high tibial osteotomy with Tomofix locking plate. *Knee Surgery, Sport Traumatol Arthrosc* 29:3361–3367
87. Smith PN, Gelinas J, Kennedy K, Thain L, Rorabeck CH, Bourne RB (1999) Popliteal vessels in knee surgery: A magnetic resonance imaging study. *Clin Orthop Relat Res*, pp 158–164
88. Song EK, Seon JK, Park SJ, Jeong MS (2010) The complications of high tibial osteotomy: Closing- versus opening-wedge methods. *J Bone Jt Surg - Ser B* 92:1245–1252
89. Spahn G, Kirschbaum S, Kahl E (2006) Factors that influence high tibial osteotomy results in patients with medial gonarthrosis: A score to predict the results. *Osteoarthr Cartil* 14:190–195
90. Staubli AE, De Simoni C, Babst R, Lobenhoffer P (2003) TomoFix: A new LCP-concept for open wedge osteotomy of the medial proximal tibia - Early results in 92 cases. *Injury* 34:55–62
91. Szyber Jr., Skóra, Rybak, Pupka (2011) Iatrogenic pseudoaneurysm of the popliteal artery following corrective tibial osteotomy. *Vasa* 40:414–417
92. Takebe K, Nakagawa A, Minami H, Kanazawa H, Hirohata K (1984) Role of the fibula in weight-bearing. *Clin Orthop Relat Res* 184:289–292
93. Takeuchi R, Ishikawa H, Kumagai K, Yamaguchi Y, Chiba N, Akamatsu Y, Saito T (2012) Fractures around the lateral cortical hinge after a medial opening-wedge high tibial osteotomy: A new classification of lateral hinge fracture. *Arthrosc - J Arthrosc Relat Surg* 28:85–94
94. Tandon SC, Kharbanda Y, Fraser AM (1996) Aneurysm complicating high tibial osteotomy: A case report. *Acta Orthop Acta Orthop Scand* 67:73–74
95. Tjörnstrand B, Hagstedt B, Persson BM (1978) Results of surgical treatment for non-union after high tibial osteotomy in osteoarthritis of the knee. *J Bone Joint Surg Am* 60:973–977



96. Valkering KP, van den Bekerom MPJ, Kappelhoff FM, Albers GHR (2009) Complications after tomofix medial opening wedge high tibial osteotomy. *J Knee Surg* 22:218–225
97. W-Dahl A, Lidgren L, Sundberg M, Robertsson O (2015) Introducing prospective national registration of knee osteotomies. A report from the first year in Sweden. *Int Orthop* 39:1283–1288
98. W-Dahl A, Toksvig-Larsen S (2006) Infection prophylaxis: A prospective study in 106 patients operated on by tibial osteotomy using the hemicallotasis technique. *Arch Orthop Trauma Surg* 126:441–447
99. Warden SJ, Morris HG, Crossley KM, Brukner PD, Bennell KL (2005) Delayed- and non-union following opening wedge high tibial osteotomy: Surgeons' results from 182 completed cases. *Knee Surgery, Sport Traumatol Arthrosc* 13:34–37
100. Whelan DB, Bhandari M, Stephen D, Kreder H, McKee MD, Zdero R, Schemitsch EH (2010) Development of the Radiographic Union Score for Tibial Fractures for the Assessment of Tibial Fracture Healing After Intramedullary Fixation. *J Trauma Inj Infect Crit Care* 68:629–632
101. Willey M, Wolf BR, Kocaglu B, Amendola A (2010) Complications associated with realignment osteotomy of the knee performed simultaneously with additional reconstructive procedures. *Iowa Orthop J* 30:55–60
102. Williams BR, McCreary DL, Parikh HR, Albersheim MS, Cunningham BP (2020) Improvement in Functional Outcomes After Elective Symptomatic Orthopaedic Implant Removal. *JAAOS Glob Res Rev* 4:e20.00137
103. Wissel H, Nebelung W, Awiszus F (1998) Intra-operative monitoring of common peroneal nerve function during surgery on the knee joint. *Biomed Tech* 43:326–329
104. Wolff AM, Krackow KA (1990) The treatment of nonunion of proximal tibial osteotomy with internal fixation. *Clin Orthop Relat Res* 250:207–215
105. Wong MT, Bourget-Murray J, Johnston K, Desy NM (2020) Understanding the role of total knee arthroplasty for primary treatment of tibial plateau fracture: a systematic review of the literature. *J Orthop Traumatol* 21:7
106. Woodacre T, Ricketts M, Evans JT, Pavlou G, Schranz P, Hockings M, Toms A (2016) Complications associated with opening wedge high tibial osteotomy - A review of the literature and of 15 years of experience. *Knee* 23:276–282
107. Yabuuchi K, Kondo E, Onodera J, Onodera T, Yagi T, Iwasaki N, Yasuda K (2020) Clinical Outcomes and Complications During and After Medial Open-Wedge High Tibial Osteotomy Using a Locking Plate: A 3- to 7-Year Follow-up Study. *Orthop J Sport Med* 8
108. Yang JCS, Lobenhoffer P, Chang CM, Chen CF, Lin HC, Ma HH, Lee PY, Lee OKS (2020) A supplemental screw enhances the biomechanical stability in medial open-wedge high tibial osteotomy. *PLoS One* 15:e0244557
109. Yapici F, Aykut US, Coskun M, Arslan MC, Merder-Coskun D, Kocabiyik A, Ulu E, Bayhan AI, Kaygusuz MA (2020) Complications, additional surgery, and joint survival analysis after medial open-wedge high tibial osteotomy. *Orthopedics* 43:303–314
110. Yoo JH, Chang CB (2009) The location of the popliteal artery in extension and 90 degree knee flexion measured on MRI. *Knee* 16:143–148
111. Yoshino N, Takai S, Watanabe Y, Nakamura S, Kubo T (2004) Total knee arthroplasty with long stem for treatment of nonunion after high tibial osteotomy. *J Arthroplasty* 19:528–531
112. Zaidi SHA, Cobb AG, Bentley G (1995) Danger to the popliteal artery in high tibial osteotomy. *J Bone Jt Surg - Ser B* 77:384–386